A 37-year-old man comes to the emergency department due to blood-tinged vomiting and abdominal discomfort. Six months ago, he lost his job as an investment banker and began drinking large amounts of whiskey on a daily basis. He has since been hospitalized several times with alcohol intoxication. His temperature is 36.7 C (98 F), blood pressure is 110/70 mm Hg, pulse is 84/min, and respirations are 18/min. Physical examination shows a firm, enlarged liver. Peripheral blood smear results show neutrophils with 6-8 nuclear lobes. Which of the following is the most likely explanation for this latter finding?

A. Blood lipid abnormality
B. Chronic blood loss
C. Cobalamin deficiency
D. Folate deficiency
E. Hypothyroidism
F. Myelodysplasia

Submit

A 37-year-old man comes to the emergency department due to blood-tinged vomiting and abdominal discomfort. Six months ago, he lost his job as an investment banker and began drinking large amounts of whiskey on a daily basis. He has since been hospitalized several times with alcohol intoxication. His temperature is 36.7 C (98 F), blood pressure is 110/70 mm Hg, pulse is 84/min, and respirations are 18/min. Physical examination shows a firm, enlarged liver. Peripheral blood smear results show neutrophils with 6-8 nuclear lobes. Which of the following is the most likely explanation for this latter finding?

- A. Blood lipid abnormality (1%)
- B. Chronic blood loss (1%)
- C. Cobalamin deficiency (22%)
- ✓ D. Folate deficiency (71%)
- E. Hypothyroidism (0%)
- F. Myelodysplasia (2%)

Omitted
Correct answer
D

71%
Answered correctly

04 secs
Time Spent

05/29/2020
Last Updated

Explanation

Alcoholism is one of the most common causes of **folate deficiency** anemia due to poor dietary intake and impaired folate absorption, utilization, and enterohepatic recycling. A normal individual with a folate-deficient diet can maintain normal red blood cell (RBC) production for months due to folate recycling, whereas a patient who consumes large amounts of alcohol will experience anemia within a few **weeks**. A reduced form of folic

Alcoholism is one of the most common causes of **folate deficiency** anemia due to poor dietary intake and impaired folate absorption, utilization, and enterohepatic recycling. A normal individual with a folate-deficient diet can maintain normal red blood cell (RBC) production for months due to folate recycling, whereas a patient who consumes large amounts of alcohol will experience anemia within a few **weeks**. A reduced form of folic acid, tetrahydrofolic acid, is necessary for the synthesis of amino acids, thymidine, and purines. Impaired nucleotide synthesis leads to defective DNA production in blood cell precursors, resulting in abnormal cell division and **megaloblastic** hyperplasia of the bone marrow. The peripheral blood smear shows pancytopenia and hypersegmented neutrophils containing nuclei with >5 lobes. RBC abnormalities include ovalocytosis and **macrocytosis**, with a mean corpuscular volume (MCV) >100 μm^3.

(Choice A) Lipid abnormalities such as extreme hypertriglyceridemia can cause acute pancreatitis.

(Choice B) Chronic blood loss causes iron deficiency anemia, which is not characterized by hypersegmented neutrophils.

(Choice C) Vitamin B_{12} (cobalamin) deficiency is typically associated with pernicious anemia, gastrectomy, certain medications, and fish tapeworm infections. Chronic alcohol use can deplete vitamin B_{12} levels; however, given the body's large B_{12} stores, this depletion would take place over a period of many years not months. In addition, there is no mention in this patient of the neurologic symptoms that classically accompany B_{12} deficiency (eg, subacute combined degeneration with paresthesias, ataxia, and loss of proprioception).

(Choice E) Elevated MCV can be present in hypothyroidism, but hypersegmented neutrophils are classically not seen.

(Choice F) Myelodysplasia is a premalignant condition that manifests with pancytopenia, impaired blood cell differentiation, and clonal expansion of mutated hematopoietic cells in the bone marrow. Elevated MCV can be present, but hypersegmented neutrophils are not commonly seen.

Educational objective:
Folic acid deficiency anemia commonly occurs in alcoholism. It is a megaloblastic anemia that can develop within weeks. Peripheral blood smear shows macrocytosis, ovalocytosis, and neutrophils with hypersegmented nuclei.

References

- Disturbances of folic acid and homocysteine metabolism in alcohol abuse
- Red blood cell status in alcoholic and non-alcoholic liver disease

DNA production in blood cell precursors, resulting in abnormal cell division and **megaloblastic** hyperplasia of the bone marrow. The peripheral blood smear shows pancytopenia and hypersegmented neutrophils containing nuclei with >5 lobes. RBC abnormalities include ovalocytosis and **macrocytosis**, with a mean corpuscular volume (MCV) >100 μm^3.

(Choice A) Lipid abnormalities such as extreme hypertriglyceridemia can cause acute pancreatitis.

(Choice B) Chronic blood loss causes iron deficiency anemia, which is not characterized by hypersegmented neutrophils.

(Choice C) Vitamin B_{12} (cobalamin) deficiency is typically associated with pernicious anemia, gastrectomy, certain medications, and fish tapeworm infections. Chronic alcohol use can deplete vitamin B_{12} levels; however, given the body's large B_{12} stores, this depletion would take place over a period of many years not months. In addition, there is no mention in this patient of the neurologic symptoms that classically accompany B_{12} deficiency (eg, subacute combined degeneration with paresthesias, ataxia, and loss of proprioception).

(Choice E) Elevated MCV can be present in hypothyroidism, but hypersegmented neutrophils are classically not seen.

(Choice F) Myelodysplasia is a premalignant condition that manifests with pancytopenia, impaired blood cell differentiation, and clonal expansion of mutated hematopoietic cells in the bone marrow. Elevated MCV can be present, but hypersegmented neutrophils are not commonly seen.

Educational objective:
Folic acid deficiency anemia commonly occurs in alcoholism. It is a megaloblastic anemia that can develop within weeks. Peripheral blood smear shows macrocytosis, ovalocytosis, and neutrophils with hypersegmented nuclei.

References

- Disturbances of folic acid and homocysteine metabolism in alcohol abuse
- Red blood cell status in alcoholic and non-alcoholic liver disease

Pathology	Hematology & Oncology	Alcohol use disorder
Subject	System	Topic

Copyright © UWorld. All rights reserved.

Correct answer
D

Answered correctly
Time Spent
Last Updated

Exhibit Display

Hypersegmented neutrophils Hypersegmented neutrophils

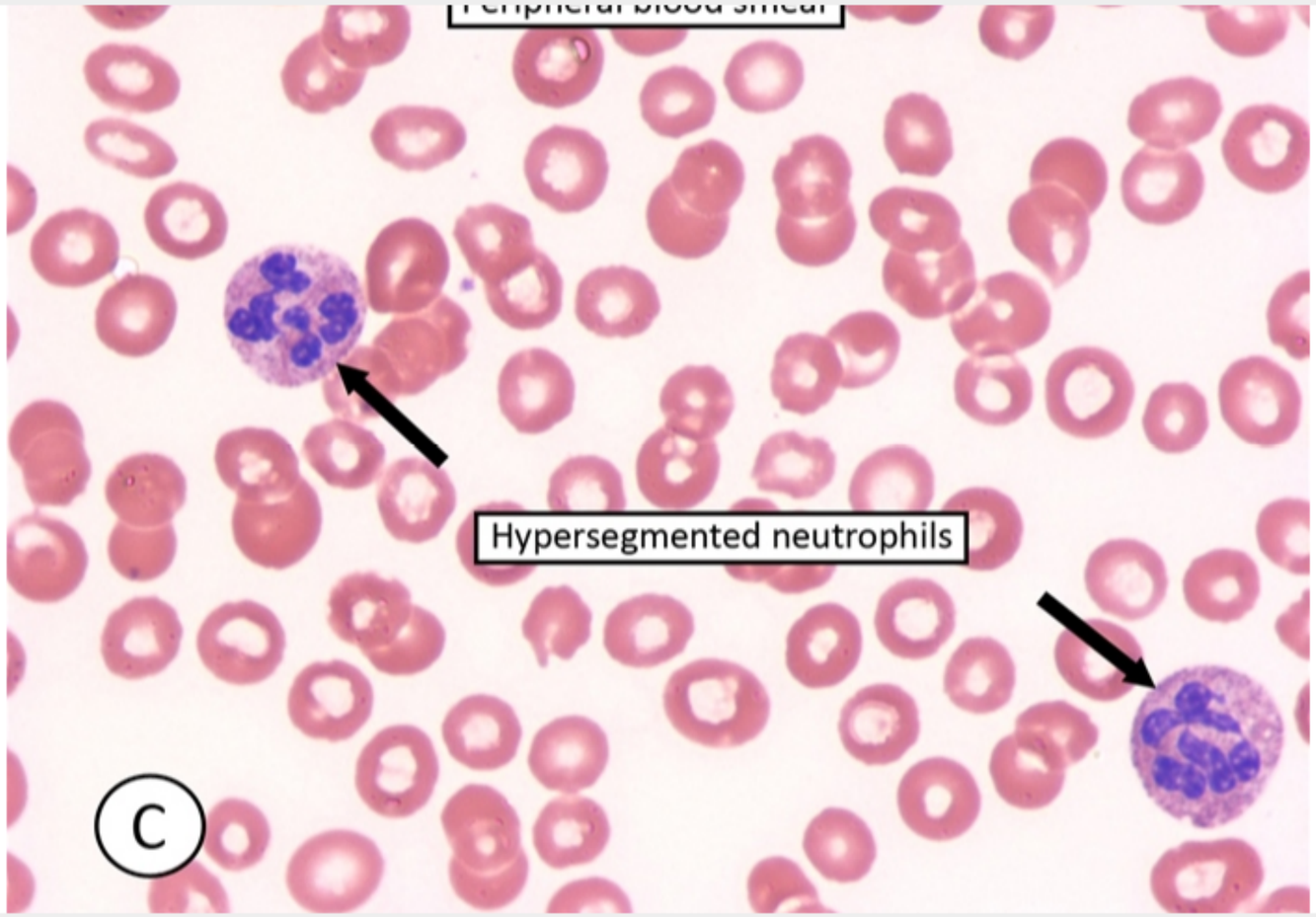

Zoom In Zoom Out Reset Add To New Card | Existing Card

1
2
3
4
5
6
7
8
9
10
11
12
13
14
15
16
17
18
19
20
21
22
23
24
25
26
27
28
29
30

Correct answer
D

Answered correctly

Time Spent

Last Updated

Exhibit Display

Hypersegmented neutrophils Hypersegmented neutrophils

Zoom In Zoom Out Reset Add To New Card | Existing Card

Correct answer
D

Answered correctly
Time Spent
Last Updated

Exhibit Display

Hypersegmented neutrophils Hypersegmented neutrophils

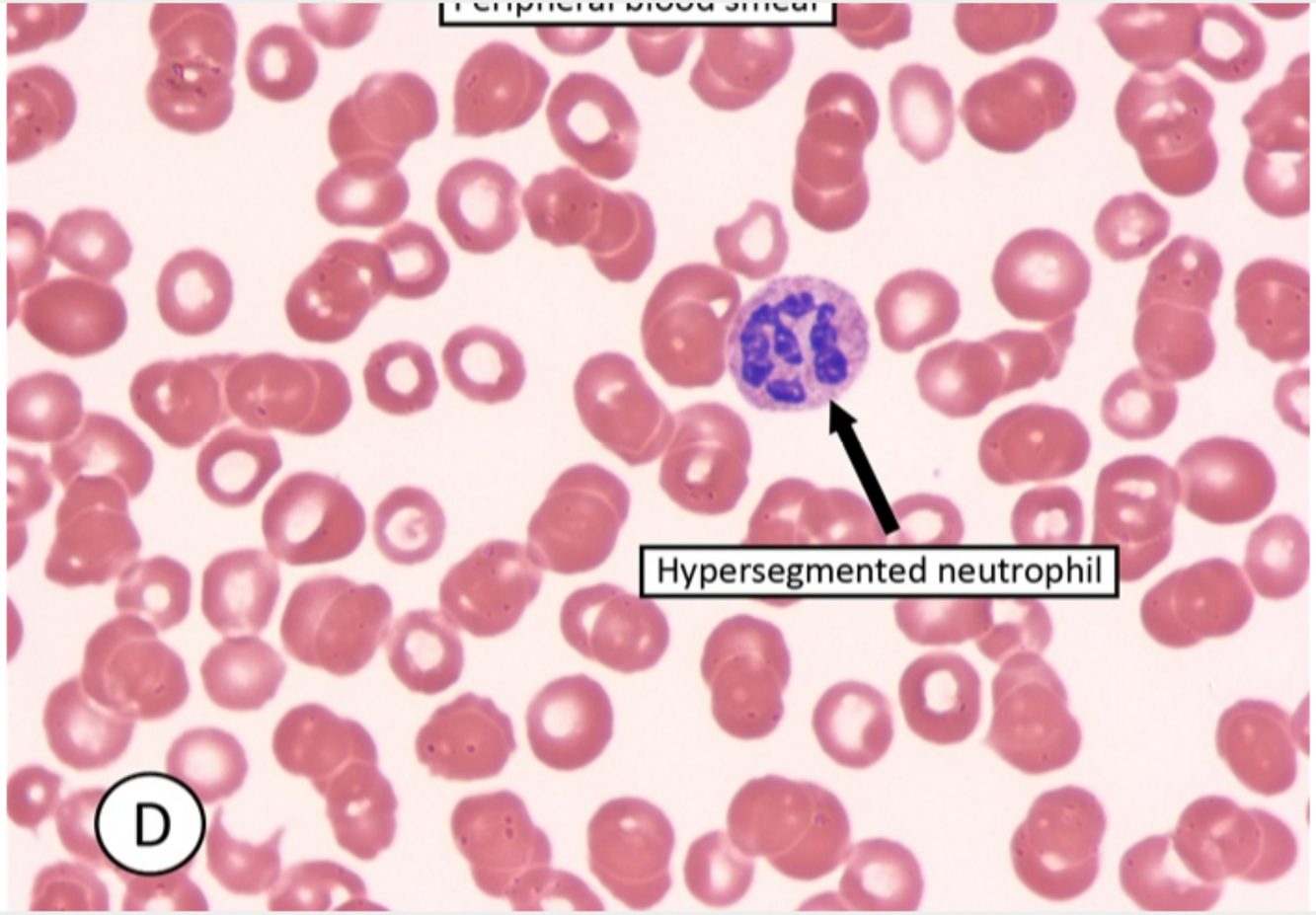

Zoom In Zoom Out Reset Add To New Card | Existing Card

A 32-year-old African American male is diagnosed with acute prostatitis. He has no significant past medical history. He begins treatment with trimethoprim-sulfamethoxazole, but subsequently develops dark urine and anemia with a high reticulocyte count. Which of the following is the best explanation for the observed findings?

A. Antibody-mediated erythrocyte destruction

B. Hereditary erythrocyte membrane defect

C. Hereditary erythrocyte enzyme deficiency

D. Hemoglobin structure abnormality

E. Microangiopathic hemolytic anemia

Submit

A 32-year-old African American male is diagnosed with acute prostatitis. He has no significant past medical history. He begins treatment with trimethoprim-sulfamethoxazole, but subsequently develops dark urine and anemia with a high reticulocyte count. Which of the following is the best explanation for the observed findings?

- A. Antibody-mediated erythrocyte destruction (7%)
- B. Hereditary erythrocyte membrane defect (3%)
- ✓ C. Hereditary erythrocyte enzyme deficiency (77%)
- D. Hemoglobin structure abnormality (4%)
- E. Microangiopathic hemolytic anemia (6%)

Omitted
Correct answer
C

77%
Answered correctly

03 secs
Time Spent

02/03/2020
Last Updated

Explanation

This patient is demonstrating signs of hemolysis induced by trimethoprim-sulfamethoxazole (Bactrim, TMP/SMX). This scenario is not an uncommon way for glucose-6-phosphate dehydrogenase (G6PD) deficiency to present. G6PD deficiency is an X-linked disorder that affects mostly males, and is more common in patients of African, Asian and Mediterranean descent. G6PD is an enzyme of the pentose phosphate pathway that in erythrocytes is essential for maintaining adequate concentrations of NADPH. Insufficient NADPH results in an inability to maintain glutathione in the reduced state. This increases the vulnerability of erythrocytes to oxidative stress and manifests with hemolysis induced by infection, drugs (e.g. bactrim, dapsone, antimalarials, nitrofurantoin), or other oxidants (e.g. fava beans).

This patient is demonstrating signs of hemolysis induced by trimethoprim-sulfamethoxazole (Bactrim, TMP/SMX). This scenario is not an uncommon way for glucose-6-phosphate dehydrogenase (G6PD) deficiency to present. G6PD deficiency is an X-linked disorder that affects mostly males, and is more common in patients of African, Asian and Mediterranean descent. G6PD is an enzyme of the pentose phosphate pathway that in erythrocytes is essential for maintaining adequate concentrations of NADPH. Insufficient NADPH results in an inability to maintain glutathione in the reduced state. This increases the vulnerability of erythrocytes to oxidative stress and manifests with hemolysis induced by infection, drugs (e.g. bactrim, dapsone, antimalarials, nitrofurantoin), or other oxidants (e.g. fava beans).

Hemolytic episodes manifest with symptoms of anemia such as malaise and pallor, indirect bilirubinemia (jaundice), hemoglobinemia and hemoglobinuria (dark-red urine). The level of serum haptoglobin decreases and a reticulocytosis develops to compensate for the increased destruction of RBCs. Patients are generally asymptomatic between episodes.

(Choice A) Autoimmune hemolytic anemias result from extrinsic antibody-mediated hemolysis and are associated with a positive Coombs test. These anemias often accompany SLE and other autoimmune diseases, Hodgkin and non-Hodgkin lymphomas, *Mycoplasma* infections (cold agglutinins), and infectious mononucleosis.

(Choice B) Hereditary spherocytosis is an autosomal dominant defect in RBC structural proteins (spectrin, ankyrin, or protein 4.1) characterized by increased erythrocyte osmotic fragility and MCHC (mean corpuscular hemoglobin concentration) increased above 36 g/dL.

(Choice D) Abnormalities of hemoglobin structure include hemoglobin S (sickle cell disease), C, and E disorders, as well as others. Heterozygotes usually show minimal to no clinical signs, while homozygotes present with hemolytic anemia in addition to other disease-specific complications.

(Choice E) Microangiopathic hemolytic anemia (MAHA) occurs when there is destruction of RBCs within small vessels due to widespread thrombosis. MAHA is associated with disseminated intravascular coagulation (DIC), thrombotic thrombocytopenic purpura (TTP) and hemolytic-uremic syndrome (HUS).

Educational Objective:
Glucose-6-phosphate dehydrogenase deficiency is an X-linked disorder of the hexose monophosphate (pentose phosphate) pathway. In affected individuals, the amount of NADPH produced in RBCs is low, which impairs glutathione-mediated inactivation of free radicals. Hemolytic episodes are induced by infections, medications, and other oxidants.

This patient is demonstrating signs of hemolysis induced by trimethoprim-sulfamethoxazole (Bactrim, TMP/SMX). This scenario is not an uncommon way for glucose-6-phosphate dehydrogenase (G6PD) deficiency to present. G6PD deficiency is an X-linked disorder that affects mostly males, and is more common in patients of African, Asian and Mediterranean descent. G6PD is an enzyme of the pentose phosphate pathway that in erythrocytes is essential for maintaining adequate concentrations of NADPH. Insufficient NADPH results in an inability to maintain glutathione in the reduced state. This increases the vulnerability of erythrocytes to oxidative stress and manifests with hemolysis induced by infection, drugs (e.g. bactrim, dapsone, antimalarials, nitrofurantoin), or other oxidants (e.g. fava beans).

Hemolytic episodes manifest with symptoms of anemia such as malaise and pallor, indirect bilirubinemia (jaundice), hemoglobinemia and hemoglobinuria (dark-red urine). The level of serum haptoglobin decreases and a reticulocytosis develops to compensate for the increased destruction of RBCs. Patients are generally asymptomatic between episodes.

(Choice A) Autoimmune hemolytic anemias result from extrinsic antibody-mediated hemolysis and are associated with a positive Coombs test. These anemias often accompany SLE and other autoimmune diseases, Hodgkin and non-Hodgkin lymphomas, *Mycoplasma* infections (cold agglutinins), and infectious mononucleosis.

(Choice B) Hereditary spherocytosis is an autosomal dominant defect in RBC structural proteins (spectrin, ankyrin, or protein 4.1) characterized by increased erythrocyte osmotic fragility and MCHC (mean corpuscular hemoglobin concentration) increased above 36 g/dL.

(Choice D) Abnormalities of hemoglobin structure include hemoglobin S (sickle cell disease), C, and E disorders, as well as others. Heterozygotes usually show minimal to no clinical signs, while homozygotes present with hemolytic anemia in addition to other disease-specific complications.

(Choice E) Microangiopathic hemolytic anemia (MAHA) occurs when there is destruction of RBCs within small vessels due to widespread thrombosis. MAHA is associated with disseminated intravascular coagulation (DIC), thrombotic thrombocytopenic purpura (TTP) and hemolytic-uremic syndrome (HUS).

Educational Objective:
Glucose-6-phosphate dehydrogenase deficiency is an X-linked disorder of the hexose monophosphate (pentose phosphate) pathway. In affected individuals, the amount of NADPH produced in RBCs is low, which impairs glutathione-mediated inactivation of free radicals. Hemolytic episodes are induced by infections, medications, and other oxidants.

1
2
3
4
5
6
7
8
9
10
11
12
13
14
15
16
17
18
19
20
21
22
23
24
25
26
27
28
29
30

A 12-year-old girl is brought to the emergency department due to several days of worsening exertional dyspnea and lethargy. The patient has a history of sickle cell disease and takes hydroxyurea. Physical examination shows mucosal pallor and an ejection systolic murmur. Laboratory studies reveal a hemoglobin level of 5.6 gm/dL. Bone marrow biopsy is performed and demonstrates decreased erythroid precursors and giant pronormoblasts containing inclusions, as shown below.

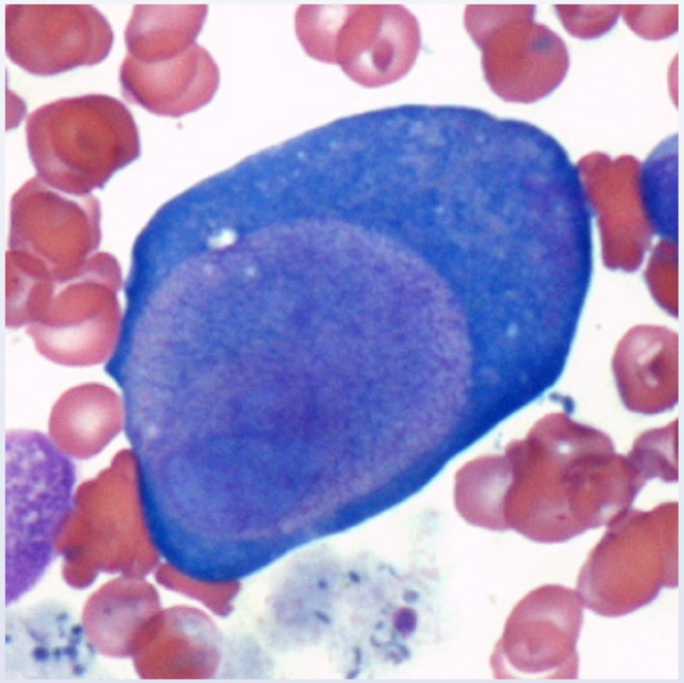

Which of the following is the most likely cause of this patient's current condition?

A. Acute viral infection

B. Dietary folate deficiency

C. Medication adverse effect

1
2
3
4
5
6
7
8
9
10
11
12
13
14
15
16
17
18
19
20
21
22
23
24
25
26
27
28
29
30

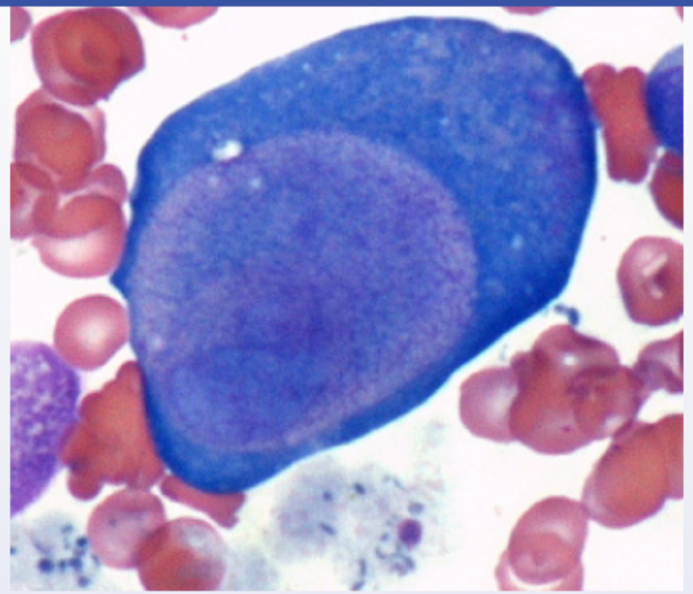

Which of the following is the most likely cause of this patient's current condition?

- A. Acute viral infection
- B. Dietary folate deficiency
- C. Medication adverse effect
- D. Secondary iron overload
- E. Toxic chemical exposure

Submit

1
2
3
4
5
6
7
8
9
10
11
12
13
14
15
16
17
18
19
20
21
22
23
24
25
26
27
28
29
30

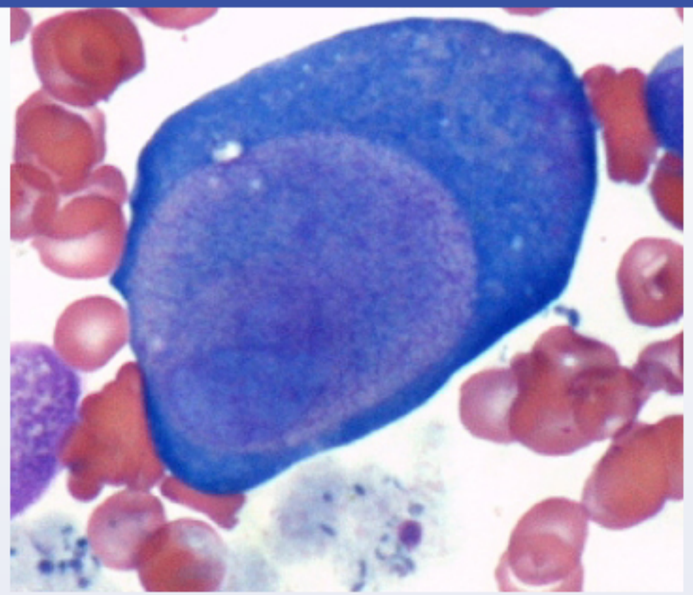

Which of the following is the most likely cause of this patient's current condition?

- ✓ A. Acute viral infection (56%)
- B. Dietary folate deficiency (9%)
- C. Medication adverse effect (27%)
- D. Secondary iron overload (3%)
- E. Toxic chemical exposure (2%)

Omitted
Correct answer

56%
Answered correctly

05 secs
Time Spent

02/16/2020
Last Updated

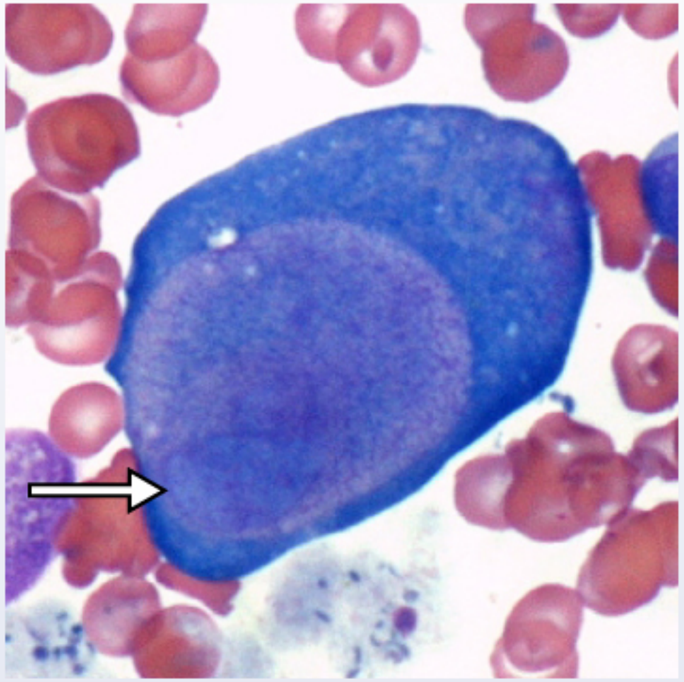

This patient's symptomatic anemia (lethargy, exertional dyspnea, mucosal pallor, ejection murmur) and bone marrow biopsy evidence of ineffective erythropoiesis (reduced erythrocyte precursors) raise suspicion for **transient aplastic crisis** due to acute **parvovirus B19 infection**.

Parvovirus is a small, nonenveloped, DNA virus transmitted via the respiratory route that primarily attacks erythroid progenitor cells due to tropism for an erythrocyte cell surface receptor (P blood group antigen). Infection of erythroid progenitor cells **prevents red blood cell maturation**, leading to formation of abnormal **giant pronormoblasts** (several times larger than surrounding red blood cells) with glassy, intranuclear viral inclusions. The drop in red cell production often leads to a transient (1-2 week) drop in hematocrit. Although many patients are asymptomatic, individuals with underlying hemoglobin disorders (eg, **sickle cell anemia**) sometimes develop **symptomatic anemia**.

(Choice B) Folate deficiency can be seen in patients with sickle disease because of increased erythropoiesis (in response to chronic anemia). However, folate deficiency is characterized by macrocytic anemia and hypersegmented neutrophils; giant pronormoblasts with inclusions would not be seen.

This patient's symptomatic anemia (lethargy, exertional dyspnea, mucosal pallor, ejection murmur) and bone marrow biopsy evidence of ineffective erythropoiesis (reduced erythrocyte precursors) raise suspicion for **transient aplastic crisis** due to acute **parvovirus B19 infection**.

Parvovirus is a small, nonenveloped, DNA virus transmitted via the respiratory route that primarily attacks erythroid progenitor cells due to tropism for an erythrocyte cell surface receptor (P blood group antigen). Infection of erythroid progenitor cells **prevents red blood cell maturation**, leading to formation of abnormal **giant pronormoblasts** (several times larger than surrounding red blood cells) with glassy, intranuclear viral inclusions. The drop in red cell production often leads to a transient (1-2 week) drop in hematocrit. Although many patients are asymptomatic, individuals with underlying hemoglobin disorders (eg, **sickle cell anemia**) sometimes develop **symptomatic anemia**.

(Choice B) Folate deficiency can be seen in patients with sickle disease because of increased erythropoiesis (in response to chronic anemia). However, folate deficiency is characterized by macrocytic anemia and hypersegmented neutrophils; giant pronormoblasts with inclusions would not be seen.

(Choice C) Hydroxyurea can sometimes interfere with normal erythropoiesis and result in macrocytic anemia. However, it is not associated with giant pronormoblasts with intranuclear inclusions.

(Choice D) Patients with sickle cell disease who require repeated blood transfusion can sometimes develop secondary iron overload. Bone marrow biopsy would show increased iron stores.

(Choice E) Exposure to toxic chemicals (eg, industrial solvents/chemicals, insecticides) can lead to aplastic anemia. However, bone marrow biopsy would show hypocellular marrow with a decrease in all cell types; the remaining hematopoietic cells would be morphologically normal.

Educational objective:
Parvovirus B19 infection can cause transient aplastic crisis, particularly in those with underlying hemoglobin disorders such as sickle cell anemia. Patients develop symptomatic anemia (eg, exertional dyspnea, fatigue, low hematocrit) due to inhibition of erythropoiesis by the virus. Bone marrow examination will show giant pronormoblasts with glassy, intranuclear viral inclusions.

Pathology	Hematology & Oncology	Sickle cell
Subject	System	Topic

1
2
3
4
5
6
7
8
9
10
11
12
13
14
15
16
17
18
19
20
21
22
23
24
25
26
27
28
29
30

Exhibit Display

Hemochromatosis

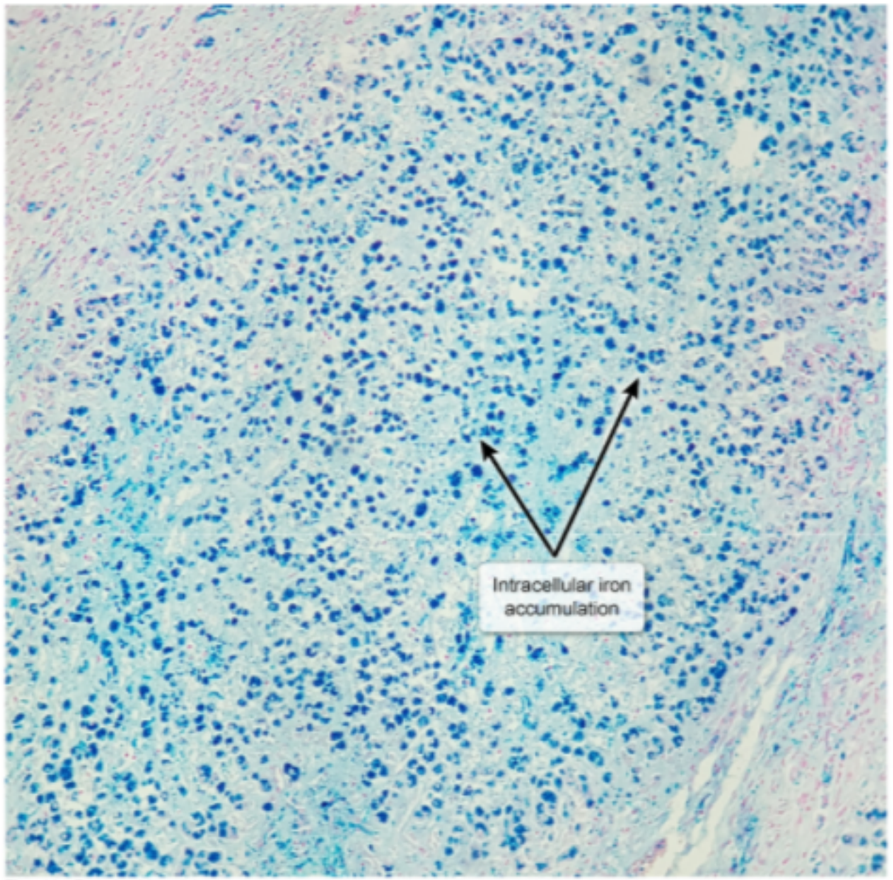

Thyroid – Prussian blue stain

©UWorld

Zoom In | Zoom Out | Reset | Add To New Card | Existing Card

A 61-year-old man comes to the office due to 4 months of easy fatigability, anorexia, and a 4.5-kg (10-lb) unintentional weight loss. His stool occult blood testing is positive, and laboratory studies show microcytic hypochromic anemia. Colonoscopy reveals a 6-cm (2.4-in) mass in the descending colon. Biopsy samples obtained during the procedure are consistent with adenocarcinoma. A subsequent CT scan of the abdomen shows multiple metastatic liver lesions. Therapy with monoclonal antibodies that bind to epidermal growth factor receptors on the malignant cells is considered. An activating mutation in which of the following will most likely make this therapy ineffective?

A. Adenomatous polyposis coli protein

B. KRAS protein

C. p53 protein

D. Platelet-derived growth factor

E. Vascular endothelial growth factor

Submit

A 61-year-old man comes to the office due to 4 months of easy fatigability, anorexia, and a 4.5-kg (10-lb) unintentional weight loss. His stool occult blood testing is positive, and laboratory studies show microcytic hypochromic anemia. Colonoscopy reveals a 6-cm (2.4-in) mass in the descending colon. Biopsy samples obtained during the procedure are consistent with adenocarcinoma. A subsequent CT scan of the abdomen shows multiple metastatic liver lesions. Therapy with monoclonal antibodies that bind to epidermal growth factor receptors on the malignant cells is considered. An activating mutation in which of the following will most likely make this therapy ineffective?

- A. Adenomatous polyposis coli protein (6%)
- ✓ B. KRAS protein (56%)
- C. p53 protein (11%)
- D. Platelet-derived growth factor (7%)
- E. Vascular endothelial growth factor (17%)

Omitted
Correct answer
B

56%
Answered correctly

02 secs
Time Spent

03/02/2020
Last Updated

Explanation

KRAS mutation causing anti-EGFR resistance

EGFR inhibitor

1
2
3
4
5
6
7
8
9
10
11
12
13
14
15
16
17
18
19
20
21
22
23
24
25
26
27
28
29
30

KRAS mutation causing anti-EGFR resistance

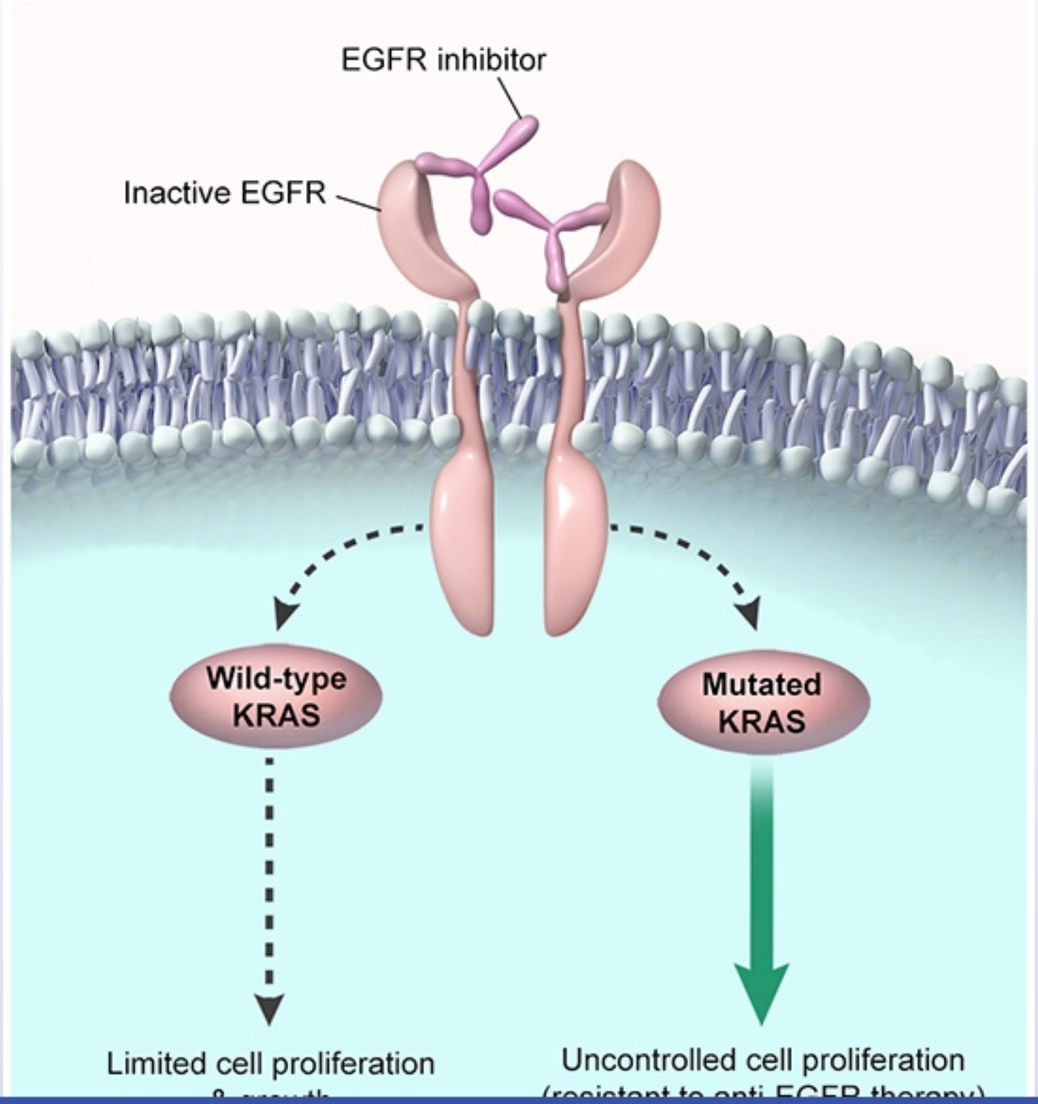

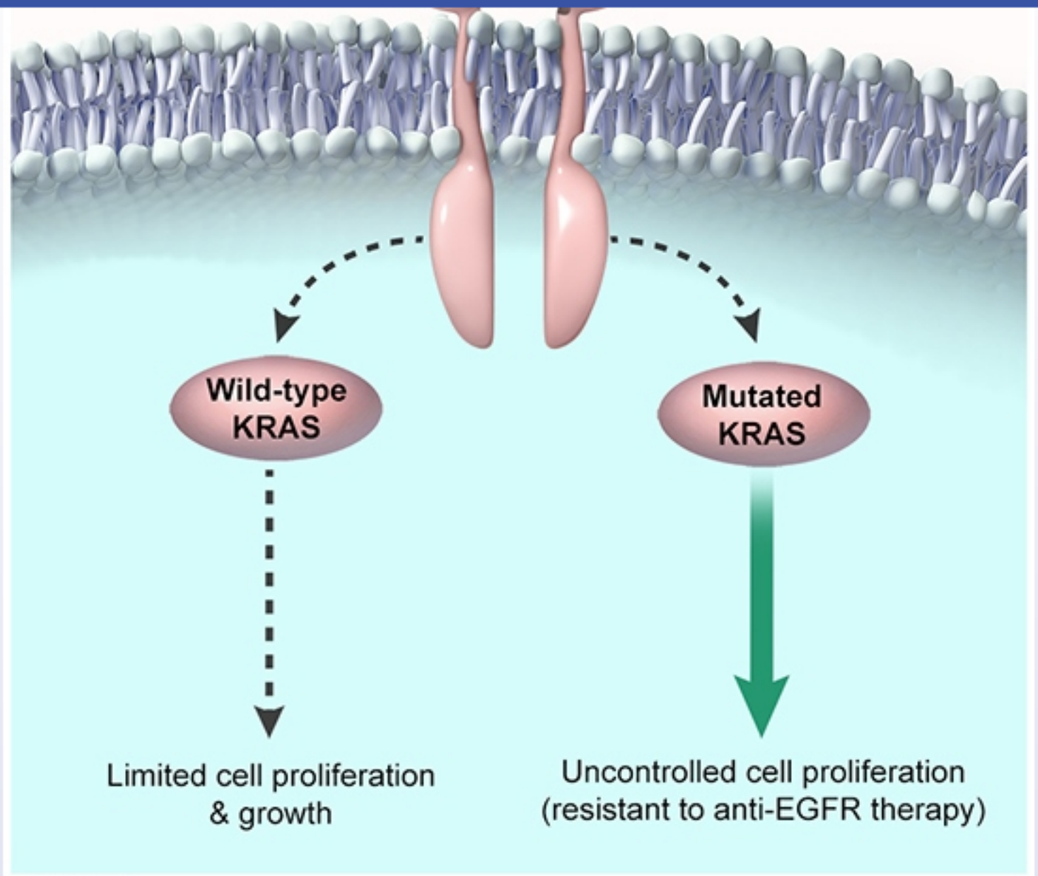

©UWorld

Epidermal growth factor receptor (EGFR) is stimulated in a paracrine or autocrine fashion by its ligands, leading to the **downstream activation of KRAS**, a membrane-bound GTP-binding protein that **stimulates cellular growth** and proliferation. Many cancers (eg, colorectal, pancreas) leverage this system to drive unchecked cellular growth by overexpressing EGFR and its ligands or by developing constitutive activating mutations in the *KRAS* proto-oncogene.

The EGFR signaling system can be targeted for cancer treatment through the use of **monoclonal antibodies** (eg, cetuximab, panitumumab) that **block EGFR**, leading to reduced KRAS stimulation and **decreased cellular growth**. However, this treatment is only effective for tumors with wild

Epidermal growth factor receptor (EGFR) is stimulated in a paracrine or autocrine fashion by its ligands, leading to the **downstream activation of KRAS**, a membrane-bound GTP-binding protein that **stimulates cellular growth** and proliferation. Many cancers (eg, colorectal, pancreas) leverage this system to drive unchecked cellular growth by overexpressing EGFR and its ligands or by developing constitutive activating mutations in the *KRAS* proto-oncogene.

The EGFR signaling system can be targeted for cancer treatment through the use of **monoclonal antibodies** (eg, cetuximab, panitumumab) that **block EGFR**, leading to reduced KRAS stimulation and **decreased cellular growth**. However, this treatment is only effective for tumors with wild-type (normal) KRAS. Tumors with ***KRAS*-activating mutations** are **resistant** to anti-EGFR agents as they have a constitutive activation of a downstream signal that is independent of EGFR stimulation or blockade. Prior to the use of anti-EGFR agents, genetic testing of tumor tissue is performed to see if KRAS is wild-type (eligible for treatment) or mutated (noneligible).

(Choice A) Adenomatous polyposis coli is a tumor suppressor protein that helps degrade beta-catenin, preventing uncontrolled cell growth. Inherited inactivating gene mutations are responsible for familial adenomatous polyposis.

(Choice C) p53 is a tumor suppressor protein involved in DNA repair, apoptosis, and cell cycle control; mutations or deletions are present in a large percentage of human tumors.

(Choice D) Platelet-derived growth factor stimulates formation of new blood vessels and proliferation of fibroblasts and smooth muscle cells by binding to a receptor tyrosine kinase; mutations resulting in overexpression encourage tumor growth by promoting uncontrolled angiogenesis.

(Choice E) Vascular endothelial growth factor (VEGF) is the dominant growth factor involved in angiogenesis and lymph vessel development. Overexpression of VEGF promotes tumor vascularization, facilitating the growth and metastasis of cancers.

Educational objective:
Activating mutations of the *KRAS* gene lead to constitutive activation of the epidermal growth factor receptor (EGFR) pathway, promoting increased cell proliferation and growth. Tumors harboring these mutations are resistant to treatment with anti-EGFR drugs (eg, cetuximab, panitumumab).

References

- KRAS mutation testing in metastatic colorectal cancer.

block EGFR, leading to reduced KRAS stimulation and **decreased cellular growth**. However, this treatment is only effective for tumors with wild-type (normal) KRAS. Tumors with ***KRAS*-activating mutations** are **resistant** to anti-EGFR agents as they have a constitutive activation of a downstream signal that is independent of EGFR stimulation or blockade. Prior to the use of anti-EGFR agents, genetic testing of tumor tissue is performed to see if KRAS is wild-type (eligible for treatment) or mutated (noneligible).

(Choice A) Adenomatous polyposis coli is a tumor suppressor protein that helps degrade beta-catenin, preventing uncontrolled cell growth. Inherited inactivating gene mutations are responsible for familial adenomatous polyposis.

(Choice C) p53 is a tumor suppressor protein involved in DNA repair, apoptosis, and cell cycle control; mutations or deletions are present in a large percentage of human tumors.

(Choice D) Platelet-derived growth factor stimulates formation of new blood vessels and proliferation of fibroblasts and smooth muscle cells by binding to a receptor tyrosine kinase; mutations resulting in overexpression encourage tumor growth by promoting uncontrolled angiogenesis.

(Choice E) Vascular endothelial growth factor (VEGF) is the dominant growth factor involved in angiogenesis and lymph vessel development. Overexpression of VEGF promotes tumor vascularization, facilitating the growth and metastasis of cancers.

Educational objective:
Activating mutations of the *KRAS* gene lead to constitutive activation of the epidermal growth factor receptor (EGFR) pathway, promoting increased cell proliferation and growth. Tumors harboring these mutations are resistant to treatment with anti-EGFR drugs (eg, cetuximab, panitumumab).

References

- KRAS mutation testing in metastatic colorectal cancer.
- Clinical relevance of KRAS in human cancers.

Pathology	Hematology & Oncology	Colorectal cancer
Subject	System	Topic

Copyright © UWorld. All rights reserved.

1
2
3
4
5
6
7
8
9
10
11
12
13
14
15
16
17
18
19
20
21
22
23
24
25
26
27
28
29
30

A 15-year-old boy is brought to the emergency department due to hemoptysis. He has a history of amputation of the right lower extremity for "bone cancer" in Mexico. Chest imaging reveals a lung mass. Excisional biopsy of the mass shows sheets of uniform, small (slightly larger than lymphocytes), round cells with scant, clear cytoplasm. The cellular deposits are interrupted by vascular fibrous septae, with areas of hemorrhage and an abrupt transition from viable to necrotic cells. A representative sample is shown in the image.

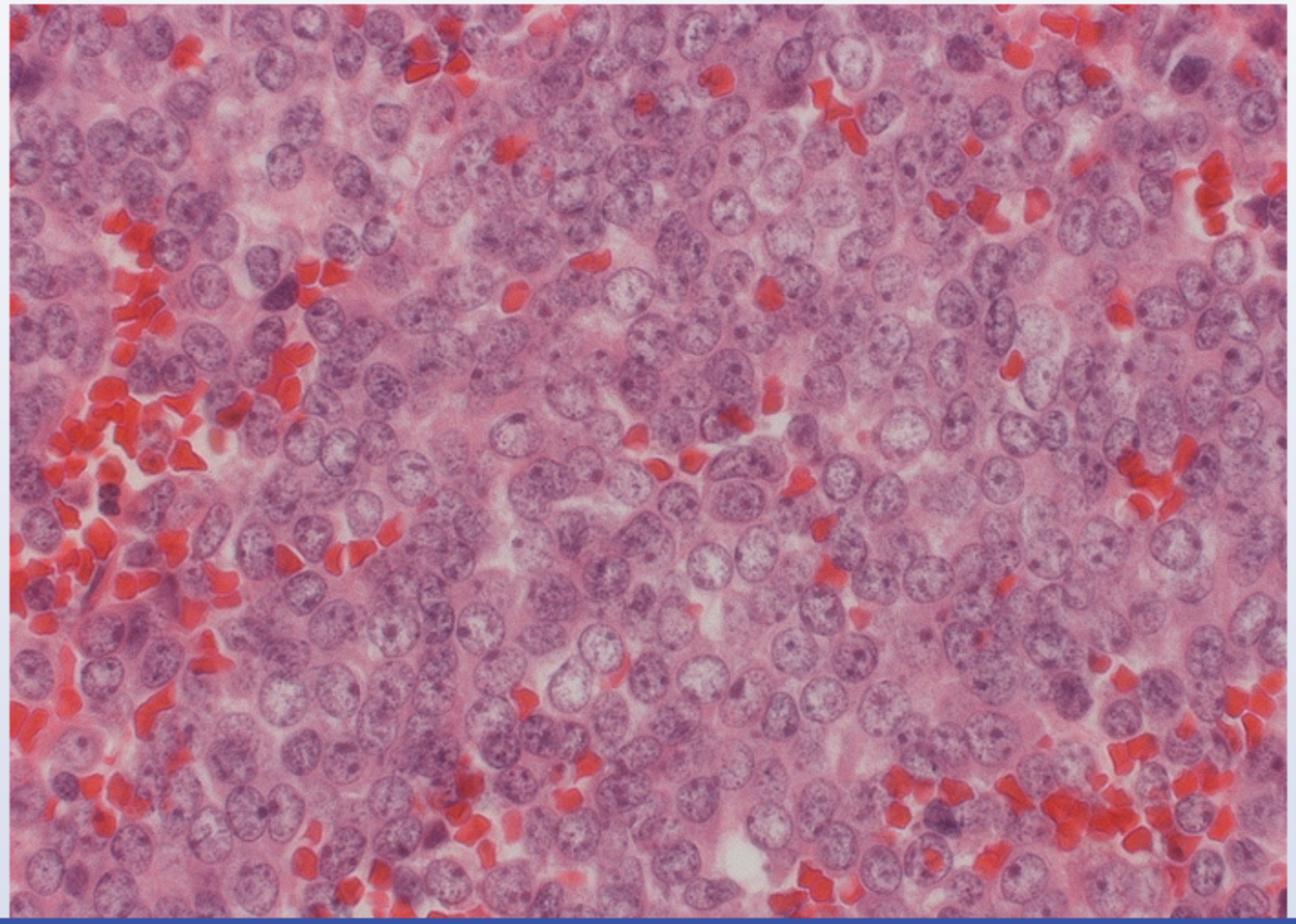

1
2
3
4
5
6
7
8
9
10
11
12
13
14
15
16
17
18
19
20
21
22
23
24
25
26
27
28
29
30

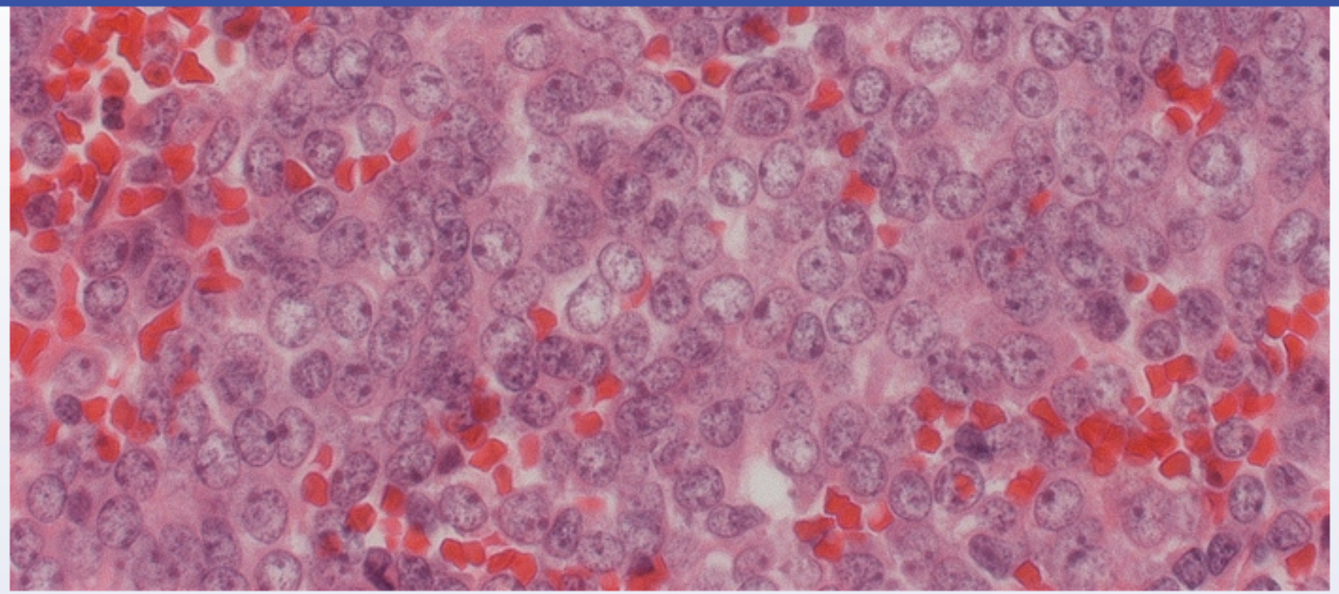

Which of the following is the most likely diagnosis?

A. Adenocarcinoma

B. Chondrosarcoma

C. Ewing sarcoma

D. Multiple myeloma

E. Osteosarcoma

Submit

1
2
3
4
5
6
7
8
9
10
11
12
13
14
15
16
17
18
19
20
21
22
23
24
25
26
27
28
29
30

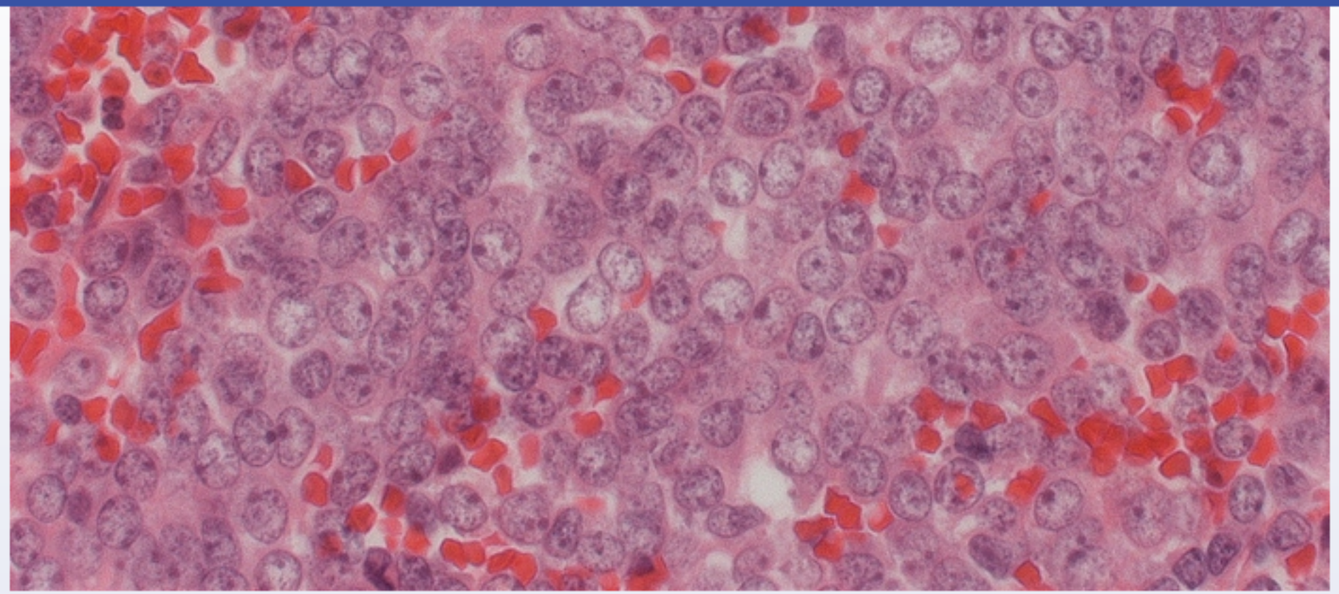

Which of the following is the most likely diagnosis?

A. Adenocarcinoma (5%)

B. Chondrosarcoma (7%)

✓ C. Ewing sarcoma (61%)

D. Multiple myeloma (4%)

E. Osteosarcoma (20%)

Omitted
Correct answer

61%
Answered correctly

05 secs
Time Spent

02/01/2020
Last Updated

Ewing sarcoma	
Epidemiology	• Mesenchymal stem cell neoplasm* • Primarily seen in children/young adults • Site of origin: long bones, axial skeleton, or pelvis
Manifestations	• Localized pain & swelling • Early metastases to lungs & other bones (may be subclinical)
Histopathology	• Sheets of uniform, small, round cells separated by fibrous septae • Scant, clear cytoplasm (heavy glycogen content) • Areas of hemorrhage & necrosis • Rare mitotic figures

*Ewing sarcoma was previously thought to be neuroectodermal in origin.

This boy with a history of bone cancer has a lung tumor with sheets of uniform, small, round cells, raising strong suspicion for metastatic **Ewing sarcoma** (ES). ES is the second most common childhood bone malignancy (after osteosarcoma) and typically presents with pain and swelling at the bone tumor site. Spread to the lungs or other tissue can occur in those who don't undergo both resection and chemotherapy.

ES is a primitive, undifferentiated tumor that was originally thought to be neuroectodermal in origin but is now believed to arise from a **mesenchymal stem cell**. Tumor histology typically reveals sheets of **uniform, small, round, cells** with clear, scant cytoplasm separated by **fibrous septae** and patches of necrosis/hemorrhage. This appearance resembles neuroendocrine tumors such as carcinoid and small cell lung cancer. Most cases of ES involve **translocations** of *EWSR1* and *FLI1*.

(Choice A) Adenocarcinoma, the most common primary lung malignancy, often metastasizes to bone. However, histopathology would show neoplastic glands lined by mucin-producing cells.

(Choice B) Chondrosarcoma is an uncommon tumor and typically occurs in the 5th or 6th decade of life. Histology shows neoplastic chondrocytes in a hyaline cartilage matrix, usually with small calcifications.

This boy with a history of bone cancer has a lung tumor with sheets of uniform, small, round cells, raising strong suspicion for metastatic **Ewing sarcoma** (ES). ES is the second most common childhood bone malignancy (after osteosarcoma) and typically presents with pain and swelling at the bone tumor site. Spread to the lungs or other tissue can occur in those who don't undergo both resection and chemotherapy.

ES is a primitive, undifferentiated tumor that was originally thought to be neuroectodermal in origin but is now believed to arise from a **mesenchymal stem cell**. Tumor histology typically reveals sheets of **uniform, small, round, cells** with clear, scant cytoplasm separated by **fibrous septae** and patches of necrosis/hemorrhage. This appearance resembles neuroendocrine tumors such as carcinoid and small cell lung cancer. Most cases of ES involve **translocations** of *EWSR1* and *FLI1*.

(Choice A) Adenocarcinoma, the most common primary lung malignancy, often metastasizes to bone. However, histopathology would show neoplastic glands lined by mucin-producing cells.

(Choice B) Chondrosarcoma is an uncommon tumor and typically occurs in the 5th or 6th decade of life. Histology shows neoplastic chondrocytes in a hyaline cartilage matrix, usually with small calcifications.

(Choice D) Multiple myeloma is a plasma cell malignancy that is extremely rare in patients age <40. X-ray often shows multiple lytic lesions, osteopenia, and pathologic fractures. The malignant cells have eccentric nuclei with "clock-face" chromatin, perinuclear clearing, and abundant basophilic cytoplasm.

(Choice E) Osteosarcoma is the most common primary bone malignancy. Histology shows pleomorphic, spindle-shaped cells that produce new osteoid and bone.

Educational objective:
Ewing sarcoma is the second most common malignant bone tumor of childhood (after osteosarcoma). It most commonly involves the lower extremity and pelvis and often metastasizes to the lungs. Histopathology is characterized by uniform, small, round, cells; fibrous septae; and patches of necrosis and hemorrhage.

References

- Pediatric malignant bone tumors: a review and update on current challenges, and emerging drug targets.

1
2
3
4
5
6
7
8
9
10
11
12
13
14
15
16
17
18
19
20
21
22
23
24
25
26
27
28
29
30

Exhibit Display

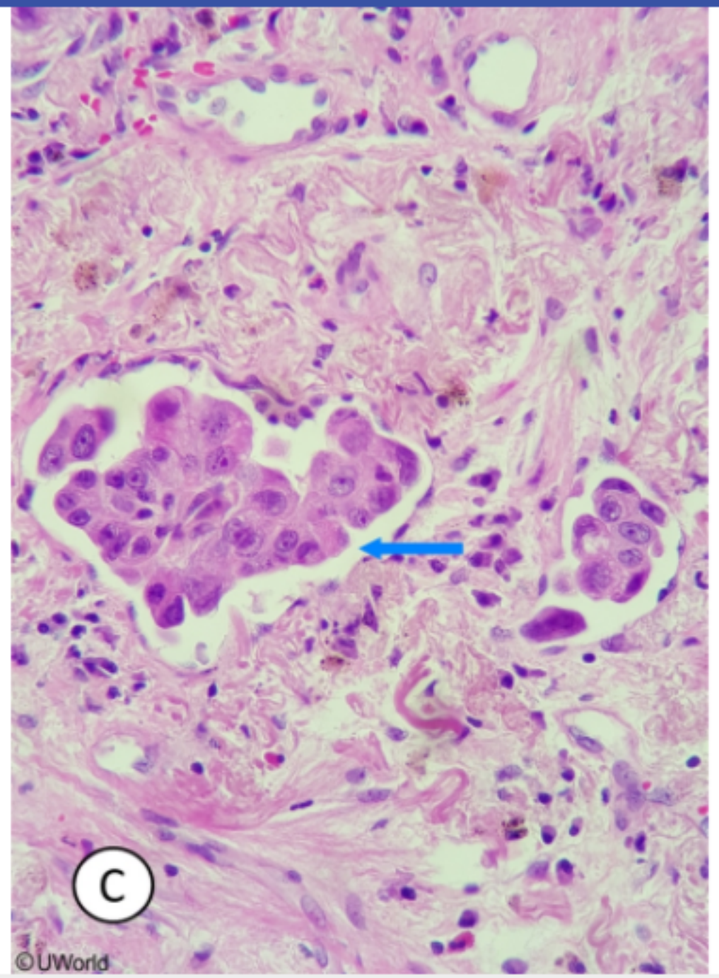

Zoom In | Zoom Out | Reset | Add To New Card | Existing Card

Exhibit Display

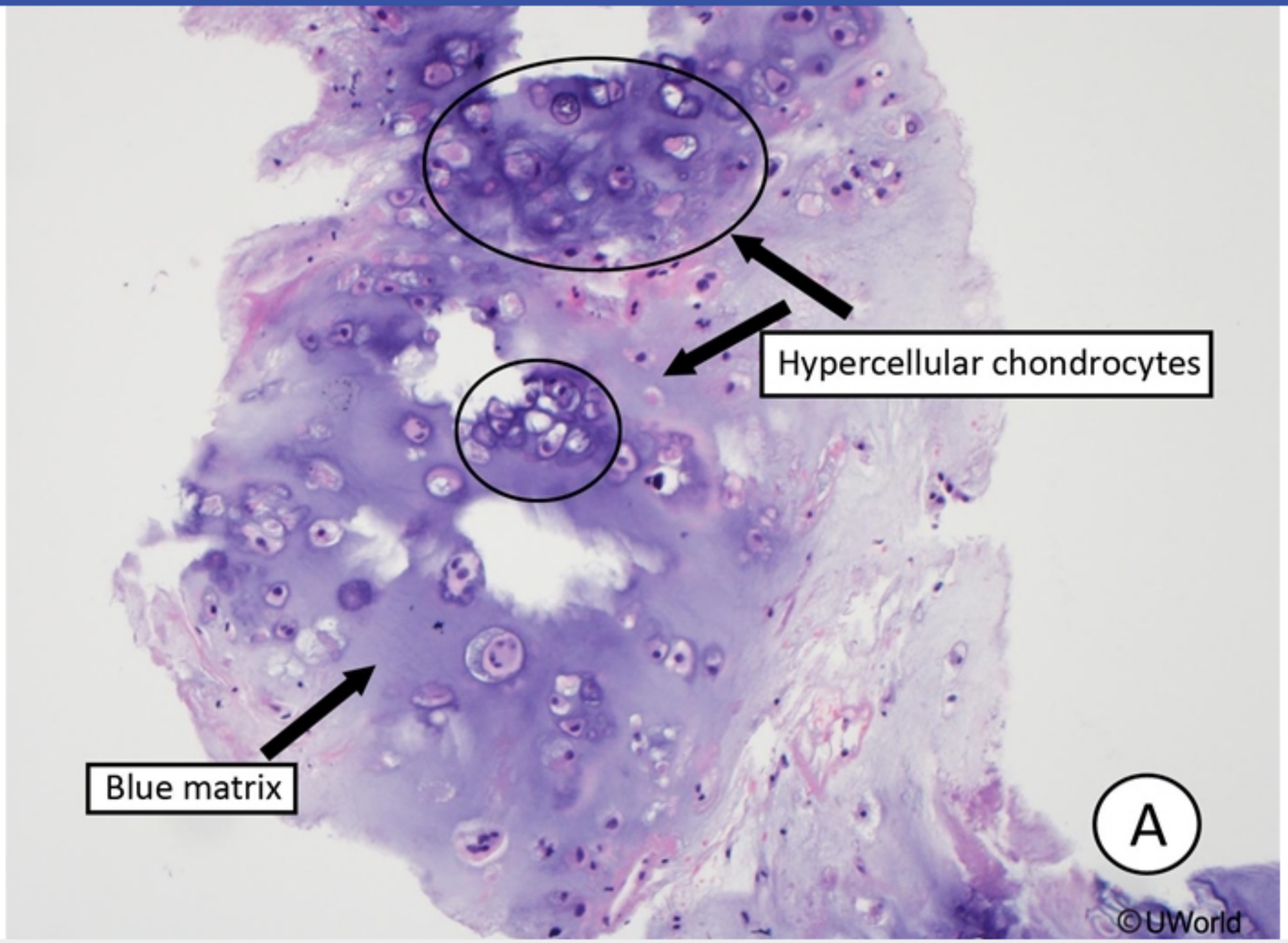

Zoom In | Zoom Out | Reset | Add To New Card | Existing Card

1
2
3
4
5
6
7
8
9
10
11
12
13
14
15
16
17
18
19
20
21
22
23
24
25
26
27
28
29
30

Exhibit Display

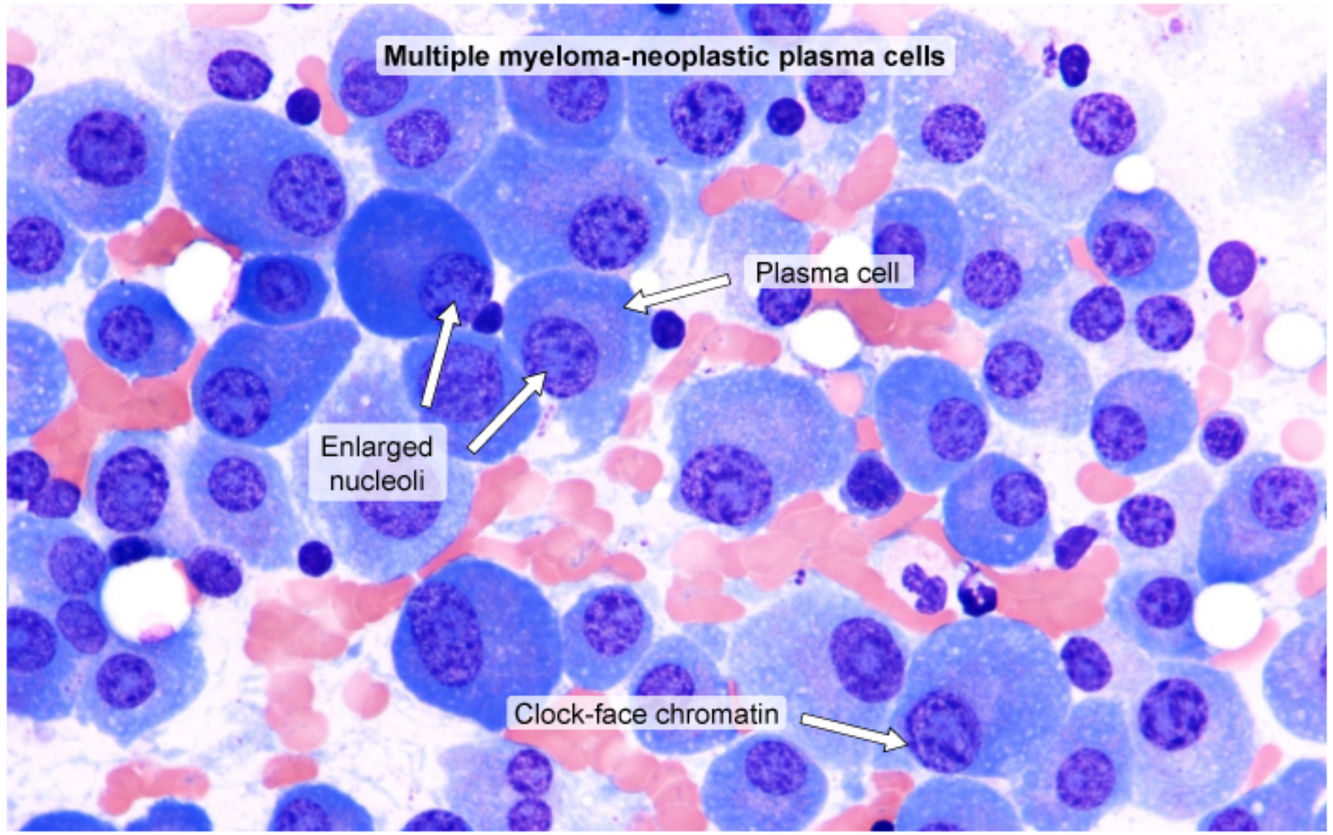

Zoom In | Zoom Out | Reset | Add To New Card | Existing Card

1
2
3
4
5
6
7
8
9
10
11
12
13
14
15
16
17
18
19
20
21
22
23
24
25
26
27
28
29
30

A 55-year-old man undergoing evaluation for fatigue and exertional dyspnea is diagnosed with macrocytic anemia. Upper gastrointestinal endoscopy is consistent with atrophic gastritis. He is started on intramuscular cyanocobalamin, with the resulting changes shown in the graph below.

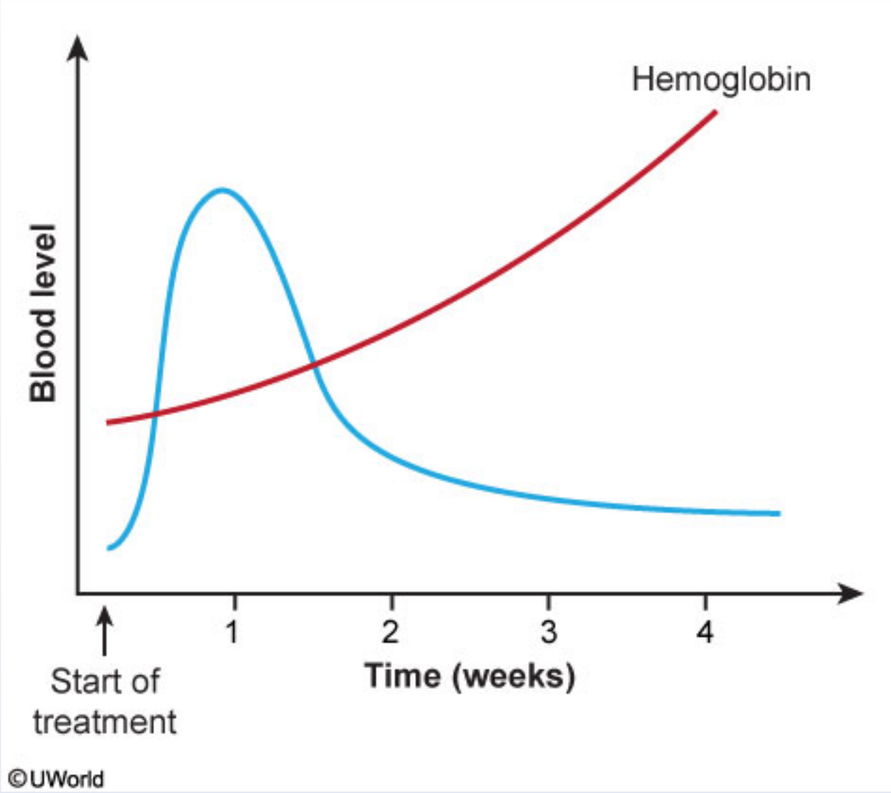

The blue curve most likely corresponds to which of the following parameters?

A. Erythrocyte count

B. Gastrin

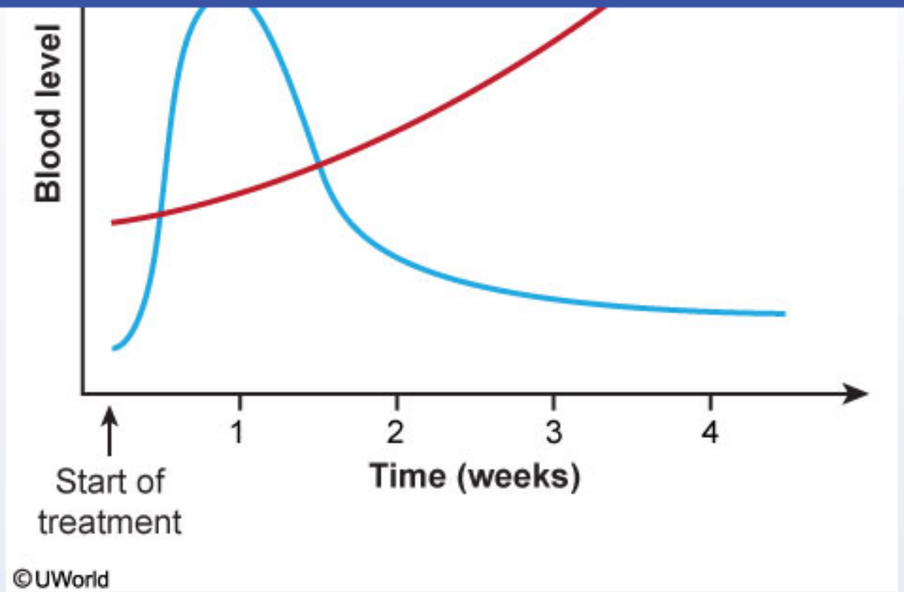

The blue curve most likely corresponds to which of the following parameters?

- A. Erythrocyte count
- B. Gastrin
- C. Haptoglobin
- D. Methylmalonic acid
- E. Reticulocyte count

Submit

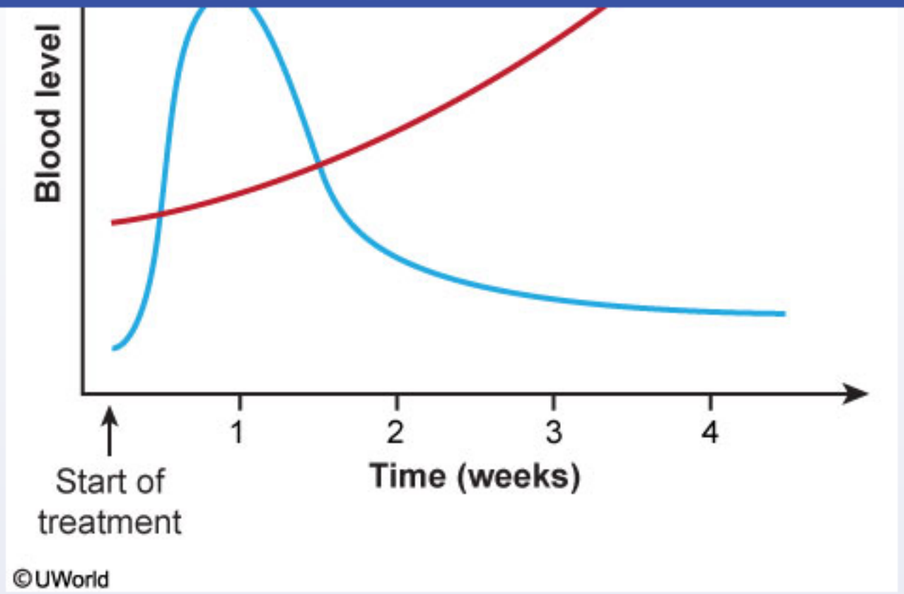

The blue curve most likely corresponds to which of the following parameters?

- A. Erythrocyte count (5%)
- B. Gastrin (2%)
- C. Haptoglobin (5%)
- D. Methylmalonic acid (25%)
- ✓ E. Reticulocyte count (60%)

Omitted
Correct answer

60%
Answered correctly

04 secs
Time Spent

02/05/2020
Last Updated

The graph shows the treatment response to vitamin B_{12} (cyanocobalamin) in a patient with **vitamin B_{12} deficiency** secondary to atrophic gastritis. Vitamin B_{12} deficiency impairs nucleic acid metabolism, causing delayed nuclear maturation and reduced cell division of erythrocyte precursors in the bone marrow (**megaloblastic anemia**).

Once vitamin B_{12}**replacement therapy** is begun, erythrocyte precursors begin to change from megaloblastic to normoblastic. As the rate of effective erythropoiesis increases, immature erythrocytes (**reticulocytes**) are released from the bone marrow into the bloodstream. The peripheral count of these reticulocytes begins rising within 3 to 4 days and **peaks at around 1 week**, as indicated by the blue curve. The reticulocyte response peaks early during vitamin replacement as the reticulocytes that are initially released are left-shifted and take longer to mature in the circulation than later reticulocytes. However, hemoglobin levels (~1 g/week) are slower to rise, and the anemia typically takes as long as 8 weeks to correct.

(Choice A) The erythrocyte count curve would be expected to follow the contour of the hemoglobin curve as the total red blood cell pool returns to normal levels.

(Choice B) In chronic atrophic gastritis, parietal cell loss results in profound hypochlorhydria, increased serum gastrin levels, and inadequate intrinsic factor production. This patient most likely has elevated gastrin levels that would be unaffected by vitamin B_{12} replacement.

(Choice C) Vitamin B_{12} deficiency causes increased red cell breakdown due to ineffective erythropoiesis, and the resulting release of free hemoglobin leads to a decrease in serum haptoglobin levels. Haptoglobin levels would normalize (increase) with therapy.

(Choice D) Homocysteine and methylmalonic acid levels are elevated in vitamin B_{12} deficiency due to decreased metabolism. In contrast, only homocysteine is elevated in folate deficiency. Vitamin B_{12} replacement would cause a reduction in homocysteine and methylmalonic acid levels. However, the blue curve shows a high initial peak before declining, which is more consistent with the reticulocyte response.

Educational objective:
Atrophic gastritis can result in profound hypochlorhydria, inadequate intrinsic factor production, vitamin B_{12} deficiency, and elevated methylmalonic acid levels. The reticulocyte count increases dramatically once vitamin B_{12} replacement therapy is initiated in an individual with pernicious anemia. Hemoglobin and erythrocyte count levels rise more gradually and take up to 8 weeks to normalize.

Pathology Hematology & Oncology Vitamin b12 deficiency

Once vitamin B_{12} **replacement therapy** is begun, erythrocyte precursors begin to change from megaloblastic to normoblastic. As the rate of effective erythropoiesis increases, immature erythrocytes (**reticulocytes**) are released from the bone marrow into the bloodstream. The peripheral count of these reticulocytes begins rising within 3 to 4 days and **peaks at around 1 week**, as indicated by the blue curve. The reticulocyte response peaks early during vitamin replacement as the reticulocytes that are initially released are left-shifted and take longer to mature in the circulation than later reticulocytes. However, hemoglobin levels (~1 g/week) are slower to rise, and the anemia typically takes as long as 8 weeks to correct.

(Choice A) The erythrocyte count curve would be expected to follow the contour of the hemoglobin curve as the total red blood cell pool returns to normal levels.

(Choice B) In chronic atrophic gastritis, parietal cell loss results in profound hypochlorhydria, increased serum gastrin levels, and inadequate intrinsic factor production. This patient most likely has elevated gastrin levels that would be unaffected by vitamin B_{12} replacement.

(Choice C) Vitamin B_{12} deficiency causes increased red cell breakdown due to ineffective erythropoiesis, and the resulting release of free hemoglobin leads to a decrease in serum haptoglobin levels. Haptoglobin levels would normalize (increase) with therapy.

(Choice D) Homocysteine and methylmalonic acid levels are elevated in vitamin B_{12} deficiency due to decreased metabolism. In contrast, only homocysteine is elevated in folate deficiency. Vitamin B_{12} replacement would cause a reduction in homocysteine and methylmalonic acid levels. However, the blue curve shows a high initial peak before declining, which is more consistent with the reticulocyte response.

Educational objective:
Atrophic gastritis can result in profound hypochlorhydria, inadequate intrinsic factor production, vitamin B_{12} deficiency, and elevated methylmalonic acid levels. The reticulocyte count increases dramatically once vitamin B_{12} replacement therapy is initiated in an individual with pernicious anemia. Hemoglobin and erythrocyte count levels rise more gradually and take up to 8 weeks to normalize.

Pathology	Hematology & Oncology	Vitamin b12 deficiency
Subject	System	Topic

Copyright © UWorld. All rights reserved.

1
2
3
4
5
6
7
8
9
10
11
12
13
14
15
16
17
18
19
20
21
22
23
24
25
26
27
28
29
30

A 16-year-old previously healthy boy is brought to the office due to fever, malaise, and sore throat. The patient says that he gets tired even by simply getting out of bed. Physical examination shows palatal petechiae, cervical lymphadenopathy, and splenomegaly. His peripheral blood smear is shown in the image below.

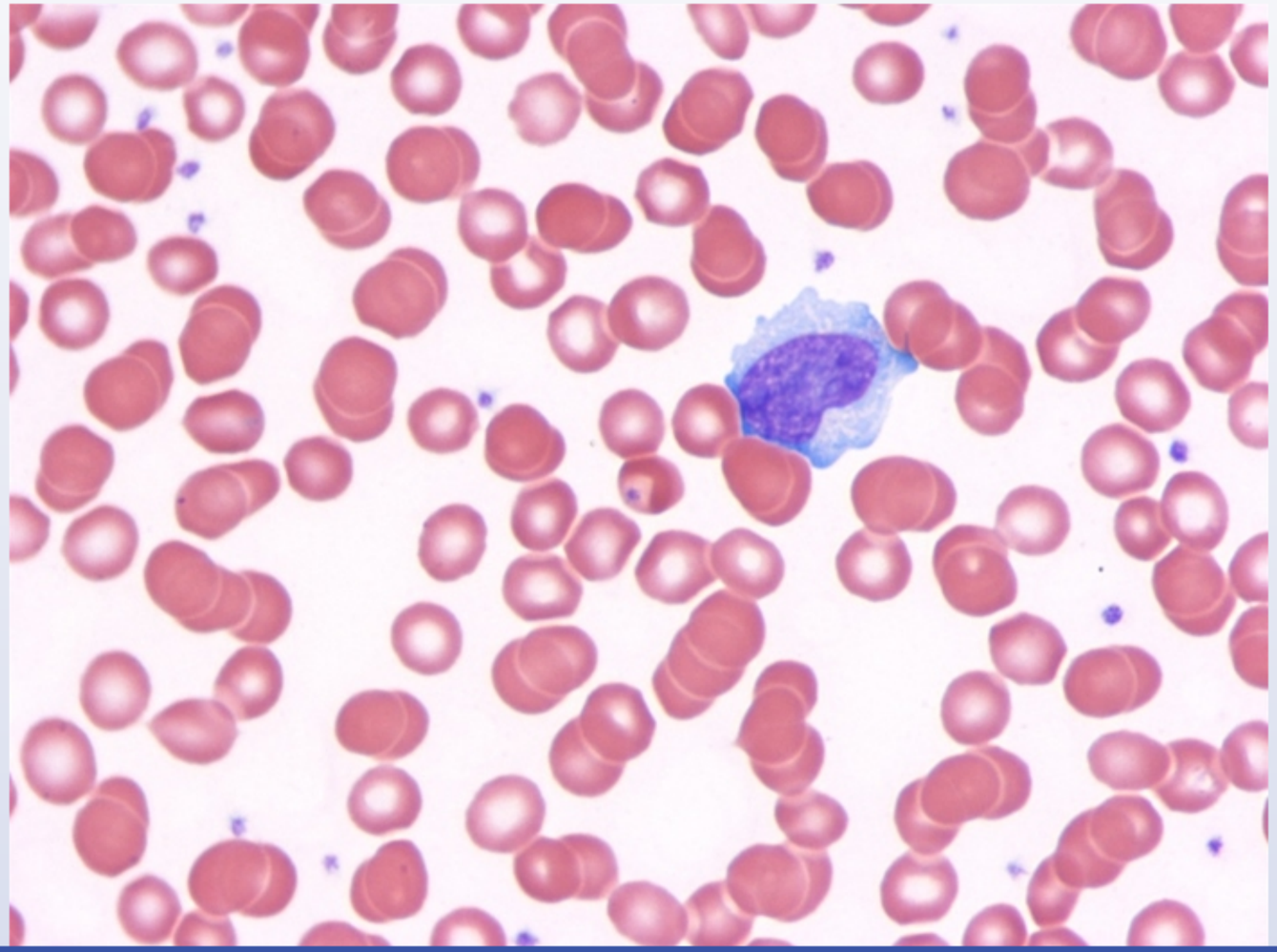

1
2
3
4
5
6
7
8
9
10
11
12
13
14
15
16
17
18
19
20
21
22
23
24
25
26
27
28
29
30

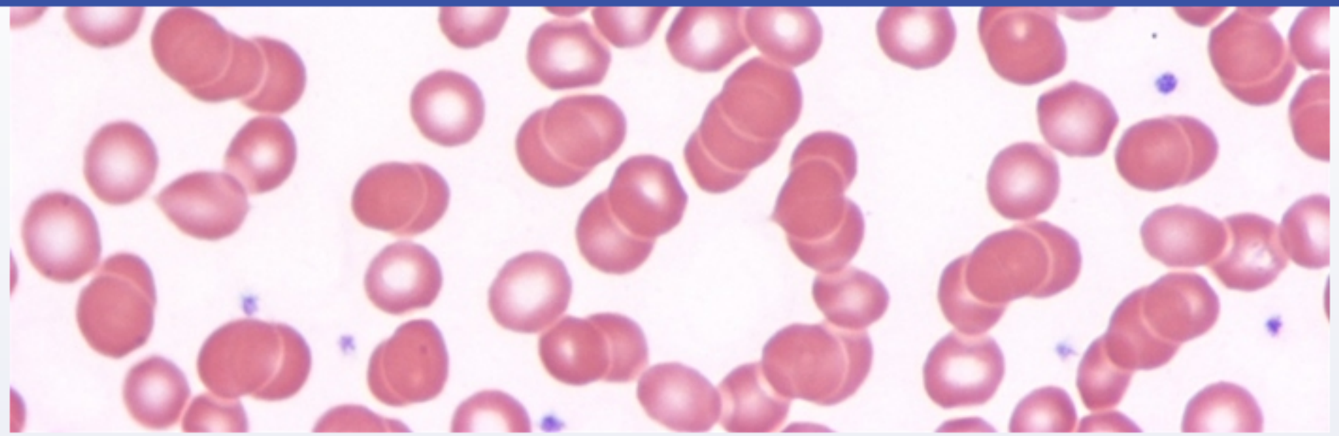

Horse erythrocytes agglutinate when exposed to the patient's serum. The agent causing this patient's disease is most strongly associated with which of the following malignancies?

- A. Acute myeloid leukemia
- B. Cervical carcinoma
- C. Hepatocellular carcinoma
- D. Kaposi sarcoma
- E. Mucosa-associated lymphoid tissue tumor
- F. Multiple myeloma
- G. Nasopharyngeal carcinoma

Submit

1
2
3
4
5
6
7
8
9
10
11
12
13
14
15
16
17
18
19
20
21
22
23
24
25
26
27
28
29
30

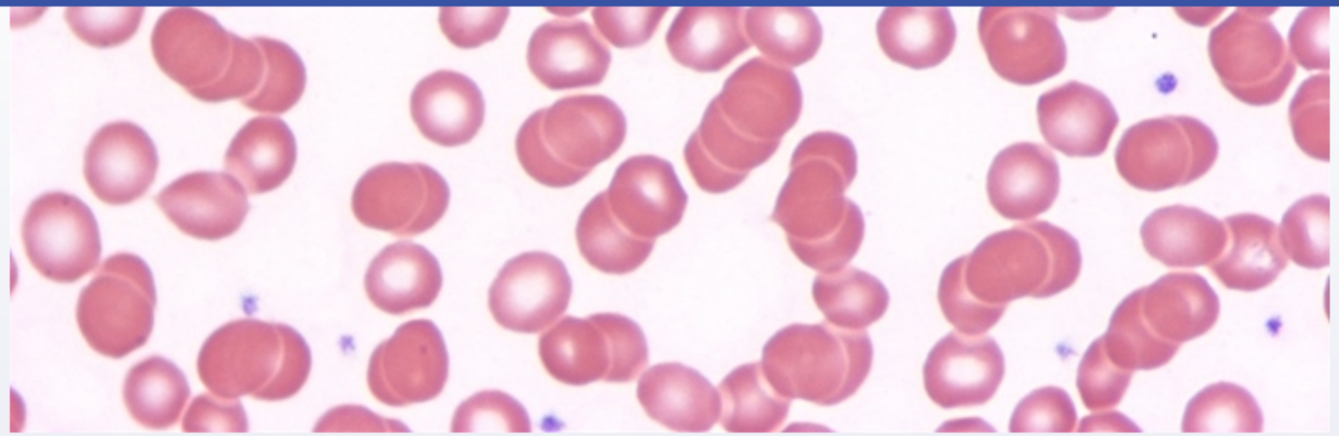

Horse erythrocytes agglutinate when exposed to the patient's serum. The agent causing this patient's disease is most strongly associated with which of the following malignancies?

- A. Acute myeloid leukemia
- B. Cervical carcinoma
- C. Hepatocellular carcinoma
- D. Kaposi sarcoma
- E. Mucosa-associated lymphoid tissue tumor
- F. Multiple myeloma
- G. Nasopharyngeal carcinoma

Submit

1
2
3
4
5
6
7
8
9
10
11
12
13
14
15
16
17
18
19
20
21
22
23
24
25
26
27
28
29
30

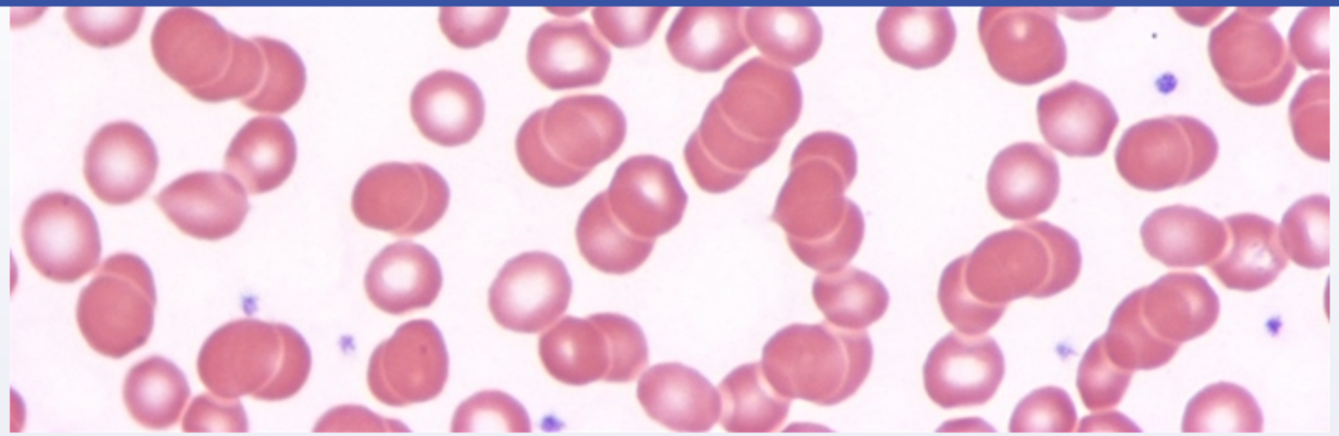

Horse erythrocytes agglutinate when exposed to the patient's serum. The agent causing this patient's disease is most strongly associated with which of the following malignancies?

A. Acute myeloid leukemia (8%)

B. Cervical carcinoma (0%)

C. Hepatocellular carcinoma (0%)

D. Kaposi sarcoma (3%)

E. Mucosa-associated lymphoid tissue tumor (4%)

F. Multiple myeloma (9%)

✓ G. Nasopharyngeal carcinoma (72%)

Omitted
Correct answer

72%
Answered correctly

09 secs
Time Spent

06/01/2020
Last Updated

1
2
3
4
5
6
7
8
9
10
11
12
13
14
15
16
17
18
19
20
21
22
23
24
25
26
27
28
29
30

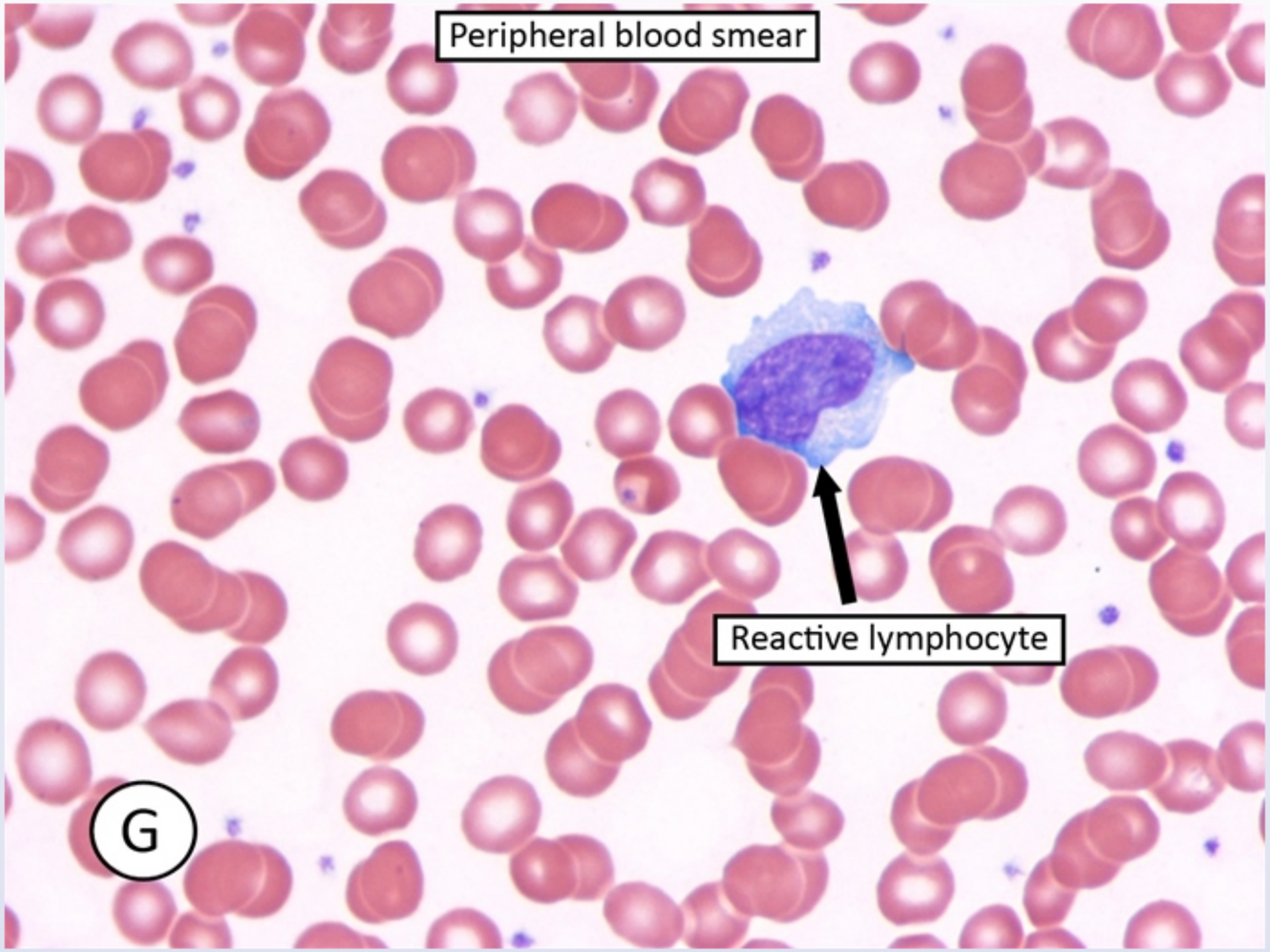

Sore throat, moderate to high fever, palatal petechiae, **lymphadenopathy** (commonly posterior cervical or auricular), splenomegaly, and **atypical** (reactive) **lymphocytosis** are classic signs and symptoms of **infectious mononucleosis**, a disease common among teenagers and young adults. Ninety percent of cases of infectious mononucleosis are caused by the **Epstein-Barr virus** (EBV); however, cytomegalovirus, HIV, and

Sore throat, moderate to high fever, palatal petechiae, **lymphadenopathy** (commonly posterior cervical or auricular), splenomegaly, and **atypical** (reactive) **lymphocytosis** are classic signs and symptoms of **infectious mononucleosis**, a disease common among teenagers and young adults. Ninety percent of cases of infectious mononucleosis are caused by the **Epstein-Barr virus** (EBV); however, cytomegalovirus, HIV, and *Toxoplasma* are some of the other agents known to cause non-EBV infectious mononucleosis. EBV infection induces **heterophile antibodies**, which react to antigens from animal erythrocytes (sheep in the Paul-Bunnell test and horse in the Monospot test). The heterophile antibody tests are sensitive and specific for EBV-associated infectious mononucleosis.

EBV replicates primarily in B lymphocytes and is also associated with **malignancies**, including **Burkitt lymphoma** (especially the endemic African type) and **nasopharyngeal carcinoma**. Many disorders in immunocompromised patients are caused by EBV, including central nervous system lymphoma in HIV-positive patients and post-transplant lymphoproliferative disorder (PTLD) in allograft recipients.

(Choices A and F) There is no classic association between acute myeloid leukemia or multiple myeloma and viral infection.

(Choice B) Cervical carcinoma is strongly associated with human papillomavirus (types 16, 18, 31, and 33) infection.

(Choice C) Chronic infection with either hepatitis B or C virus significantly increases the risk of hepatocellular carcinoma.

(Choice D) Kaposi sarcoma is strongly associated with HIV and human herpes virus type 8 infections.

(Choice E) Gastric adenocarcinoma and mucosa-associated lymphoid tissue tumor (MALToma) are associated with *Helicobacter pylori* infection.

Educational objective:
Epstein-Barr virus causes infectious mononucleosis in teenagers and young adults. It is also associated with a number of malignant conditions, including Burkitt lymphoma and nasopharyngeal carcinoma.

Pathology	Hematology & Oncology	Infectious mononucleosis
Subject	System	Topic

Copyright © UWorld. All rights reserved.

1
2
3
4
5
6
7
8
9
10
11
12
13
14
15
16
17
18
19
20
21
22
23
24
25
26
27
28
29
30

A 62-year-old woman comes to the physician after finding a lump in her breast. Physical examination reveals a firm, immovable, irregularly shaped mass. Mammography is performed and shows a spiculated, calcified lesion that was not seen on prior studies. A tissue biopsy is diagnostic for infiltrating ductal carcinoma. Malignant tumors such as infiltrating ductal carcinoma are typically associated with varying degrees of disordered differentiation and maturation. Which of the following findings is most characteristic of an anaplastic tumor?

A. Brain tumor cells forming giant cells

B. Bronchial epithelial cells producing keratin pearls

C. Colonic tumor cells creating glands

D. Hepatic tumor cells synthesizing bile

E. Skin tumor cells producing keratin pearls

Submit

A 62-year-old woman comes to the physician after finding a lump in her breast. Physical examination reveals a firm, immovable, irregularly shaped mass. Mammography is performed and shows a spiculated, calcified lesion that was not seen on prior studies. A tissue biopsy is diagnostic for infiltrating ductal carcinoma. Malignant tumors such as infiltrating ductal carcinoma are typically associated with varying degrees of disordered differentiation and maturation. Which of the following findings is most characteristic of an anaplastic tumor?

- ✓ A. Brain tumor cells forming giant cells (49%)
- B. Bronchial epithelial cells producing keratin pearls (31%)
- C. Colonic tumor cells creating glands (7%)
- D. Hepatic tumor cells synthesizing bile (3%)
- E. Skin tumor cells producing keratin pearls (8%)

Omitted
Correct answer
A

49%
Answered correctly

02 secs
Time Spent

06/04/2020
Last Updated

Explanation

Well differentiated (low-grade) tumors contain neoplastic cells that are morphologically and architecturally similar to normal cells in the tissue of origin. In contrast, poorly differentiated (high-grade) tumors contain neoplastic cells that lack most of the characteristic features of the original tissue. Neoplasms that contain cells in the midst of this spectrum are termed moderately differentiated (medium-grade). Neoplastic cells that demonstrate a complete lack of differentiation are termed anaplastic.

Anaplastic tumors typically demonstrate the following features:

1 2 3 4 5 6 7 8 9 10 11 12 13 14 15 16 17 18 19 20 21 22 23 24 25 26 27 28 29 30

Well differentiated (low-grade) tumors contain neoplastic cells that are morphologically and architecturally similar to normal cells in the tissue of origin. In contrast, poorly differentiated (high-grade) tumors contain neoplastic cells that lack most of the characteristic features of the original tissue. Neoplasms that contain cells in the midst of this spectrum are termed moderately differentiated (medium-grade). Neoplastic cells that demonstrate a complete lack of differentiation are termed anaplastic.

Anaplastic tumors typically demonstrate the following features:

1. Loss of cell polarity with complete disruption of normal tissue architecture; cells coalesce into sheets or islands in a disorganized, infiltrative fashion (example, compare to normal)
2. Significant variation in the shape and size of cells (cellular pleomorphism) and nuclei (nuclear pleomorphism)
3. Disproportionately large nuclei (high nucleus-to-cytoplasm ratio) that are often deep-staining (hyperchromatic) with abundant, coarsely-clumped chromatin and large nucleoli (example)
4. Numerous, often abnormal, mitotic figures
5. Giant, multinucleated tumor cells**(Choice A)**

(Choices B and E) The production of keratin pearls by skin tumor cells is an example of dysplasia (ie, disordered growth). The fact that they produce keratin means that the tumor cells are well differentiated. Bronchial epithelial cells can also produce keratin pearls after undergoing a phenotypic switch from columnar epithelium to squamous epithelium. The process of switching from one differentiated cell type to another is known as metaplasia and often occurs in response to irritants (eg, tobacco smoke or gastric acid).

(Choices C and D) Cells in the colon normally form goblet cell-containing glands and cells in hepatic tissue normally synthesize bile. Therefore, the described tumor cells would be well-differentiated, not anaplastic.

Educational objective:
Undifferentiated (anaplastic) tumors bear no resemblance to the tissue of origin. They are composed of pleomorphic cells with large, hyperchromatic nuclei that grow in a disorganized fashion. Anaplastic tumors may also contain numerous, abnormal mitoses and giant tumor cells.

Pathology Hematology & Oncology Breast cancer

1
2
3
4
5
6
7
8
9
10
11
12
13
14
15
16
17
18
19
20
21
22
23
24
25
26
27
28
29
30

Exhibit Display

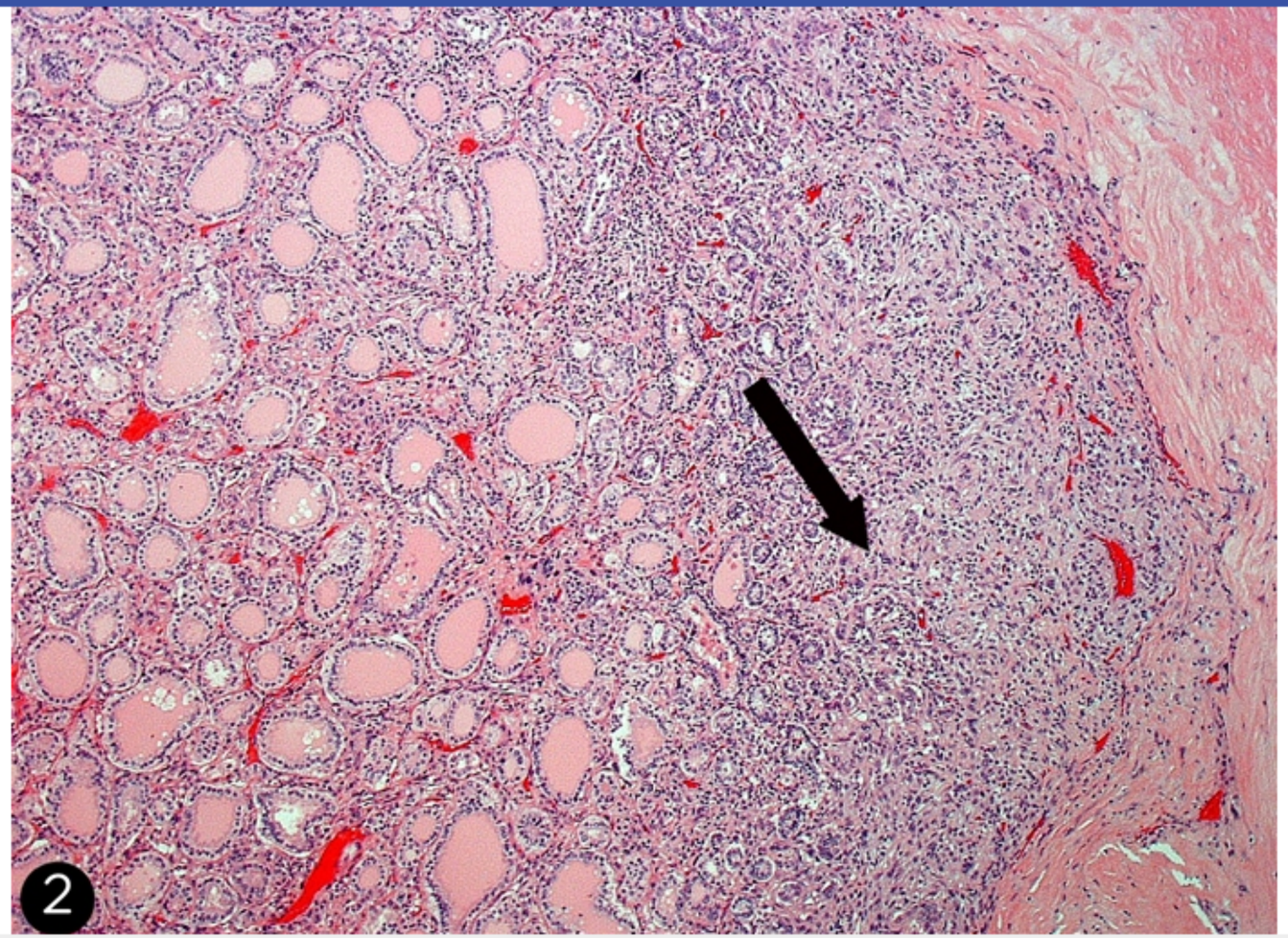

Zoom In
Zoom Out
Reset
Add To New Card | Existing Card

Pathology
Hematology & Oncology
Breast cancer

1
2
3
4
5
6
7
8
9
10
11
12
13
14
15
16
17
18
19
20
21
22
23
24
25
26
27
28
29
30

Exhibit Display

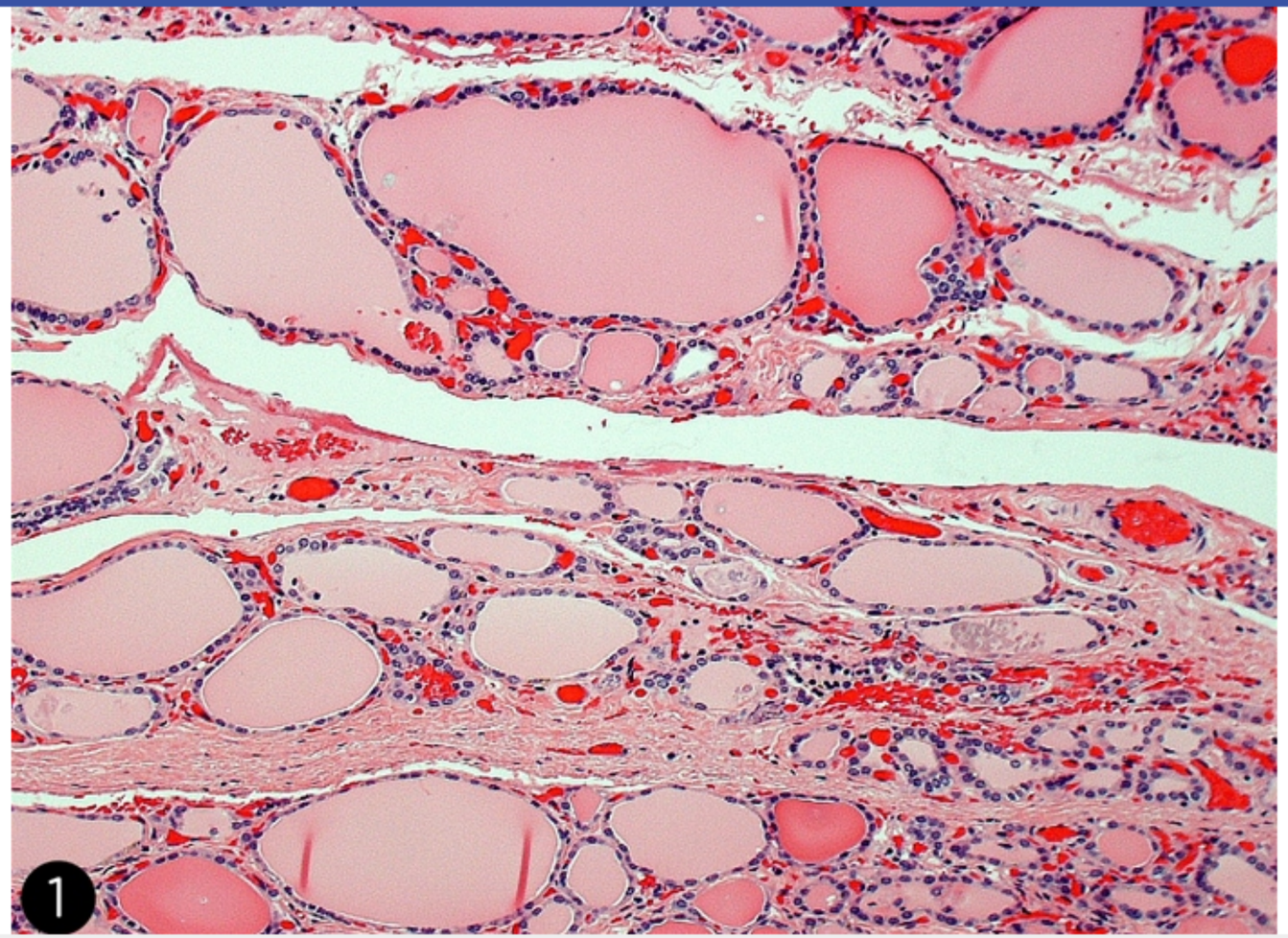

Zoom In
Zoom Out
Reset
Add To New Card | Existing Card

Pathology
Hematology & Oncology
Breast cancer

1
2
3
4
5
6
7
8
9
10
11
12
13
14
15
16
17
18
19
20
21
22
23
24
25
26
27
28
29
30

Exhibit Display

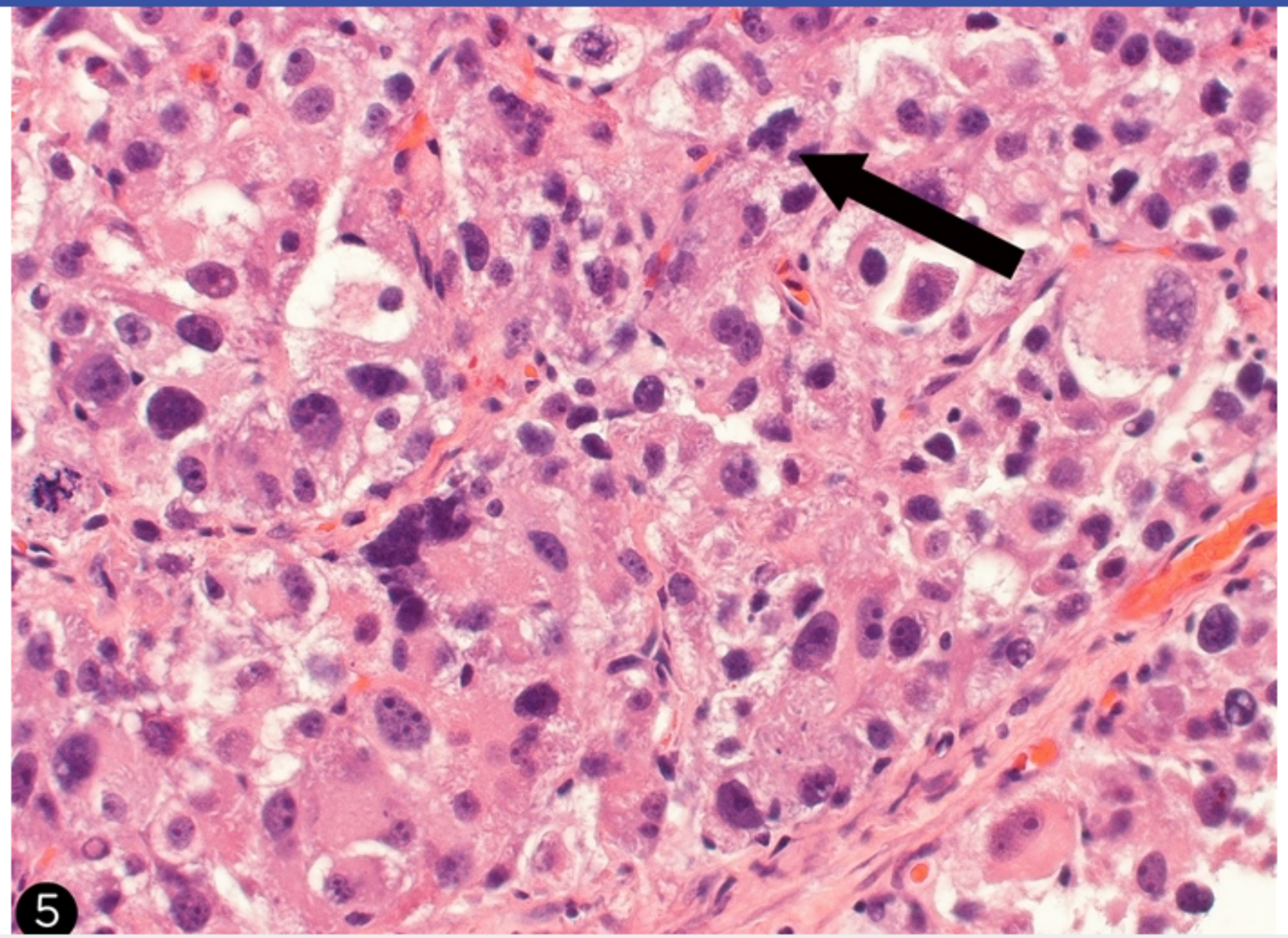

Zoom In | Zoom Out | Reset | Add To New Card | Existing Card

Pathology | Hematology & Oncology | Breast cancer

1
2
3
4
5
6
7
8
9
10
11
12
13
14
15
16
17
18
19
20
21
22
23
24
25
26
27
28
29
30

Exhibit Display

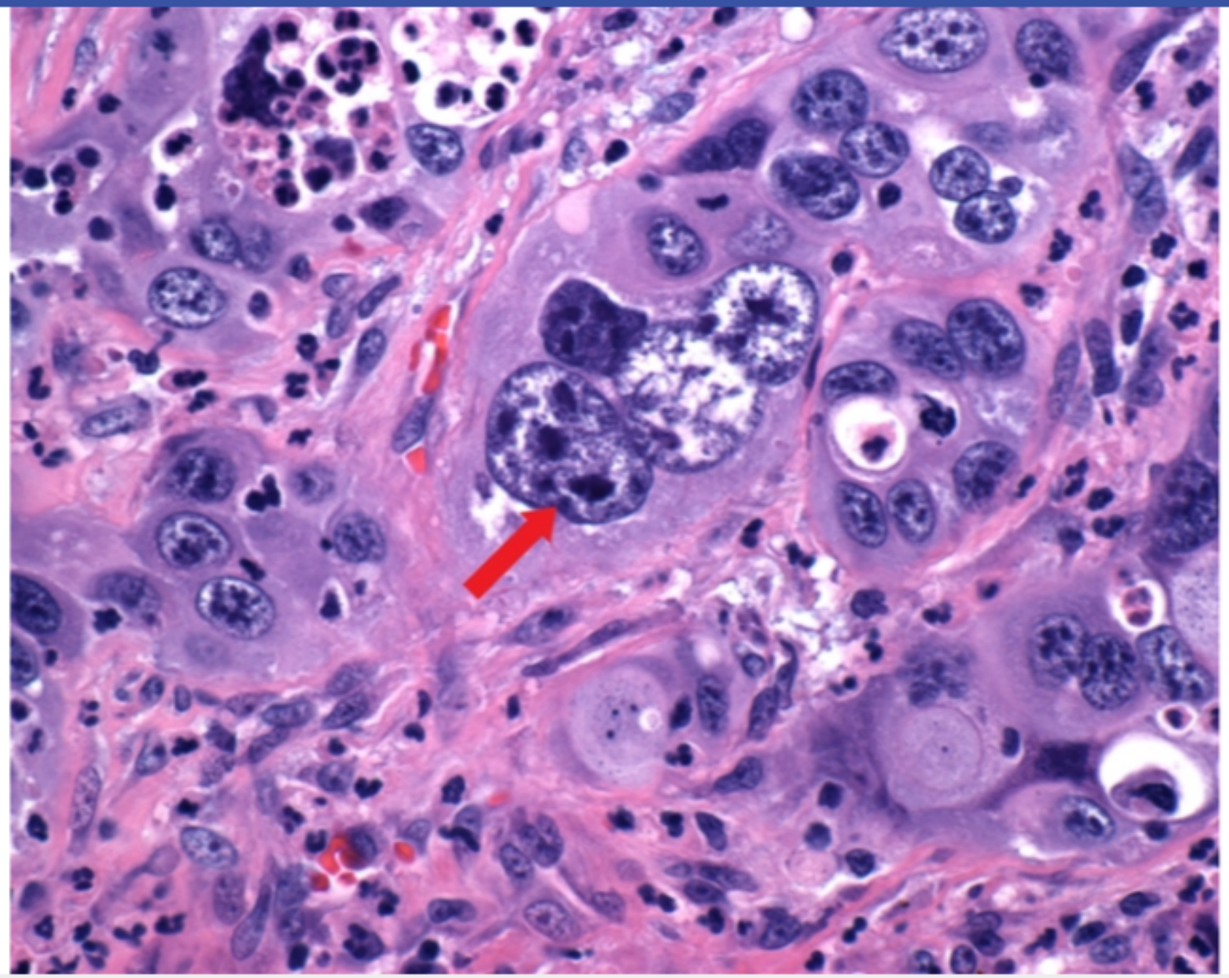

Zoom In | Zoom Out | Reset | Add To New Card | Existing Card

Pathology | Hematology & Oncology | Breast cancer

1
2
3
4
5
6
7
8
9
10
11
12
13
14
15
16
17
18
19
20
21
22
23
24
25
26
27
28
29
30

Exhibit Display

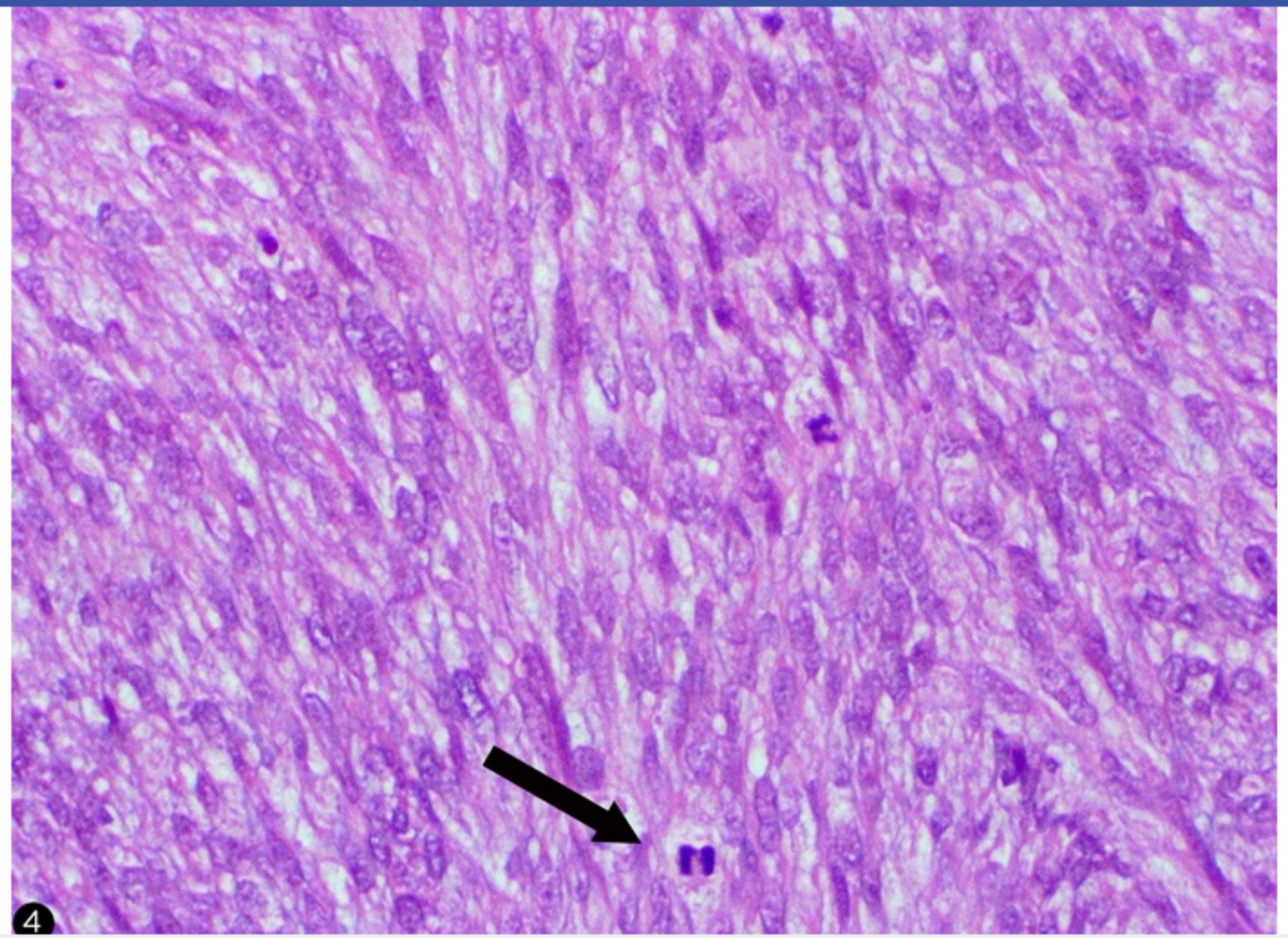

Zoom In | Zoom Out | Reset | Add To New Card | Existing Card

Pathology | Hematology & Oncology | Breast cancer

1
2
3
4
5
6
7
8
9
10
11
12
13
14
15
16
17
18
19
20
21
22
23
24
25
26
27
28
29
30

Exhibit Display

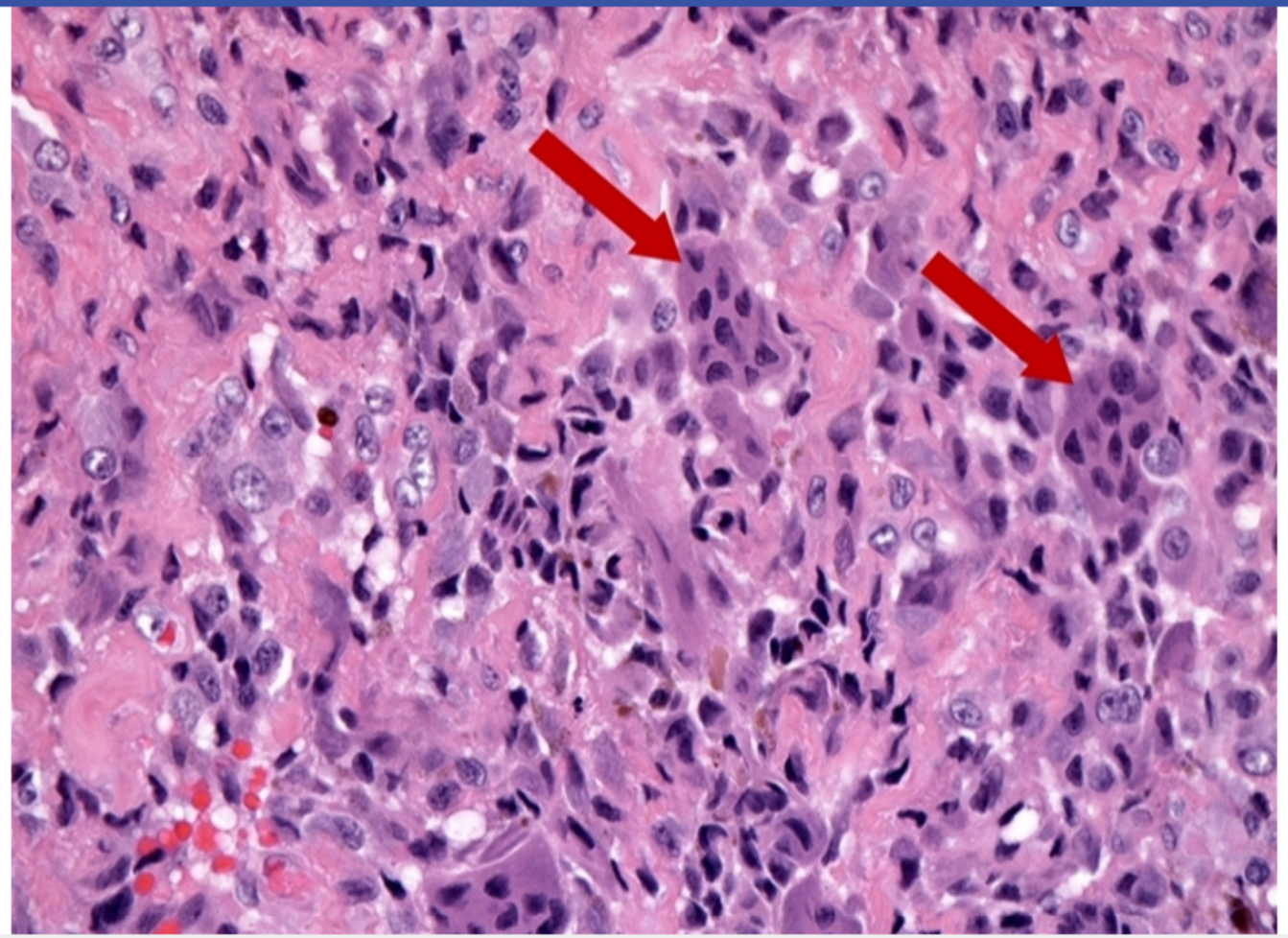

Zoom In | Zoom Out | Reset | Add To New Card | Existing Card

Pathology | Hematology & Oncology | Breast cancer

A 20-year-old man is brought to the emergency department due to a day of fever, headache, and neck pain. He has no significant medical history. Temperature is 38.7 C (101.7 F), blood pressure is 120/72 mm Hg, pulse is 112/min, and respirations are 26/min. There is neck stiffness and a petechial rash on the trunk. Cerebrospinal fluid (CSF) analysis reveals the following:

Glucose	30 mg/dL
Protein	180 mg/dL
Leukocytes	1,500/mm^3
Neutrophils	70%

CSF gram stain shows gram-negative diplococci. In the emergency department, the patient's hemodynamic status deteriorates rapidly. Blood pressure drops to 80/50 mm Hg, and the venous access sites are oozing blood. Which of the following findings is most likely to be seen on this patient's peripheral smear?

A. Atypical lymphocytosis
B. Howell-Jolly bodies
C. Hypersegmented neutrophils
D. Reactive thrombocytosis
E. Schistocytes
F. Severe pancytopenia

Submit

1
2
3
4
5
6
7
8
9
10
11
12
13
14
15
16
17
18
19
20
21
22
23
24
25
26
27
28
29
30

Exhibit Display

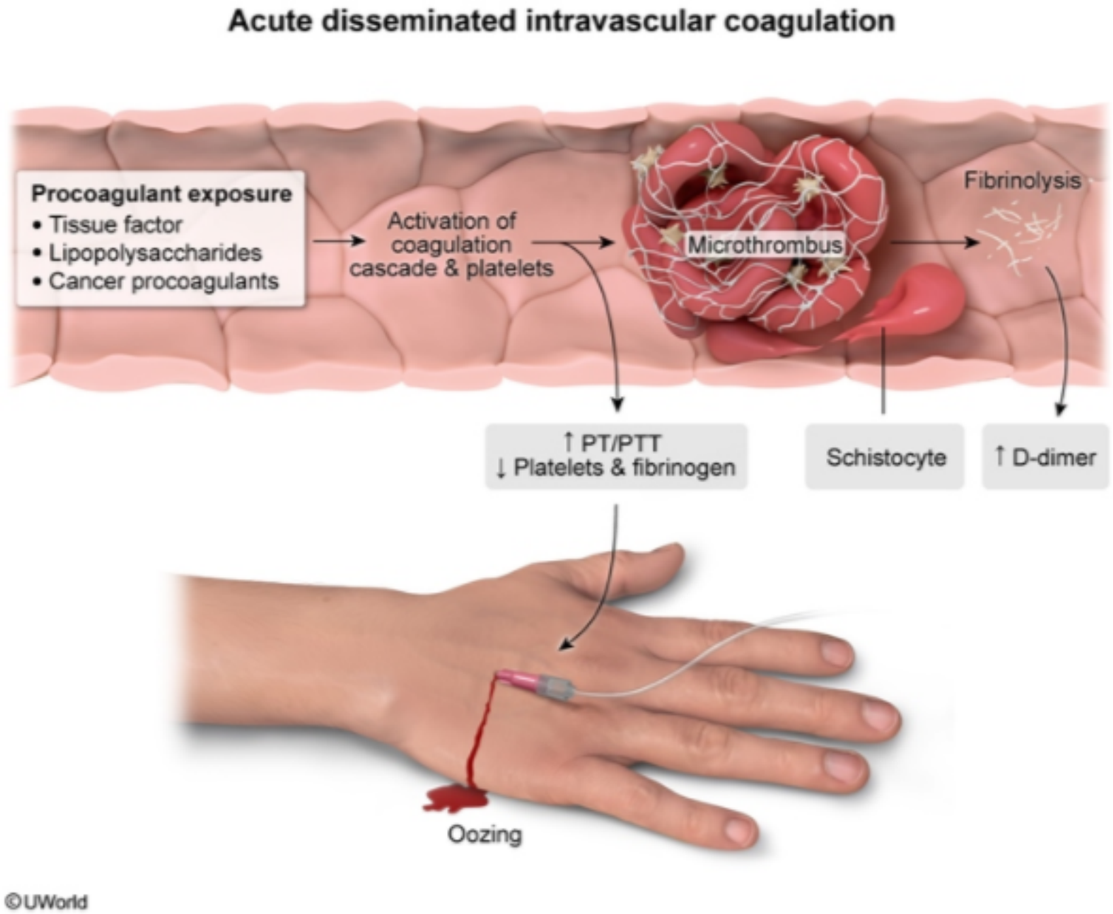

Zoom In | Zoom Out | Reset | Add To New Card | Existing Card

A 20-year-old man is brought to the emergency department due to a day of fever, headache, and neck pain. He has no significant medical history. Temperature is 38.7 C (101.7 F), blood pressure is 120/72 mm Hg, pulse is 112/min, and respirations are 26/min. There is neck stiffness and a petechial rash on the trunk. Cerebrospinal fluid (CSF) analysis reveals the following:

Glucose	30 mg/dL
Protein	180 mg/dL
Leukocytes	1,500/mm^3
Neutrophils	70%

CSF gram stain shows gram-negative diplococci. In the emergency department, the patient's hemodynamic status deteriorates rapidly. Blood pressure drops to 80/50 mm Hg, and the venous access sites are oozing blood. Which of the following findings is most likely to be seen on this patient's peripheral smear?

A. Atypical lymphocytosis (2%)
B. Howell-Jolly bodies (6%)
C. Hypersegmented neutrophils (4%)
D. Reactive thrombocytosis (18%)
✓ E. Schistocytes (56%)
F. Severe pancytopenia (11%)

Omitted
Correct answer
E

56%
Answered correctly

02 secs
Time Spent

06/29/2020
Last Updated

1
2
3
4
5
6
7
8
9
10
11
12
13
14
15
16
17
18
19
20
21
22
23
24
25
26
27
28
29
30

Acute disseminated intravascular coagulation

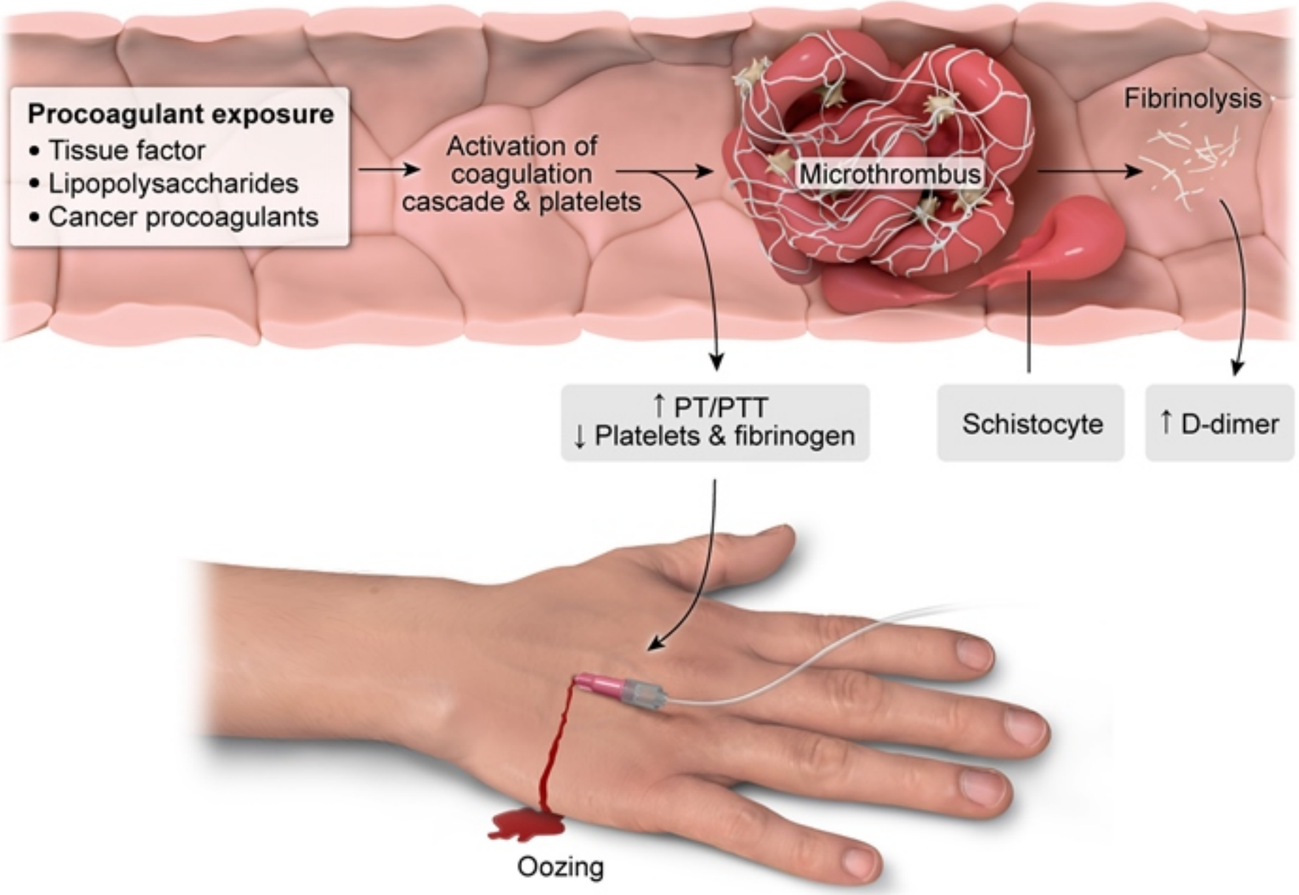

©UWorld

©UWorld

This patient's clinical findings (fever, headache, neck stiffness, rash) and cerebrospinal fluid analysis (elevated protein, low glucose, leukocytosis, gram-negative diplococci) are indicative of **meningococcal meningitis**; he subsequently developed septic shock (severe hypotension) while in the emergency department. His **bleeding** from venous puncture sites is highly suggestive of **disseminated intravascular coagulation** (DIC), a consumptive coagulopathy associated with **sepsis**, malignancy, trauma, and obstetric complications.

In DIC due to gram-negative sepsis, the coagulation cascade is activated by bacterial **endotoxins**, leading to widespread fibrin deposition and the consumption of coagulation factors and platelets, with eventual bleeding. Deposition of fibrin strands in small vessels can cause shearing of circulating erythrocytes, resulting in schistocytes (fragmented erythrocytes) on peripheral smear. Laboratory values in DIC typically show **decreased platelet count** and fibrinogen level and **prolonged PT and PTT** (indicating a consumption of coagulation factors).

(Choice A) Atypical lymphocytes are reactive lymphocytes with abundant, pale-blue cytoplasm and large nuclei. They are often seen in viral infections, particularly infectious mononucleosis.

(Choice B) Howell-Jolly bodies are round, dark, purple/red inclusions within erythrocytes. These represent nuclear fragments that are typically removed by the spleen; they can be seen in patients with splenectomy or reduced splenic function (eg, sickle cell).

(Choice C) Hypersegmented neutrophils are characterized by nuclei with ≥5 lobes. They are a feature of megaloblastic anemia (vitamin B_{12} or folate deficiency).

(Choice D) Reactive thrombocytosis is common in infection due to cytokine-mediated megakaryocyte proliferation and the release of platelets into the peripheral bloodstream. However, patients with DIC have excessive consumption of platelets due to the formation of microthrombi; therefore, they have thrombocytopenia, not thrombocytosis.

(Choice F) Severe pancytopenia is often seen in patients with aplastic anemia, which is characterized by destruction of hematopoietic stem cells and profoundly hypocellular bone marrow. Although patients with severe pancytopenia are at risk for bleeding, oozing from venipuncture sites in the setting of sepsis almost always indicates DIC.

Educational objective:
Disseminated intravascular coagulation is a common complication of gram-negative bacterial sepsis due to activation of the coagulation cascade by bacterial endotoxins, which leads to the formation of microthrombi. Peripheral smear shows fragmented erythrocytes (schistocytes) and

©UWorld

Exhibit Display

Schistocytes

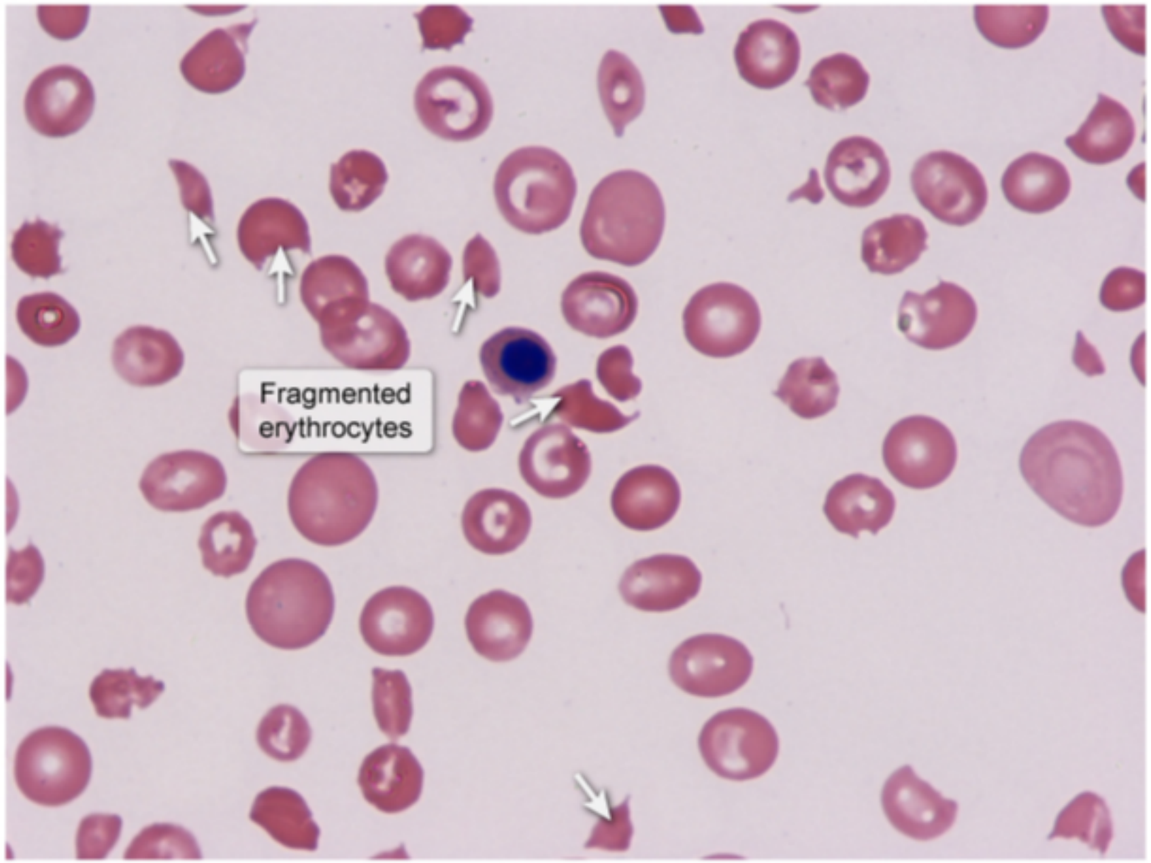

Zoom In | Zoom Out | Reset | Add To New Card | Existing Card

by bacterial endotoxins, which leads to the formation of microthrombi. Peripheral smear shows fragmented erythrocytes (schistocytes) and

©UWorld

Exhibit Display

Atypical CD8+ T lymphocyte

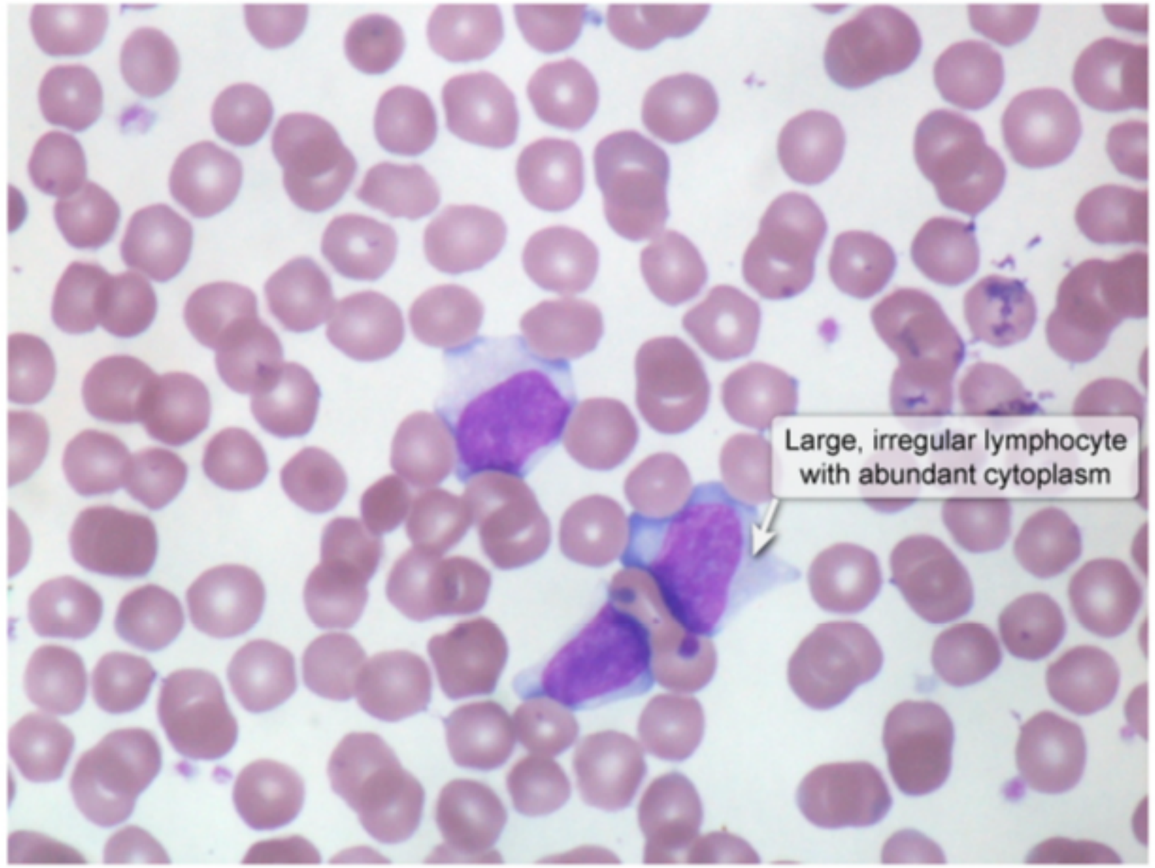

Zoom In | Zoom Out | Reset | Add To New Card | Existing Card

by bacterial endotoxins, which leads to the formation of microthrombi. Peripheral smear shows fragmented erythrocytes (schistocytes) and

©UWorld

Exhibit Display

Patient with splenectomy

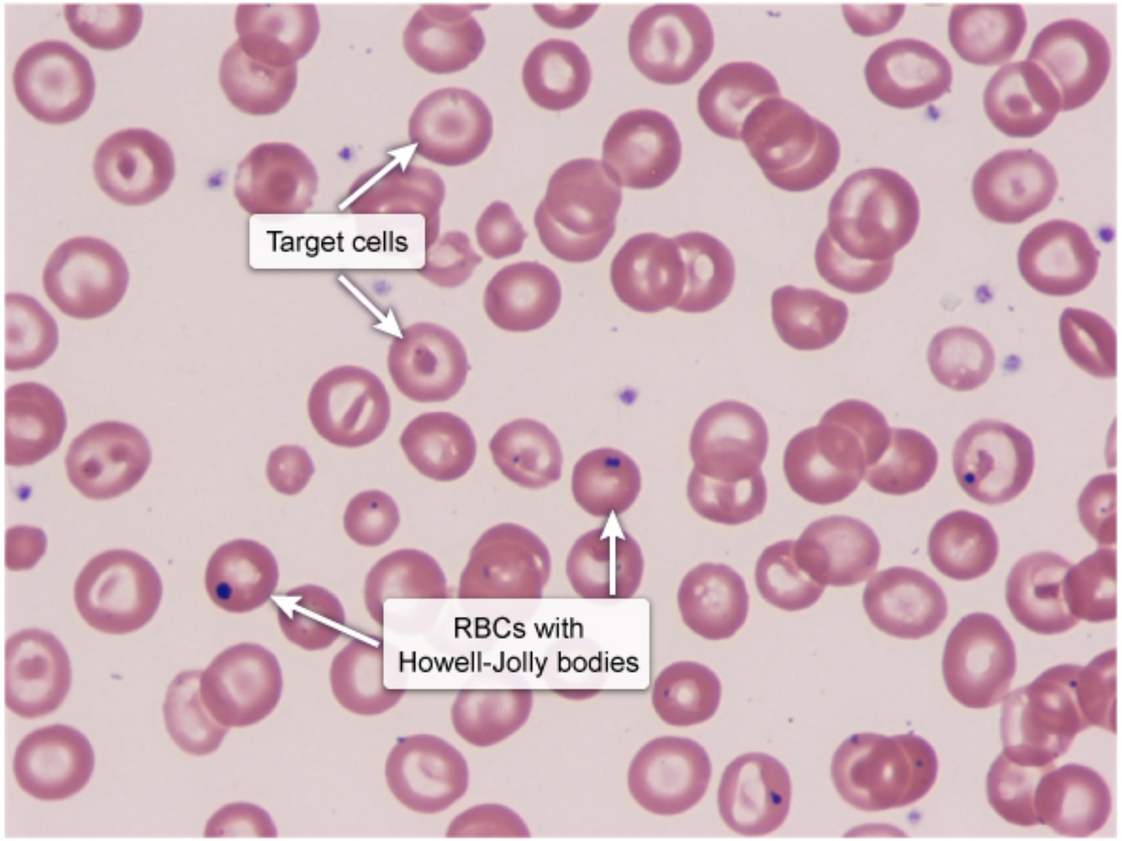

©UWorld

Zoom In | Zoom Out | Reset | Add To New Card | Existing Card

by bacterial endotoxins, which leads to the formation of microthrombi. Peripheral smear shows fragmented erythrocytes (schistocytes) and

©UWorld

Exhibit Display

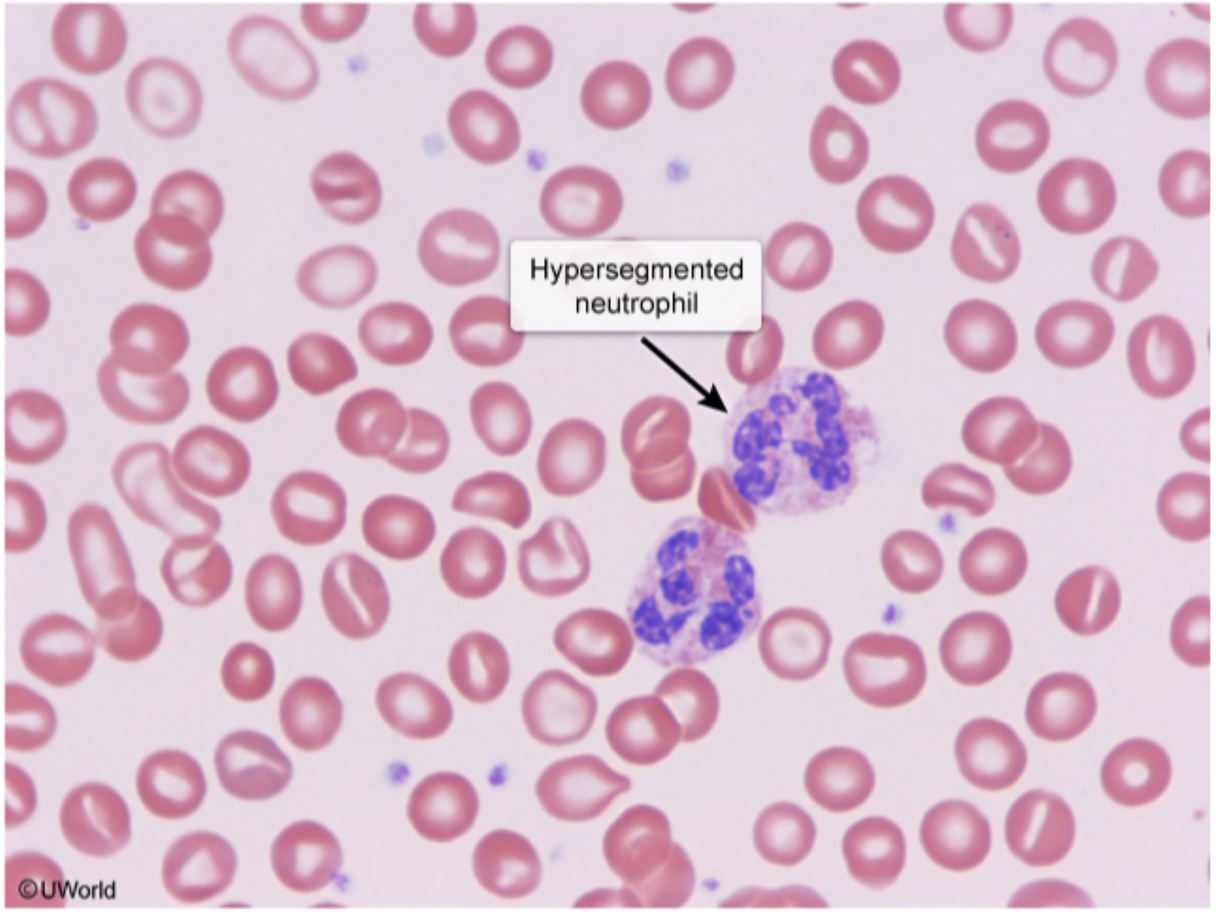

Zoom In | Zoom Out | Reset | Add To New Card | Existing Card

by bacterial endotoxins, which leads to the formation of microthrombi. Peripheral smear shows fragmented erythrocytes (schistocytes) and

1
2
3
4
5
6
7
8
9
10
11
12
13
14
15
16
17
18
19
20
21
22
23
24
25
26
27
28
29
30

A 54-year-old male presents with an enlarged left-sided supraclavicular lymph node. The node is painless and stony hard on palpation. The node biopsy reveals anaplastic cells that stain positive for keratin. Which of the following is the most likely origin of the cells detected on the biopsy?

A. Lymphocytes

B. Epithelial surfaces

C. Muscle tissue

D. Endothelium

E. Glial cells

Submit

1
2
3
4
5
6
7
8
9
10
11
12
13
14
15
16
17
18
19
20
21
22
23
24
25
26
27
28
29
30

A 54-year-old male presents with an enlarged left-sided supraclavicular lymph node. The node is painless and stony hard on palpation. The node biopsy reveals anaplastic cells that stain positive for keratin. Which of the following is the most likely origin of the cells detected on the biopsy?

A. Lymphocytes (2%)
✓ B. Epithelial surfaces (88%)
C. Muscle tissue (1%)
D. Endothelium (5%)
E. Glial cells (1%)

Omitted
Correct answer
B

88%
Answered correctly

02 secs
Time Spent

02/21/2020
Last Updated

Explanation

Keratins are a broad group of intermediate filaments present in epithelial cells. Immunohistochemistry stains that employ keratin markers are used by pathologists in the identification of poorly differentiated tumors or tumors with an unclear site of origin. Tumors that stain positive for keratin include carcinomas, mesotheliomas, thymomas, various sarcomas, trophoblastic tumors, and desmoplastic small round cell tumors.

(Choice A) Lymphocytes can be identified immunohistochemically with a special stain for the pan T cell marker CD3, among others.

(Choice C) Muscle tissue can be identified immunohistochemically with special stains for smooth muscle actin, caldesmon, or desmin, among others.

Omitted
Correct answer
B

88%
Answered correctly

02 secs
Time Spent

02/21/2020
Last Updated

Explanation

Keratins are a broad group of intermediate filaments present in epithelial cells. Immunohistochemistry stains that employ keratin markers are used by pathologists in the identification of poorly differentiated tumors or tumors with an unclear site of origin. Tumors that stain positive for keratin include carcinomas, mesotheliomas, thymomas, various sarcomas, trophoblastic tumors, and desmoplastic small round cell tumors.

(Choice A) Lymphocytes can be identified immunohistochemically with a special stain for the pan T cell marker CD3, among others.

(Choice C) Muscle tissue can be identified immunohistochemically with special stains for smooth muscle actin, caldesmon, or desmin, among others.

(Choice D) Endothelium can be identified immunohistochemically with special stains for CD34 and von Willebrand's factor, among others.

(Choice E) Glial cells can be identified immunohistochemically with a special stain for glial fibrillary acidic protein.

Educational Objective:
Keratin is a marker of epithelial cell origin.

Pathology	Hematology & Oncology	Immunohistochemistry
Subject	System	Topic

Copyright © UWorld. All rights reserved.

1
2
3
4
5
6
7
8
9
10
11
12
13
14
15
16
17
18
19
20
21
22
23
24
25
26
27
28
29
30

A 22-year-old woman comes to the emergency department due to a nosebleed. She had a similar episode yesterday, but the bleeding stopped with prolonged local pressure. On review of systems, the patient has also had easy bruising for the past several months. She has no significant past medical history and takes no medications. On physical examination, her heart and lungs appear normal. The liver span is 8 cm and the spleen is not palpable. There are scattered ecchymoses over her arms and legs. Laboratory results are as follows:

Hematocrit	45%
Platelet count	9,000/mm^3
Leukocytes	5,500/mm^3
Neutrophils	60%
Eosinophils	2%
Lymphocytes	32%
Monocytes	6%
Fibrinogen	250 mg/dL (normal: 150-350 mg/dL)
Prothrombin time	13 sec

HIV and hepatitis C tests are negative. Which of the following is the most likely primary mechanism causing this patient's condition?

A. Bone marrow aplasia
B. Bone marrow infiltration by malignant cells
C. Disseminated intravascular coagulation
D. Immune destruction of platelets

1
2
3
4
5
6
7
8
9
10
11
12
13
14
15
16
17
18
19
20
21
22
23
24
25
26
27
28
29
30

Platelet count	9,000/mm^3
Leukocytes	5,500/mm^3
Neutrophils	60%
Eosinophils	2%
Lymphocytes	32%
Monocytes	6%
Fibrinogen	250 mg/dL (normal: 150-350 mg/dL)
Prothrombin time	13 sec

HIV and hepatitis C tests are negative. Which of the following is the most likely primary mechanism causing this patient's condition?

A. Bone marrow aplasia
B. Bone marrow infiltration by malignant cells
C. Disseminated intravascular coagulation
D. Immune destruction of platelets
E. Platelet sequestration
F. von Willebrand disease

Submit

Platelet count	9,000/mm^3
Leukocytes	5,500/mm^3
Neutrophils	60%
Eosinophils	2%
Lymphocytes	32%
Monocytes	6%
Fibrinogen	250 mg/dL (normal: 150-350 mg/dL)
Prothrombin time	13 sec

HIV and hepatitis C tests are negative. Which of the following is the most likely primary mechanism causing this patient's condition?

A. Bone marrow aplasia (1%)
B. Bone marrow infiltration by malignant cells (2%)
C. Disseminated intravascular coagulation (3%)
✓ D. Immune destruction of platelets (71%)
E. Platelet sequestration (6%)
F. von Willebrand disease (14%)

Omitted
Correct answer

71%
Answered correctly

04 secs
Time Spent

05/26/2020
Last Updated

Explanation

This patient has recurrent epistaxis, ecchymoses, and marked thrombocytopenia (normal 150,000-400,000/mm^3). She has a normal hematocrit, leukocyte count and differential, fibrinogen level, and prothrombin time/International Normalized Ratio. She takes no medications, and there is no obvious hepatosplenomegaly on physical examination. Taken together, these findings suggest an isolated acquired thrombocytopenia.

Common causes of acquired thrombocytopenia include increased platelet consumption, sequestration, and/or destruction. In this patient, primary **immune thrombocytopenic purpura (ITP)** is the most likely diagnosis as, other than thrombocytopenia (with associated ecchymosis), her physical examination and laboratory findings are unremarkable. ITP is characterized by the **autoimmune** destruction of platelets by anti-platelet antibodies, likely IgG autoantibodies against the platelet membrane glycoproteins GPIIb/IIIa. In children, ITP is typically acute and self-limited, whereas it tends to run an insidious and chronic course in adults. A peripheral blood smear with **isolated** thrombocytopenia and no other platelet abnormalities would help confirm the diagnosis (megakaryocytes can sometimes be seen). Treatment involves systemic immunosuppression (corticosteroids). Secondary ITP is sometimes associated with HIV or hepatitis C infection.

(Choice A) Bone marrow aplasia would cause pancytopenia. It is unlikely that this patient's thrombocytopenia is due to bone marrow failure as the peripheral counts of the hematopoietic cell lines, other than platelets, are normal. Common causes of aplastic anemia include parvovirus and Epstein-Barr virus infections, high-dose chemotherapy, and radiation.

(Choice B) Malignant infiltration of the bone marrow would be expected to cause pancytopenia and extramedullary hematopoiesis within the liver and spleen, leading to hepatosplenomegaly.

(Choice C) If this patient were experiencing accelerated platelet consumption due to disseminated intravascular coagulation, the plasma fibrinogen level would be decreased and the prothrombin time would be elevated due to clotting factor consumption.

(Choice E) Splenic sequestration of platelets typically occurs in disorders that produce splenomegaly, such as portal hypertension; the platelet count usually remains >30,000/mm^3, and abnormal bleeding generally does not occur. Although platelets can undergo splenic sequestration in ITP, the primary mechanism responsible for the thrombocytopenia is immune destruction.

(Choice F) In von Willebrand disease, platelet function is impaired because von Willebrand factor, which normally facilitates platelet binding to damaged endothelium, is deficient. The platelet count would be normal (unlike in this patient), and the bleeding time and partial thromboplastin time would be prolonged.

whereas it tends to run an insidious and chronic course in adults. A peripheral blood smear with **isolated** thrombocytopenia and no other platelet abnormalities would help confirm the diagnosis (megakaryocytes can sometimes be seen). Treatment involves systemic immunosuppression (corticosteroids). Secondary ITP is sometimes associated with HIV or hepatitis C infection.

(Choice A) Bone marrow aplasia would cause pancytopenia. It is unlikely that this patient's thrombocytopenia is due to bone marrow failure as the peripheral counts of the hematopoietic cell lines, other than platelets, are normal. Common causes of aplastic anemia include parvovirus and Epstein-Barr virus infections, high-dose chemotherapy, and radiation.

(Choice B) Malignant infiltration of the bone marrow would be expected to cause pancytopenia and extramedullary hematopoiesis within the liver and spleen, leading to hepatosplenomegaly.

(Choice C) If this patient were experiencing accelerated platelet consumption due to disseminated intravascular coagulation, the plasma fibrinogen level would be decreased and the prothrombin time would be elevated due to clotting factor consumption.

(Choice E) Splenic sequestration of platelets typically occurs in disorders that produce splenomegaly, such as portal hypertension; the platelet count usually remains >30,000/mm^3, and abnormal bleeding generally does not occur. Although platelets can undergo splenic sequestration in ITP, the primary mechanism responsible for the thrombocytopenia is immune destruction.

(Choice F) In von Willebrand disease, platelet function is impaired because von Willebrand factor, which normally facilitates platelet binding to damaged endothelium, is deficient. The platelet count would be normal (unlike in this patient), and the bleeding time and partial thromboplastin time would be prolonged.

Educational objective:
Autoimmune platelet destruction is a common cause of thrombocytopenia and should be suspected in patients with ecchymoses, petechiae, mucosal bleeding, and no other obvious causes of thrombocytopenia (eg, medications, bone marrow failure).

Pathology	Hematology & Oncology	ITP
Subject	System	Topic

Copyright © UWorld. All rights reserved.

1
2
3
4
5
6
7
8
9
10
11
12
13
14
15
16
17
18
19
20
21
22
23
24
25
26
27
28
29
30

The following vignette applies to the next **2** items. The items in the set must be answered in sequential order. Once you click **Proceed to Next Item**, you will not be able to add or change an answer.

A 23-year-old African American man comes to the emergency department due to back and lower extremity pain for 2 days. He has had several similar episodes over the last 15 years that have required hospitalization. His pain is not responsive to over-the-counter analgesics, and review of his prior records shows that he has needed treatment with opioids for adequate pain relief. The patient does not use tobacco, alcohol, or illicit drugs. On physical examination, he has scleral icterus and tenderness over his lower back and long bones of his thighs. Laboratory evaluation shows a hemoglobin level of 6.7 g/dL.

Item 1 of 2

Histopathologic evaluation of this patient's spleen is most likely to reveal which of the following?

A. Congestion

B. Cyst formation

C. Fibrosis and atrophy

D. Infiltration

E. White pulp hyperplasia

Submit

The following vignette applies to the next **2** items. The items in the set must be answered in sequential order. Once you click **Proceed to Next Item**, you will not be able to add or change an answer.

A 23-year-old African American man comes to the emergency department due to back and lower extremity pain for 2 days. He has had several similar episodes over the last 15 years that have required hospitalization. His pain is not responsive to over-the-counter analgesics, and review of his prior records shows that he has needed treatment with opioids for adequate pain relief. The patient does not use tobacco, alcohol, or illicit drugs. On physical examination, he has scleral icterus and tenderness over his lower back and long bones of his thighs. Laboratory evaluation shows a hemoglobin level of 6.7 g/dL.

Item 1 of 2

Histopathologic evaluation of this patient's spleen is most likely to reveal which of the following?

A. Congestion (27%)

B. Cyst formation (0%)

✓ C. Fibrosis and atrophy (63%)

D. Infiltration (2%)

E. White pulp hyperplasia (6%)

Omitted
Correct answer
C

63%
Answered correctly

02 secs
Time Spent

02/25/2020
Last Updated

Explanation

Explanation

This patient with frequent episodes of bony pain likely has **sickle cell disease** (SCD), an autosomal recessive condition characterized by hemolytic anemia and vaso-occlusion. The hemolytic anemia causes **jaundice** (due to unconjugated hyperbilirubinemia) and promotes formation of pigmented gallstones. Vaso-occlusion by sickled red blood cells occurs in various tissues, causing hypoxia and acidosis (vaso-occlusive pain episodes). Microvascular occlusion nearly always affects the spleen due to the trapping of sickle cells by the rigid splenic cords; autoinfarction begins in early childhood and can precipitate splenic sequestration crisis in infants. However, **repeated infarction** eventually leads to significant scarring, **fibrosis**, and **atrophy** of the spleen, which would likely be present in this **adult patient**.

Asplenic patients are more susceptible to infections with encapsulated bacteria (eg, group B *Streptococcus*, *Haemophilus influenzae*, *Streptococcus pneumoniae*, *Neisseria meningitidis*, *Salmonella typhi*).

(Choice A) Splenic congestion occurs during a splenic sequestration crisis (marked hemoglobin decrease, rapidly enlarging spleen), which develops due to vaso-occlusion within the cords of Billroth and splenic pooling of erythrocytes. However, repeated infarction leads to functional asplenia and autosplenectomy (splenic atrophy) by late childhood/adolescence.

(Choices B and D) Splenic cyst formation typically occurs due to infection. Splenic infiltration can be seen with metastatic neoplasms but is not a feature of SCD.

(Choice E) The white pulp of the spleen is composed of lymphoid tissue. Lymphoid hyperplasia may represent infection or malignancy.

Educational objective:
Sickle cell disease is characterized by repeated splenic infarctions that ultimately result in splenic atrophy and fibrosis, a process that is typically complete by late childhood/adolescence. After autosplenectomy, patients are predisposed to infections with encapsulated bacterial organisms.

Pathology	Hematology & Oncology	Sickle cell
Subject	System	Topic

Copyright © UWorld. All rights reserved.

Item 2 of 2

The patient is admitted to the hospital and receives opioid analgesics and intravenous fluids. He has no evidence of active infection. His hemoglobin electrophoresis results are consistent with sickle cell disease (hemoglobin SS). Further laboratory evaluation shows a mean corpuscular volume of 113 μm^3 and a reticulocyte index of 1.5, which is low given the patient's severe anemia. Which of the following is the most likely cause of this patient's macrocytosis?

A. Extramedullary erythropoiesis

B. Increased folic acid requirement

C. Iron overload

D. Liver disease

E. Myelodysplastic syndrome

Submit

Item 2 of 2

The patient is admitted to the hospital and receives opioid analgesics and intravenous fluids. He has no evidence of active infection. His hemoglobin electrophoresis results are consistent with sickle cell disease (hemoglobin SS). Further laboratory evaluation shows a mean corpuscular volume of 113 μm^3 and a reticulocyte index of 1.5, which is low given the patient's severe anemia. Which of the following is the most likely cause of this patient's macrocytosis?

- A. Extramedullary erythropoiesis (30%)
- ✓ B. Increased folic acid requirement (54%)
- C. Iron overload (2%)
- D. Liver disease (5%)
- E. Myelodysplastic syndrome (7%)

Omitted
Correct answer
B

54%
Answered correctly

03 secs
Time Spent

02/25/2020
Last Updated

Explanation

This patient has **macrocytic** anemia (mean corpuscular volume [MCV] >100 μm^3). Severe macrocytosis (**MCV >110 μm^3**) is usually due to **megaloblastic anemia**, a subtype of macrocytic anemia caused by impaired DNA synthesis. Cytoplasmic components then accumulate within the slowly dividing erythrocytes, producing cells that are larger than normal (macrocytes).

Patients with **sickle cell disease** (SCD) or other hemolytic anemias have **increased folic acid requirements** due to increased erythrocyte

Explanation

This patient has **macrocytic** anemia (mean corpuscular volume [MCV] >100 μm³). Severe macrocytosis (**MCV >110 μm³**) is usually due to **megaloblastic anemia**, a subtype of macrocytic anemia caused by impaired DNA synthesis. Cytoplasmic components then accumulate within the slowly dividing erythrocytes, producing cells that are larger than normal (macrocytes).

Patients with **sickle cell disease** (SCD) or other hemolytic anemias have **increased folic acid requirements** due to increased erythrocyte turnover. As such, they are prone to developing relative folic acid deficiency and megaloblastic anemia.

(Choice A) Extramedullary erythropoiesis can occur in SCD and lead to an elevated reticulocyte count and MCV, as the reticulocytes produced are larger than those released by the bone marrow. However, this patient's low reticulocyte index (representing the reticulocyte percentage corrected for the degree of anemia) suggests an inadequate response to anemia and a lack of erythropoiesis.

(Choice C) Patients with SCD may receive multiple transfusions for treatment of severe or symptomatic anemia. Transfusion related iron overload can cause severe liver disease, but would be unlikely to produce an MCV >110 μm³.

(Choice D) Macrocytosis can occur in liver failure due to an increase in circulating phospholipids and cholesterol that adsorb onto erythrocytes, resulting in membrane expansion. However, liver-associated macrocytosis is generally mild (<110 μm³) and this patient does not have any findings to suggest advanced liver disease (eg, ascities/edema, bleeding).

(Choice E) A disease of the elderly, myelodysplastic syndrome can cause macrocytic anemia. In the setting of a young patient with SCD and hemolytic anemia, however, folic acid deficiency is much more likely.

Educational objective:
An MCV >110 μm³ is highly suggestive of megaloblastic anemia, such as that caused by folic acid or vitamin B_{12} deficiency. Patients with chronic hemolytic anemia have increased folic acid requirements due to increased erythrocyte turnover and are predisposed to developing macrocytosis.

Pathology	Hematology & Oncology	Sickle cell
Subject	System	Topic

Copyright © UWorld. All rights reserved.

1
2
3
4
5
6
7
8
9
10
11
12
13
14
15
16
17
18
19
20
21
22
23
24
25
26
27
28
29
30

Certain patients with non-small cell lung cancer develop constitutive tumor kinase activity due to the production of echinoderm microtubule-associated protein-like 4 - anaplastic lymphoma kinase (EML4-ALK), a fusion protein that contributes to carcinogenesis. This is most similar to the molecular pathophysiology of which of the following disorders?

A. Burkitt lymphoma
B. Chronic myelogenous leukemia
C. Follicular lymphoma
D. Li-Fraumeni syndrome
E. Mantle cell lymphoma

Submit

1
2
3
4
5
6
7
8
9
10
11
12
13
14
15
16
17
18
19
20
21
22
23
24
25
26
27
28
29
30

Certain patients with non-small cell lung cancer develop constitutive tumor kinase activity due to the production of echinoderm microtubule-associated protein-like 4 - anaplastic lymphoma kinase (EML4-ALK), a fusion protein that contributes to carcinogenesis. This is most similar to the molecular pathophysiology of which of the following disorders?

A. Burkitt lymphoma (11%)
✓ B. Chronic myelogenous leukemia (66%)
C. Follicular lymphoma (8%)
D. Li-Fraumeni syndrome (8%)
E. Mantle cell lymphoma (5%)

Omitted
Correct answer
B

66%
Answered correctly

02 secs
Time Spent

05/18/2020
Last Updated

Explanation

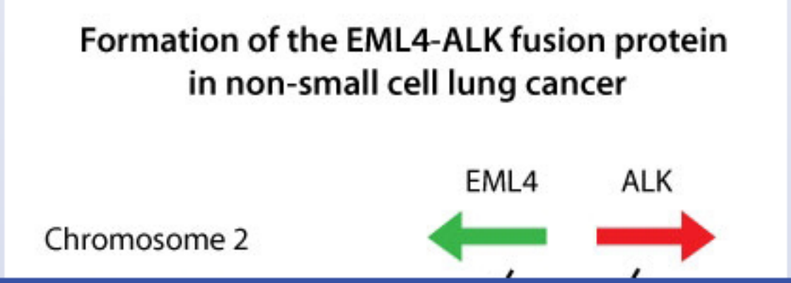

1
2
3
4
5
6
7
8
9
10
11
12
13
14
15
16
17
18
19
20
21
22
23
24
25
26
27
28
29
30

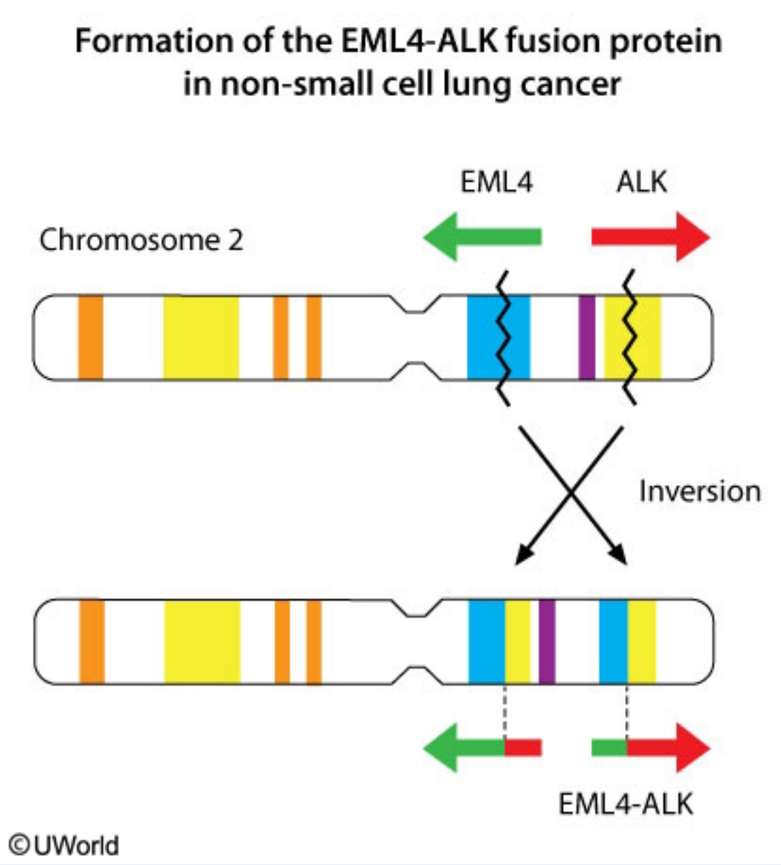

Approximately four percent of patients with non-small cell lung carcinoma (NSCLC) have an inversion of the short arm of chromosome 2 that creates a fusion gene between EML4 (echinoderm microtubule-associated protein-like 4) and ALK (anaplastic lymphoma kinase). This results in a constitutively active tyrosine kinase that causes malignancy. Interestingly, patients who harbor this gene fusion are usually young non-smokers, often with adenocarcinoma, who lack mutations in either the epidermal growth factor receptor gene or the K-ras gene. The kinase activity of this fusion protein is a target of the protein kinase inhibitor, crizotinib.

©UWorld

Approximately four percent of patients with non-small cell lung carcinoma (NSCLC) have an inversion of the short arm of chromosome 2 that creates a fusion gene between EML4 (echinoderm microtubule-associated protein-like 4) and ALK (anaplastic lymphoma kinase). This results in a constitutively active tyrosine kinase that causes malignancy. Interestingly, patients who harbor this gene fusion are usually young non-smokers, often with adenocarcinoma, who lack mutations in either the epidermal growth factor receptor gene or the K-ras gene. The kinase activity of this fusion protein is a target of the protein kinase inhibitor, crizotinib.

The pathophysiology of EML4-ALK NSCLC is most similar to the pathophysiology of chronic myelogenous leukemia (CML). In CML, the classic and most common cause is a translocation between chromosomes 9 and 22. The ABL proto-oncogene is transported from chromosome 9 to chromosome 22 where it is placed adjacent to the BCR gene. The resulting oncogene, BCR-ABL, codes for a fusion protein with constitutive tyrosine kinase activity. This protein stimulates the proliferation of granulocytic precursors and leads to the development of CML. The kinase activity of this fusion protein is a target of the protein kinase inhibitor, imatinib.

(Choice A) Burkitt lymphoma is characterized by a translocation of the c-myc oncogene on the long arm of chromosome 8 to the Ig heavy chain region on chromosome 14. This causes constitutive overproduction of c-myc, a nuclear phosphoprotein that functions as a transcription activator.

(Choice C) Patients with follicular lymphoma have a t(14;18) translocation that causes overexpression of the antiapoptotic BCL2 gene product.

(Choice D) Li-Fraumeni syndrome is an autosomal dominant predisposition to a variety of cancers, particularly sarcomas and tumors of the breast, brain, and adrenal cortex. This syndrome is associated with a mutation of the tumor suppressor gene, p53.

(Choice E) Translocation between the cyclin D1 locus on chromosome 11 and the immunoglobulin heavy chain locus on chromosome 14 is characteristic of mantle cell lymphoma. This abnormality results in increased production of cyclin D1, a promoter of the G1 to S-phase transition during the cell cycle.

Educational objective:
Some patients with non-small cell lung carcinoma (NSCLC) harbor a chromosomal rearrangement that creates a fusion gene between EML4 (echinoderm microtubule-associated protein-like 4) and ALK (anaplastic lymphoma kinase). This results in a constitutive active tyrosine kinase that causes malignancy.

References

1 2 3 4 5 6 7 8 9 10 11 12 13 14 15 16 17 18 19 20 21 22 23 24 25 26 27 28 29 30

The pathophysiology of EML4-ALK NSCLC is most similar to the pathophysiology of chronic myelogenous leukemia (CML). In CML, the classic and most common cause is a translocation between chromosomes 9 and 22. The ABL proto-oncogene is transported from chromosome 9 to chromosome 22 where it is placed adjacent to the BCR gene. The resulting oncogene, BCR-ABL, codes for a fusion protein with constitutive tyrosine kinase activity. This protein stimulates the proliferation of granulocytic precursors and leads to the development of CML. The kinase activity of this fusion protein is a target of the protein kinase inhibitor, imatinib.

(Choice A) Burkitt lymphoma is characterized by a translocation of the c-myc oncogene on the long arm of chromosome 8 to the Ig heavy chain region on chromosome 14. This causes constitutive overproduction of c-myc, a nuclear phosphoprotein that functions as a transcription activator.

(Choice C) Patients with follicular lymphoma have a t(14;18) translocation that causes overexpression of the antiapoptotic BCL2 gene product.

(Choice D) Li-Fraumeni syndrome is an autosomal dominant predisposition to a variety of cancers, particularly sarcomas and tumors of the breast, brain, and adrenal cortex. This syndrome is associated with a mutation of the tumor suppressor gene, p53.

(Choice E) Translocation between the cyclin D1 locus on chromosome 11 and the immunoglobulin heavy chain locus on chromosome 14 is characteristic of mantle cell lymphoma. This abnormality results in increased production of cyclin D1, a promoter of the G1 to S-phase transition during the cell cycle.

Educational objective:
Some patients with non-small cell lung carcinoma (NSCLC) harbor a chromosomal rearrangement that creates a fusion gene between EML4 (echinoderm microtubule-associated protein-like 4) and ALK (anaplastic lymphoma kinase). This results in a constitutive active tyrosine kinase that causes malignancy.

References

- Recurrent EML4-ALK-associated lung adenocarcinoma with a slow clinical course.

Pathology	Hematology & Oncology	Chronic myeloid leukemia
Subject	System	Topic

Copyright © UWorld. All rights reserved.

1
2
3
4
5
6
7
8
9
10
11
12
13
14
15
16
17
18
19
20
21
22
23
24
25
26
27
28
29
30

A 34-year-old obese man presents to your office complaining of fatigue, daytime sleepiness and occasional headaches. When you inquire about his sleeping habits, he reports that he sleeps in a separate room from his wife because she finds his snoring annoying. On physical examination, his blood pressure is 160/90 mmHg and his heart rate is 80/min. His abdomen is soft and non-tender, his liver span is 9 cm, and his spleen is not palpable. Laboratory findings are:

Hematocrit	57%
WBC count	9,000/mm^3
Platelets	190,000/mm^3

Decreased oxygen delivery to which of the following organs is responsible for his increased hematocrit?

A. Brain
B. Liver
C. Spleen
D. Bone marrow
E. Lungs
F. Kidneys

Submit

1 2 3 4 5 6 7 8 9 10 11 12 13 14 15 16 17 18 19 20 21 22 23 24 25 26 27 28 29 30

A 34-year-old obese man presents to your office complaining of fatigue, daytime sleepiness and occasional headaches. When you inquire about his sleeping habits, he reports that he sleeps in a separate room from his wife because she finds his snoring annoying. On physical examination, his blood pressure is 160/90 mmHg and his heart rate is 80/min. His abdomen is soft and non-tender, his liver span is 9 cm, and his spleen is not palpable. Laboratory findings are:

Hematocrit	57%
WBC count	9,000/mm^3
Platelets	190,000/mm^3

Decreased oxygen delivery to which of the following organs is responsible for his increased hematocrit?

A. Brain (9%)
B. Liver (2%)
C. Spleen (2%)
D. Bone marrow (3%)
E. Lungs (7%)
✓ F. Kidneys (74%)

Omitted
Correct answer
F

74%
Answered correctly

02 secs
Time Spent

02/03/2020
Last Updated

Explanation

This patient most likely has obstructive sleep apnea (OSA), a disease characterized by recurrent episodes of asphyxia during sleep, often up to 500 times per night. In patients with OSA, peritubular cells in the renal cortex sense hypoxia and respond by releasing erythropoietin into the bloodstream. (Deficient erythropoietin production is the reason why many patients with chronic kidney disease develop anemia.) Erythropoietin stimulates erythrocyte production by binding to erythropoietin receptors on erythrocyte precursors in the bone marrow. This response is responsible for the secondary polycythemia that occurs in patients with chronic hypoxia secondary to OSA, COPD, right-to-left shunts and high altitude.

(Choice A) Brain doesn't produce erythropoietin.

(Choice B) The liver is the major site of erythropoietin production in the fetus.

(Choice C) The spleen is the major site of destruction of aged or defective erythrocytes. The spleen and liver are potential sites of extramedullary hematopoiesis.

(Choice D) Erythropoietin released by the kidneys circulates to the bone marrow where it stimulates erythroid progenitor cells to synthesize more erythrocytes.

(Choice E) Lung stretch receptors sense distention of the lungs. Stimulation of these receptors decreases the respiratory rate.

Educational Objective:
Renal cortical cells sense hypoxia and respond by synthesizing and releasing erythropoietin. Erythropoietin stimulates the production of erythrocytes in the bone marrow.

Pathology	Hematology & Oncology	Polycythemia
Subject	System	Topic

Copyright © UWorld. All rights reserved.

1
2
3
4
5
6
7
8
9
10
11
12
13
14
15
16
17
18
19
20
21
22
23
24
25
26
27
28
29
30

Platelets	218,000/mm^3
Leukocytes	7500/mm^3
Liver studies	
Total bilirubin	3 mg/dL
Direct bilirubin	0.8 mg/dL
Alkaline phosphatase	95 U/L
Aspartate aminotransferase (AST)	18 U/L
Alanine aminotransferase (ALT)	15 U/L

The patient recovers spontaneously after a few weeks. Peripheral smear of the boy's blood after recovery is shown in the exhibit. Which of the following is the most likely cause of this patient's condition?

A. Glucose-6-phosphate dehydrogenase enzyme deficiency
B. Imbalance between alpha and beta globin chain production
C. Nuclear maturation defect due to defective DNA synthesis
D. Polymerization of hemoglobin within red blood cells
E. Red blood cell membrane cytoskeleton abnormalities

Submit

A 5-year-old boy is brought to the office by his parents who say that he "looks yellow" and has been uncharacteristically tired lately. He has had upper respiratory tract infection symptoms for the past 3 days, including cough, rhinorrhea, sneezing, and sore throat. The parents say that "a lot of kids at daycare have been sick lately." The patient has no prior medical problems. He is consistently at the 50th percentile for height and weight. He takes no medications, and his immunizations are up to date. Pallor, scleral icterus, and palpable splenomegaly are seen on examination. Laboratory results are as follows:

Complete blood count	
Hemoglobin	9 g/dL
Reticulocytes	10.8%
Platelets	218,000/mm^3
Leukocytes	7500/mm^3

Liver studies	
Total bilirubin	3 mg/dL
Direct bilirubin	0.8 mg/dL
Alkaline phosphatase	95 U/L
Aspartate aminotransferase (AST)	18 U/L
Alanine aminotransferase (ALT)	15 U/L

The patient recovers spontaneously after a few weeks. Peripheral smear of the boy's blood after recovery is shown in the exhibit. Which of the following is the most likely cause of this patient's condition?

A. Glucose-6-phosphate dehydrogenase enzyme deficiency

1
2
3
4
5
6
7
8
9
10
11
12
13
14
15
16
17
18
19
20
21
22
23
24
25
26
27
28
29
30

Platelets	218,000/mm^3
Leukocytes	7500/mm^3
Liver studies	
Total bilirubin	3 mg/dL
Direct bilirubin	0.8 mg/dL
Alkaline phosphatase	95 U/L
Aspartate aminotransferase (AST)	18 U/L
Alanine aminotransferase (ALT)	15 U/L

The patient recovers spontaneously after a few weeks. Peripheral smear of the boy's blood after recovery is shown in the exhibit. Which of the following is the most likely cause of this patient's condition?

A. Glucose-6-phosphate dehydrogenase enzyme deficiency
B. Imbalance between alpha and beta globin chain production
C. Nuclear maturation defect due to defective DNA synthesis
D. Polymerization of hemoglobin within red blood cells
E. Red blood cell membrane cytoskeleton abnormalities

Submit

Platelets	218,000/mm^3
Leukocytes	7500/mm^3
Liver studies	
Total bilirubin	3 mg/dL
Direct bilirubin	0.8 mg/dL
Alkaline phosphatase	95 U/L
Aspartate aminotransferase (AST)	18 U/L
Alanine aminotransferase (ALT)	15 U/L

The patient recovers spontaneously after a few weeks. Peripheral smear of the boy's blood after recovery is shown in the exhibit. Which of the following is the most likely cause of this patient's condition?

A. Glucose-6-phosphate dehydrogenase enzyme deficiency (20%)
B. Imbalance between alpha and beta globin chain production (5%)
C. Nuclear maturation defect due to defective DNA synthesis (5%)
D. Polymerization of hemoglobin within red blood cells (5%)
✓ E. Red blood cell membrane cytoskeleton abnormalities (63%)

Omitted
Correct answer
63%
Answered correctly
05 secs
Time Spent
07/07/2020
Last Updated

Hereditary spherocytosis	
Epidemiology	• Autosomal dominant inheritance (~75%) • Northern European descent
Clinical presentation	• Hemolytic anemia • Jaundice • Splenomegaly
Laboratory findings	• ↑ **Mean corpuscular hemoglobin concentration** • **Spherocytes** on peripheral smear • Negative Coombs test • ↑ Osmotic fragility on **acidified glycerol lysis test**
Treatment	• Splenectomy
Complications	• Pigmented gallstones • Aplastic crises from parvovirus B19 infection

©UWorld

This patient's peripheral smear shows spherocytes, which are approximately two-thirds of the diameter of normal RBCs, more densely hemoglobinized at the periphery, and often lack a zone of central pallor. This patient's presentation is consistent with hereditary spherocytosis (HS), an autosomal dominant hemolytic anemia due to a **red blood cell (RBC) membrane defect**. The mutation in HS most often affects the plasma-membrane scaffolding proteins **spectrin** and **ankyrin**. Without this scaffolding, spherocytes are less deformable than normal RBCs and are prone to sequestration and subsequent accelerated **destruction in the spleen**.

Clinical manifestations include **hemolytic anemia, jaundice** (increased RBC destruction results in greater bilirubin production), and **splenomegaly** (spherocytes have difficulty passing through the cords of Billroth and accumulate in the spleen). Infections can trigger hemolysis

©UWorld

This patient's peripheral smear shows spherocytes, which are approximately two-thirds of the diameter of normal RBCs, more densely hemoglobinized at the periphery, and often lack a zone of central pallor. This patient's presentation is consistent with hereditary spherocytosis (HS), an autosomal dominant hemolytic anemia due to a **red blood cell (RBC) membrane defect**. The mutation in HS most often affects the plasma-membrane scaffolding proteins **spectrin** and **ankyrin**. Without this scaffolding, spherocytes are less deformable than normal RBCs and are prone to sequestration and subsequent accelerated **destruction in the spleen**.

Clinical manifestations include **hemolytic anemia, jaundice** (increased RBC destruction results in greater bilirubin production), and **splenomegaly** (spherocytes have difficulty passing through the cords of Billroth and accumulate in the spleen). Infections can trigger hemolysis and lead to an acute hemolytic crisis, as seen in this patient. Age of diagnosis varies considerably, but many patients have jaundice and fatigue in times of increased hemolysis in the setting of viral infections.

(Choice A) Glucose-6-phosphate dehydrogenase (G6PD) enzyme deficiency anemia usually follows oxidative stress. Common triggers include drugs (sulfonamide or antimalarial agents), fava beans, and infections (viral hepatitis, pneumonia, or typhoid). Peripheral smears of G6PD deficiency anemia show bite cells and Heinz bodies, not spherocytes.

(Choice B) An imbalance between alpha globin and beta globin chain production results in thalassemia. In this patient, the peripheral smear has no morphologic variants associated with thalassemia, such as target cells or hypochromic microcytes.

(Choice C) A nuclear maturation defect due to defective DNA synthesis is the pathophysiologic mechanism of megaloblastic anemia, which is most commonly caused by vitamin B_{12} and folic acid deficiencies. In this patient's peripheral smear, small spherocytes are primarily seen and not the enlarged oval cells and hypersegmented neutrophils of megaloblastic anemia.

(Choice D) Polymerization of hemoglobin occurs in sickle cell anemia. A missense mutation in the beta globin chain leads to the production of hemoglobin S, which has the capacity to polymerize in deoxygenated states. This polymerization leads to red blood cell membrane injury and deformation to a "sickle" shape seen on peripheral smear.

Educational objective:
Hereditary spherocytosis results from red cell cytoskeleton abnormalities, most commonly spectrin and ankyrin. Hemolytic anemia, jaundice, and splenomegaly are classic manifestations. Spherocytes are seen on peripheral blood smear.

©UWorld

This patient's peripheral smear shows spherocytes, which are approximately two-thirds of the diameter of normal RBCs, more densely hemoglobinized at the periphery, and often lack a zone of central pallor. This patient's presentation is consistent with hereditary spherocytosis (HS), an autosomal dominant hemolytic anemia due to a **red blood cell (RBC) membrane defect**. The mutation in HS most often affects the plasma-membrane scaffolding proteins **spectrin** and **ankyrin**. Without this scaffolding, spherocytes are less deformable than normal RBCs and are prone to sequestration and subsequent accelerated **destruction in the spleen**.

Clinical manifestations include **hemolytic anemia, jaundice** (increased RBC destruction results in greater bilirubin production), and **splenomegaly** (spherocytes have difficulty passing through the cords of Billroth and accumulate in the spleen). Infections can trigger hemolysis and lead to an acute hemolytic crisis, as seen in this patient. Age of diagnosis varies considerably, but many patients have jaundice and fatigue in times of increased hemolysis in the setting of viral infections.

(Choice A) Glucose-6-phosphate dehydrogenase (G6PD) enzyme deficiency anemia usually follows oxidative stress. Common triggers include drugs (sulfonamide or antimalarial agents), fava beans, and infections (viral hepatitis, pneumonia, or typhoid). Peripheral smears of G6PD deficiency anemia show bite cells and Heinz bodies, not spherocytes.

(Choice B) An imbalance between alpha globin and beta globin chain production results in thalassemia. In this patient, the peripheral smear has no morphologic variants associated with thalassemia, such as target cells or hypochromic microcytes.

(Choice C) A nuclear maturation defect due to defective DNA synthesis is the pathophysiologic mechanism of megal most commonly caused by vitamin B_{12} and folic acid deficiencies. In this patient's peripheral smear, small spherocytes are primarily seen and not the enlarged oval cells and hypersegmented neutrophils of megaloblastic anemia.

Highlight | Add To New Card | Add To Existing Card

(Choice D) Polymerization of hemoglobin occurs in sickle cell anemia. A missense mutation in the beta globin chain leads to the production of hemoglobin S, which has the capacity to polymerize in deoxygenated states. This polymerization leads to red blood cell membrane injury and deformation to a "sickle" shape seen on peripheral smear.

Educational objective:
Hereditary spherocytosis results from red cell cytoskeleton abnormalities, most commonly spectrin and ankyrin. Hemolytic anemia, jaundice, and splenomegaly are classic manifestations. Spherocytes are seen on peripheral blood smear.

©UWorld

Exhibit Display

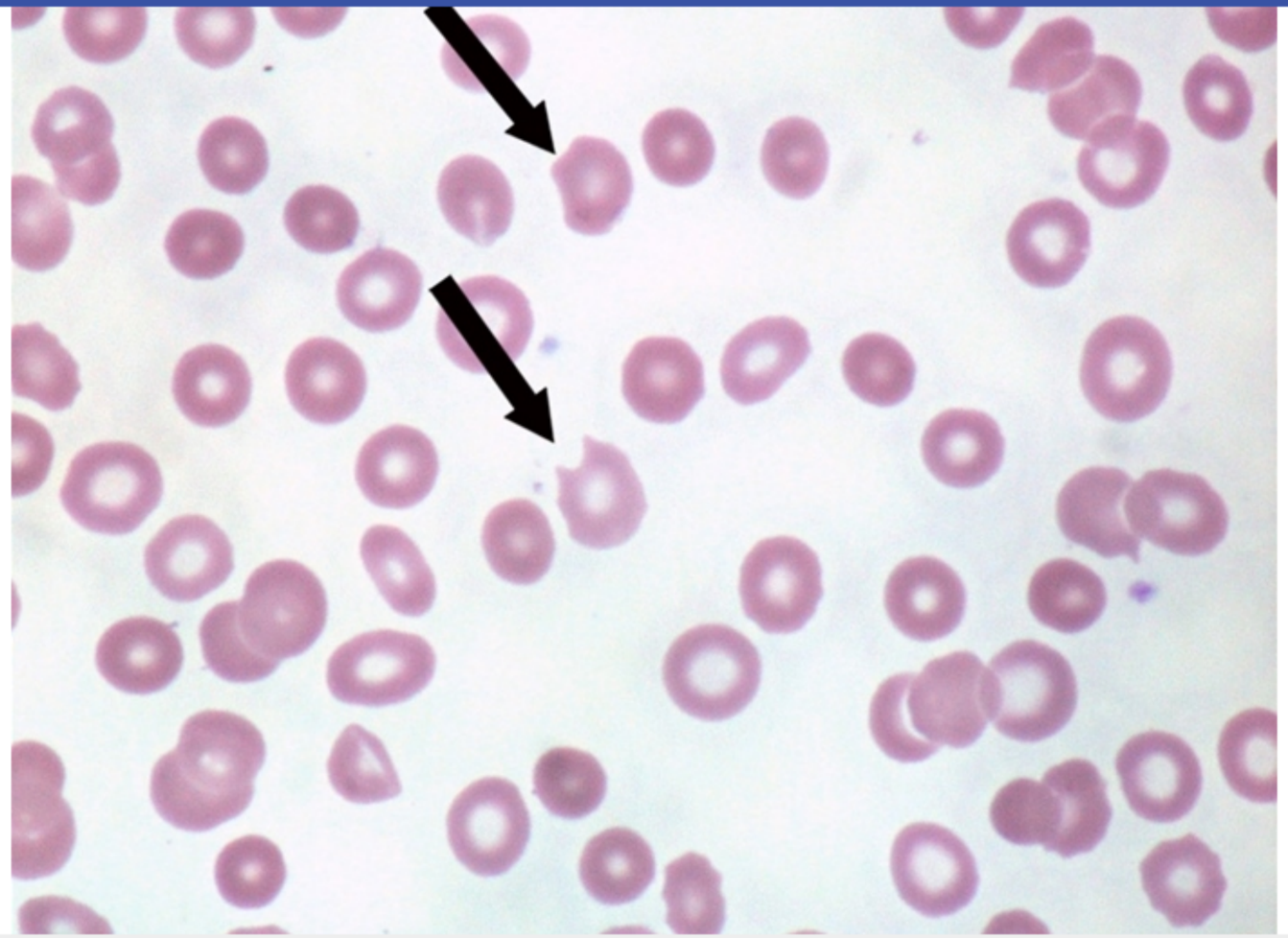

Zoom In | Zoom Out | Reset | Add To New Card | Existing Card

©UWorld

Exhibit Display

Thalassemia

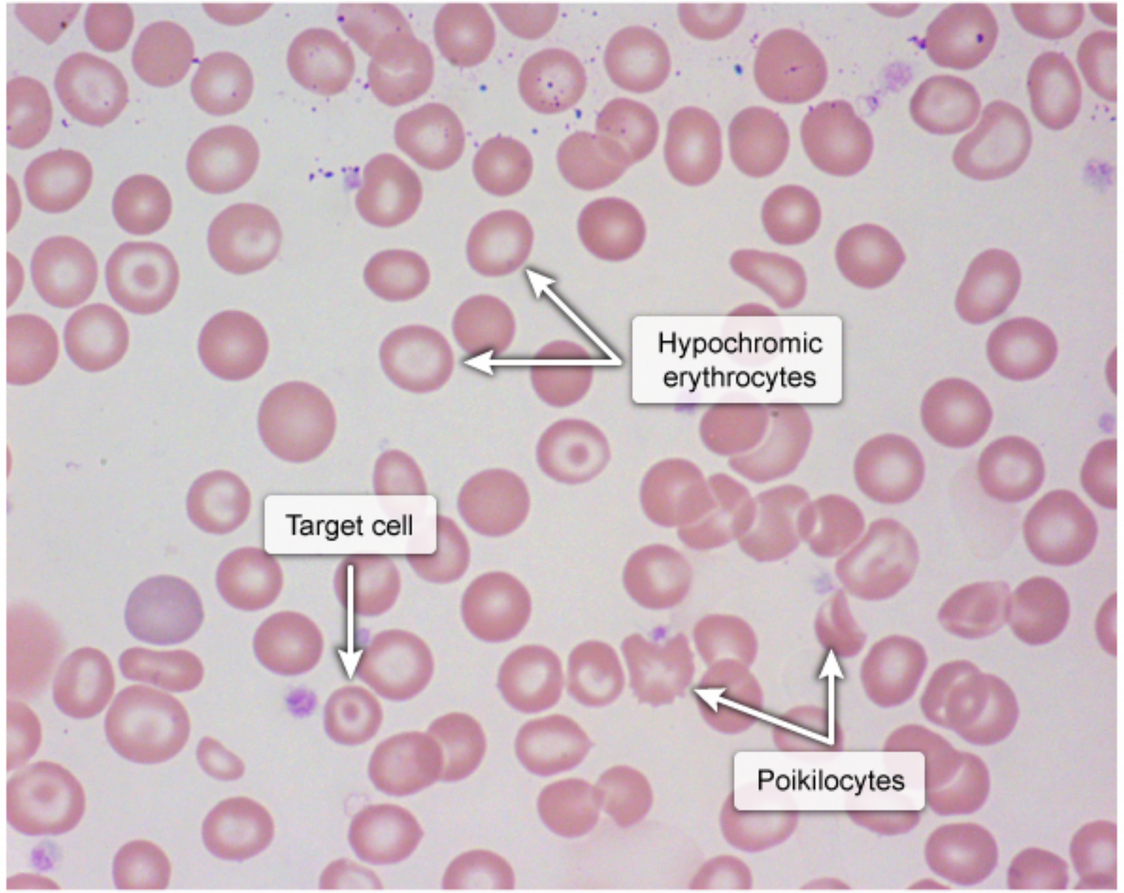

Zoom In | Zoom Out | Reset | Add To New Card | Existing Card

©UWorld

Exhibit Display

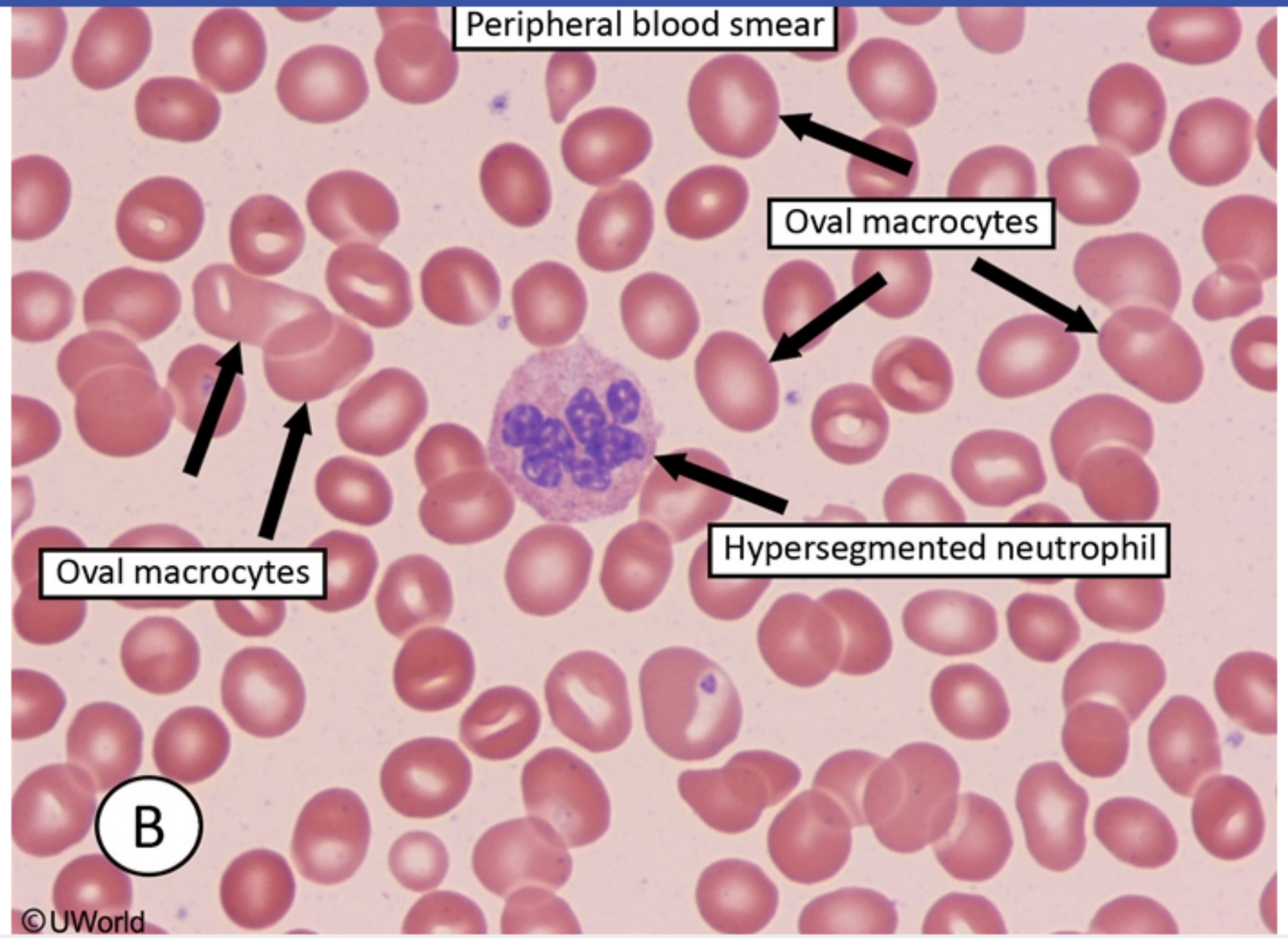

Zoom In | Zoom Out | Reset | Add To New Card | Existing Card

1
2
3
4
5
6
7
8
9
10
11
12
13
14
15
16
17
18
19
20
21
22
23
24
25
26
27
28
29
30

©UWorld

Exhibit Display

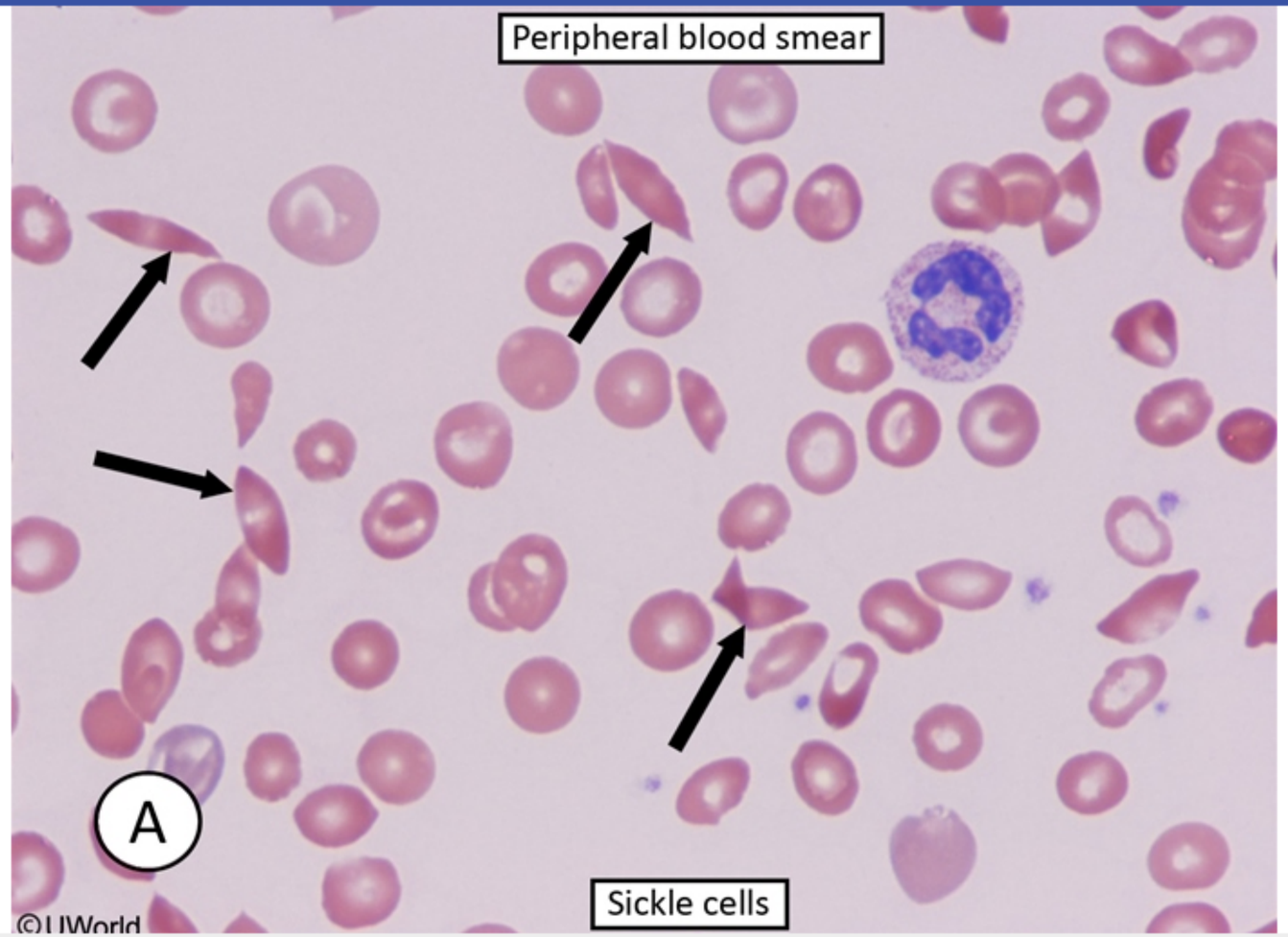

Zoom In | Zoom Out | Reset | Add To New Card | Existing Card

1
2
3
4
5
6
7
8
9
10
11
12
13
14
15
16
17
18
19
20
21
22
23
24
25
26
27
28
29
30

A 40-year-old man with end-stage renal disease due to type 1 diabetes mellitus is hospitalized for initiation of hemodialysis. A tunneled dialysis catheter is inserted into the right internal jugular vein. Before he is able to undergo dialysis treatment, the patient develops bleeding around the catheter exit site that is difficult to control. He has not been treated recently with anticoagulants. Further evaluation of this patient would most likely show which of the following laboratory abnormalities?

	Prothrombin time	Activated partial thromboplastin time	Platelet count	Bleeding Time
A.	Normal	Normal	Normal	Prolonged
B.	Normal	Prolonged	Normal	Prolonged
C.	Normal	Prolonged	Normal	Normal
D.	Prolonged	Prolonged	Decreased	Prolonged
E.	Prolonged	Prolonged	Normal	Normal

Submit

A 40-year-old man with end-stage renal disease due to type 1 diabetes mellitus is hospitalized for initiation of hemodialysis. A tunneled dialysis catheter is inserted into the right internal jugular vein. Before he is able to undergo dialysis treatment, the patient develops bleeding around the catheter exit site that is difficult to control. He has not been treated recently with anticoagulants. Further evaluation of this patient would most likely show which of the following laboratory abnormalities?

	Prothrombin time	Activated partial thromboplastin time	Platelet count	Bleeding Time
✓ A.	Normal (29%)	Normal	Normal	Prolonged
B.	Normal (15%)	Prolonged	Normal	Prolonged
C.	Normal (8%)	Prolonged	Normal	Normal
D.	Prolonged (34%)	Prolonged	Decreased	Prolonged
E.	Prolonged (12%)	Prolonged	Normal	Normal

Omitted
Correct answer
A

29%
Answered correctly

02 secs
Time Spent

05/02/2020
Last Updated

1
2
3
4
5
6
7
8
9
10
11
12
13
14
15
16
17
18
19
20
21
22
23
24
25
26
27
28
29
30

Laboratory characteristics of coagulopathies

	PT	aPTT	Platelet count	Bleeding time
Hemophilia A & B	Normal	↑	Normal	Normal
von Willebrand factor deficiency	Normal	Normal or ↑	Normal	↑
Disseminated intravascular coagulation	↑	↑	↓	↑
Uremic platelet dysfunction	Normal	Normal	Normal	↑
Heparin administration	Normal	↑	Normal (except in heparin-induced thrombocytopenia)	Normal
Warfarin use	↑	↑ (weak effect)	Normal	Normal
Immune thrombocytopenia	Normal	Normal	↓	↑

Heparin administration	Normal	↑	heparin-induced thrombocytopenia)	Normal
Warfarin use	↑	↑ (weak effect)	Normal	Normal
Immune thrombocytopenia	Normal	Normal	↓	↑

aPTT = activated partial thromboplastin time; PT = prothrombin time.

©UWorld

Excessive bleeding is common in patients with significant renal dysfunction due in part to the accumulation of **uremic toxins** in the circulation. These toxins impair platelet aggregation and adhesion, resulting in a **qualitative platelet disorder** characterized by **prolonged bleeding time** with normal platelet count, prothrombin time (PT), and activated partial thromboplastin time (aPTT). Uremic bleeding can be improved with **dialysis** as it removes the toxins and partially reverses the bleeding abnormality.

(Choice B) von Willebrand factor (vWF) acts as a bridge between glycoprotein 1b receptors and subendothelial collagen, allowing platelets to bind to damaged vessels. vWF deficiency results in platelet dysfunction with a prolonged bleeding time and normal platelet count. Since vWF also protects factor VIII from degradation, vWF deficiency can result in decreased factor VIII and prolonged aPTT.

(Choice C) Isolated aPTT prolongation is seen with hemophilia A, an X-linked disorder caused by factor VIII deficiency. Heparin use also prolongs the aPTT via antithrombin-associated inhibition of factors II and X (PT is usually normal due to the addition of heparin neutralizers in the PT reagent).

(Choice D) Disseminated intravascular coagulation is a consumptive coagulopathy associated with decreased platelet count and increased bleeding time, aPTT, and PT.

(Choice E) Warfarin inhibits vitamin K-dependent clotting factors (II, VII, IX, and X). Warfarin prolongs both PT and aPTT, but PT is increased much more than aPTT. Platelet count and bleeding time are normal.

Education objective:

Excessive bleeding is common in patients with significant renal dysfunction due in part to the accumulation of **uremic toxins** in the circulation. These toxins impair platelet aggregation and adhesion, resulting in a **qualitative platelet disorder** characterized by **prolonged bleeding time** with normal platelet count, prothrombin time (PT), and activated partial thromboplastin time (aPTT). Uremic bleeding can be improved with **dialysis** as it removes the toxins and partially reverses the bleeding abnormality.

(Choice B) von Willebrand factor (vWF) acts as a bridge between glycoprotein 1b receptors and subendothelial collagen, allowing platelets to bind to damaged vessels. vWF deficiency results in platelet dysfunction with a prolonged bleeding time and normal platelet count. Since vWF also protects factor VIII from degradation, vWF deficiency can result in decreased factor VIII and prolonged aPTT.

(Choice C) Isolated aPTT prolongation is seen with hemophilia A, an X-linked disorder caused by factor VIII deficiency. Heparin use also prolongs the aPTT via antithrombin-associated inhibition of factors II and X (PT is usually normal due to the addition of heparin neutralizers in the PT reagent).

(Choice D) Disseminated intravascular coagulation is a consumptive coagulopathy associated with decreased platelet count and increased bleeding time, aPTT, and PT.

(Choice E) Warfarin inhibits vitamin K-dependent clotting factors (II, VII, IX, and X). Warfarin prolongs both PT and aPTT, but PT is increased much more than aPTT. Platelet count and bleeding time are normal.

Education objective:
Abnormal bleeding in patients with uremia is due to a qualitative platelet disorder that causes prolonged bleeding time with normal platelet count, prothrombin time, and activated partial thromboplastin time.

References

- Coagulation assays and anticoagulant monitoring.

Pathology	Hematology & Oncology	Coagulopathy
Subject	System	Topic

Copyright © UWorld. All rights reserved.

1 2 3 4 5 6 7 8 9 10 11 12 13 14 15 16 17 18 19 20 21 22 23 24 25 26 27 28 29 30

A 36-year-old woman comes to the office due to 2 weeks of fatigue and easy bruising. She also had an upper respiratory tract infection recently. Physical examination shows no lymphadenopathy and no hepatosplenomegaly. Laboratory studies are as follows:

Hemoglobin	7.0 g/dL
Erythrocytes	1.8 million/mm^3
Mean corpuscular volume	90 μm^3
Reticulocytes	0.1%
Platelets	88,000/mm^3
Leukocytes	2,500/mm^3
Prothrombin time	13 seconds
Partial thromboplastin time	30 seconds

A peripheral blood smear shows normocytic, normochromic red blood cells. The other cell types are also morphologically normal. Bone marrow biopsy in this patient would most likely show which of the following patterns?

A. Hypercellular marrow filled with numerous blast forms
B. Hypercellular marrow with megaloblastic hematopoiesis
C. Hypergranular promyelocytes with multiple Auer rods
D. Hypocellular marrow filled with fat cells and marrow stroma

Submit

A 36-year-old woman comes to the office due to 2 weeks of fatigue and easy bruising. She also had an upper respiratory tract infection recently. Physical examination shows no lymphadenopathy and no hepatosplenomegaly. Laboratory studies are as follows:

Hemoglobin	7.0 g/dL
Erythrocytes	1.8 million/mm^3
Mean corpuscular volume	90 μm^3
Reticulocytes	0.1%
Platelets	88,000/mm^3
Leukocytes	2,500/mm^3
Prothrombin time	13 seconds
Partial thromboplastin time	30 seconds

A peripheral blood smear shows normocytic, normochromic red blood cells. The other cell types are also morphologically normal. Bone marrow biopsy in this patient would most likely show which of the following patterns?

A. Hypercellular marrow filled with numerous blast forms (9%)

B. Hypercellular marrow with megaloblastic hematopoiesis (5%)

C. Hypergranular promyelocytes with multiple Auer rods (6%)

✓ D. Hypocellular marrow filled with fat cells and marrow stroma (79%)

Omitted

Explanation

Aplastic anemia	
Pathogenesis	Bone marrow failure due to hematopoietic stem cell deficiency ($CD34^+$)
Causes	• Autoimmune • Infections (eg, parvovirus B19, Epstein-Barr virus) • Drugs (eg, carbamazepine, chloramphenicol, sulfonamides) • Exposure to radiation or toxins (eg, benzene, solvents)
Clinical & laboratory findings	Laboratory studies: Pancytopenia • Anemia (fatigue, weakness, pallor) • Thrombocytopenia (mucosal bleeding, easy bruising, petechiae) • Leukopenia (recurrent infections) Biopsy: Hypocellular bone marrow with fat and stromal cells

This patient has anemia (manifesting as fatigue), thrombocytopenia (easy bruising), and neutropenia (recent respiratory infection), with profound reticulocytopenia, morphologically normal cell lines on peripheral smear, and no splenomegaly on physical examination. This presentation is most consistent with **aplastic anemia**, which in actuality presents as **pancytopenia** (not simply anemia) that is characteristically **without splenomegaly**. Bone marrow examination reveals **marked hypocellularity** with the hematopoietic elements replaced by fat cells and marrow stroma; aspiration typically produces a "dry tap." The absence of splenomegaly is key in diagnosing aplastic anemia; a patient with pancytopenia and splenomegaly is very unlikely to have aplastic anemia.

Other causes of pancytopenia without splenomegaly include severe vitamin B_{12} and folic acid deficiency anemia, acute leukemias, and certain forms of myelodysplastic syndrome (MDS). Bone marrow examination can be extremely helpful in distinguishing among these conditions.

(Choice A) Hypercellular marrow with increased blasts can be found in myeloproliferative disorders such as primary myelofibrosis (would present with splenomegaly and fatigue) or chronic myelogenous leukemia (would present with leukocytosis), MDS (would present in older patients), and certain leukemias (eg, acute myeloid leukemia [AML] - blasts would be seen on peripheral smear).

	Biopsy: Hypocellular bone marrow with fat and stromal cells

This patient has anemia (manifesting as fatigue), thrombocytopenia (easy bruising), and neutropenia (recent respiratory infection), with profound reticulocytopenia, morphologically normal cell lines on peripheral smear, and no splenomegaly on physical examination. This presentation is most consistent with **aplastic anemia**, which in actuality presents as **pancytopenia** (not simply anemia) that is characteristically **without splenomegaly**. Bone marrow examination reveals **marked hypocellularity** with the hematopoietic elements replaced by fat cells and marrow stroma; aspiration typically produces a "dry tap." The absence of splenomegaly is key in diagnosing aplastic anemia; a patient with pancytopenia and splenomegaly is very unlikely to have aplastic anemia.

Other causes of pancytopenia without splenomegaly include severe vitamin B_{12} and folic acid deficiency anemia, acute leukemias, and certain forms of myelodysplastic syndrome (MDS). Bone marrow examination can be extremely helpful in distinguishing among these conditions.

(Choice A) Hypercellular marrow with increased blasts can be found in myeloproliferative disorders such as primary myelofibrosis (would present with splenomegaly and fatigue) or chronic myelogenous leukemia (would present with leukocytosis), MDS (would present in older patients), and certain leukemias (eg, acute myeloid leukemia [AML] - blasts would be seen on peripheral smear).

(Choice B) Hypercellular marrow with megaloblastic hematopoiesis can be seen in MDS or megaloblastic anemia. However, MDS typically occurs in elderly patients (median age ~65) and has a male predominance. Patients with severe megaloblastic anemia usually have macrocytosis rather than normocytosis.

(Choice C) Acute promyelocytic (FAB M3) leukemia is characterized by the presence of promyelocytes with Auer rods (rod-shaped cytoplasmic inclusions). The cell cytoplasm also has numerous coarse azurophilic granules. This type of AML is characterized clinically by disseminated intravascular coagulation (acquired hypercoagulability and bleeding), which is not seen in this patient (given her normal prothrombin time and partial thromboplastin time); immature white blood cell forms would also be present on peripheral smear.

Educational objective:
Aplastic anemia causes pancytopenia as the bone marrow is replaced by fat cells and marrow stroma. The absence of splenomegaly on physical examination is characteristic. A bone marrow biopsy can be extremely useful in making the diagnosis.

Pathology Hematology & Oncology Aplastic anemia

Biopsy: Hypocellular bone marrow with fat and stromal cells

Exhibit Display

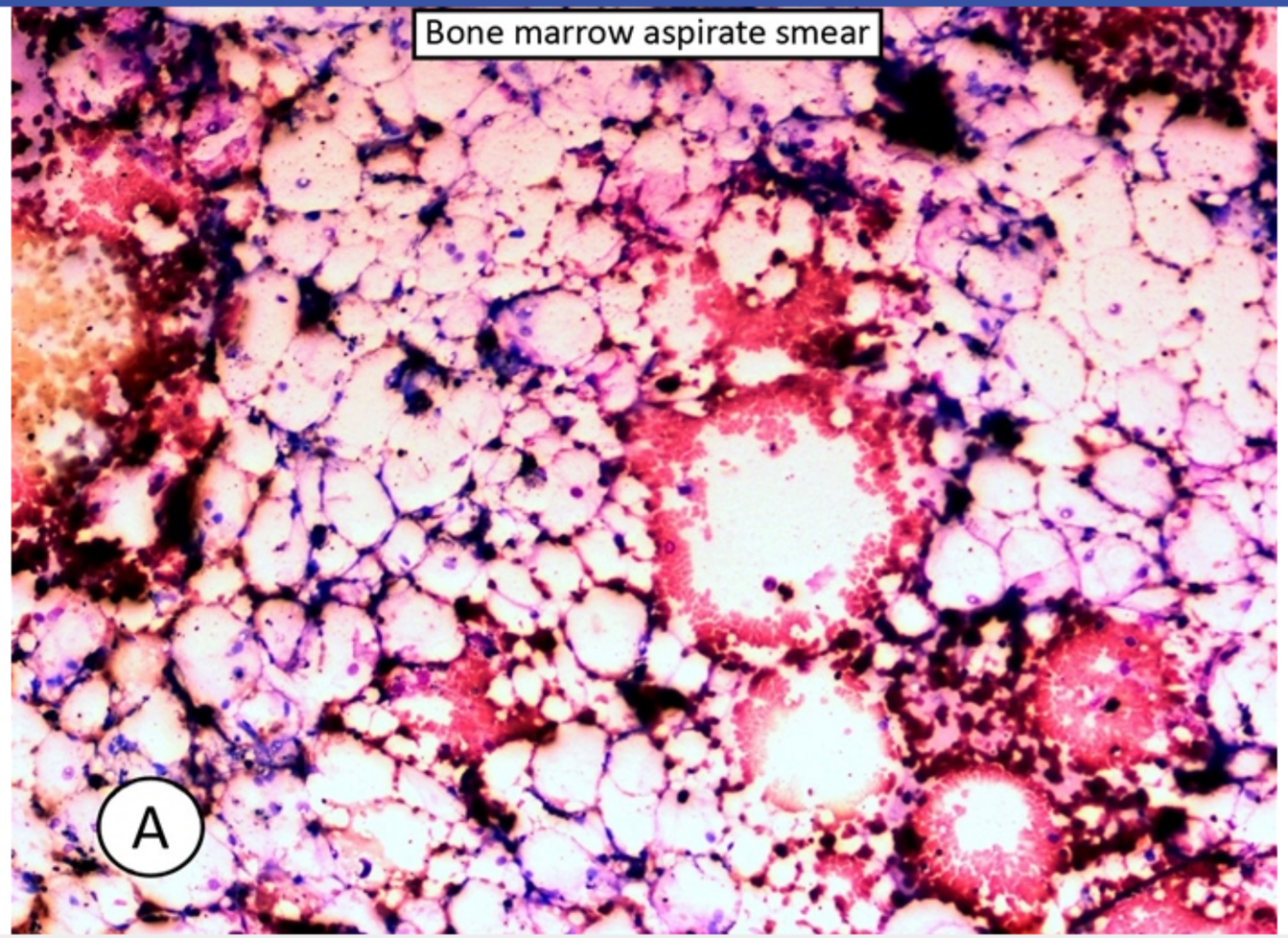

Zoom In | Zoom Out | Reset | Add To New Card | Existing Card

1
2
3
4
5
6
7
8
9
10
11
12
13
14
15
16
17
18
19
20
21
22
23
24
25
26
27
28
29
30

This patient has anemia (manifesting as fatigue), thrombocytopenia (easy bruising), and neutropenia (recent respiratory infection), with profound reticulocytopenia, morphologically normal cell lines on peripheral smear, and no splenomegaly on physical examination. This presentation is most consistent with **aplastic anemia**, which in actuality presents as **pancytopenia** (not simply anemia) that is characteristically **without splenomegaly**. Bone marrow examination reveals **marked hypocellularity** with the hematopoietic elements replaced by fat cells and marrow stroma; aspiration typically produces a "dry tap." The absence of splenomegaly is key in diagnosing aplastic anemia; a patient with pancytopenia and splenomegaly is very unlikely to have aplastic anemia.

Other causes of pancytopenia without splenomegaly include severe vitamin B_{12} and folic acid deficiency anemia, acute leukemias, and certain forms of myelodysplastic syndrome (MDS). Bone marrow examination can be extremely helpful in distinguishing among these conditions.

(Choice A) Hypercellular marrow with increased blasts can be found in myeloproliferative disorders such as primary myelofibrosis (would present with splenomegaly and fatigue) or chronic myelogenous leukemia (would present with leukocytosis), MDS (would present in older patients), and certain leukemias (eg, acute myeloid leukemia [AML] - blasts would be seen on peripheral smear).

(Choice B) Hypercellular marrow with megaloblastic hematopoiesis can be seen in MDS or megaloblastic anemia. However, MDS typically occurs in elderly patients (median age ~65) and has a male predominance. Patients with severe megaloblastic anemia usually have macrocytosis rather than normocytosis.

(Choice C) Acute promyelocytic (FAB M3) leukemia is characterized by the presence of promyelocytes with Auer rods (rod-shaped cytoplasmic inclusions). The cell cytoplasm also has numerous coarse azurophilic granules. This type of AML is characterized clinically by disseminated intravascular coagulation (acquired hypercoagulability and bleeding), which is not seen in this patient (given her normal prothrombin time and partial thromboplastin time); immature white blood cell forms would also be present on peripheral smear.

Educational objective:
Aplastic anemia causes pancytopenia as the bone marrow is replaced by fat cells and marrow stroma. The absence of splenomegaly on physical examination is characteristic. A bone marrow biopsy can be extremely useful in making the diagnosis.

Pathology	Hematology & Oncology	Aplastic anemia
Subject	System	Topic

Copyright © UWorld. All rights reserved.

1
2
3
4
5
6
7
8
9
10
11
12
13
14
15
16
17
18
19
20
21
22
23
24
25
26
27
28
29
30

A 7-year-old boy is brought to the office due to fatigue, easy bruising, and frequent epistaxis for 2 weeks. He has no medical problems and takes no medications. His temperature is 36.7 C (98 F), blood pressure is 90/60 mm Hg, pulse is 94/min, and respirations are 18/min. Physical examination reveals pallor and multiple ecchymoses. There is no lymphadenopathy or hepatosplenomegaly. Laboratory results are as follows:

Hemoglobin	8.2 g/L
Platelets	40,000/mm^3
Leukocytes	2,100/mm^3

A bone marrow biopsy is shown in the image below. Which of the following is the most likely diagnosis?

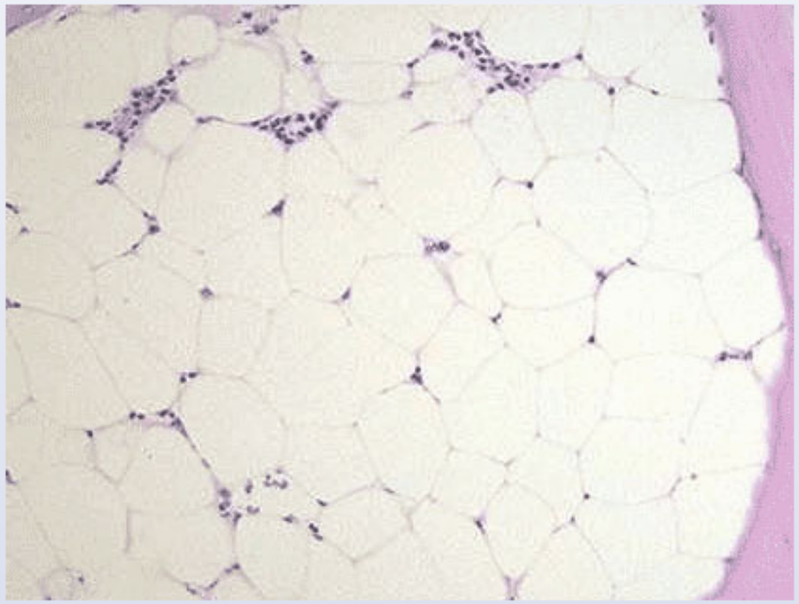

A. Acute lymphoblastic leukemia

A bone marrow biopsy is shown in the image below. Which of the following is the most likely diagnosis?

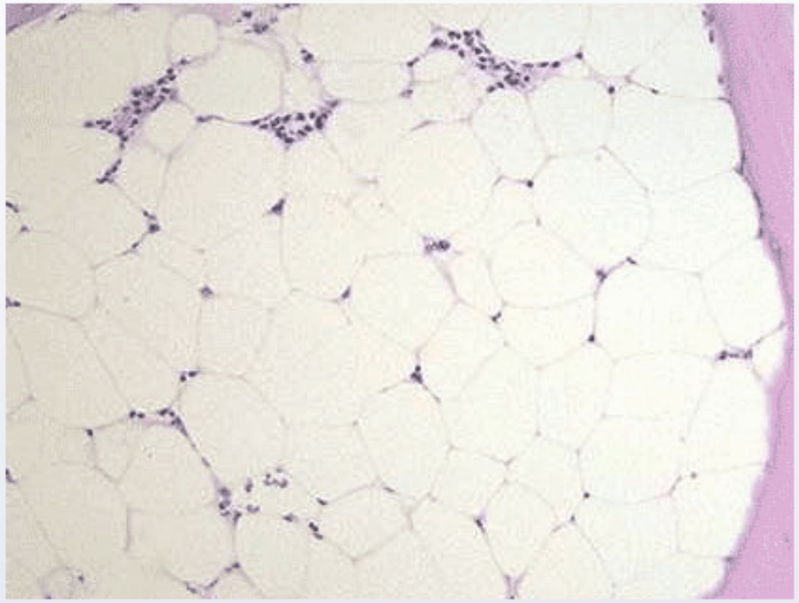

A. Acute lymphoblastic leukemia

B. Fanconi anemia

C. Idiopathic aplastic anemia

D. Myelodysplastic syndrome

E. Parvovirus B19 infection

Submit

1
2
3
4
5
6
7
8
9
10
11
12
13
14
15
16
17
18
19
20
21
22
23
24
25
26
27
28
29
30

A bone marrow biopsy is shown in the image below. Which of the following is the most likely diagnosis?

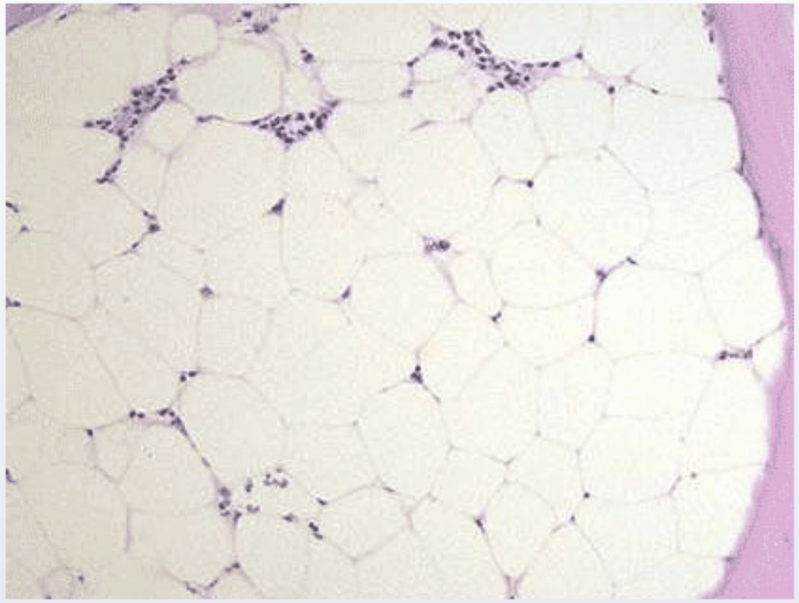

A. Acute lymphoblastic leukemia (3%)

B. Fanconi anemia (6%)

✓ C. Idiopathic aplastic anemia (61%)

D. Myelodysplastic syndrome (11%)

E. Parvovirus B19 infection (15%)

Omitted
Correct answer

61%
Answered correctly

03 secs
Time Spent

03/01/2020
Last Updated

1
2
3
4
5
6
7
8
9
10
11
12
13
14
15
16
17
18
19
20
21
22
23
24
25
26
27
28
29
30

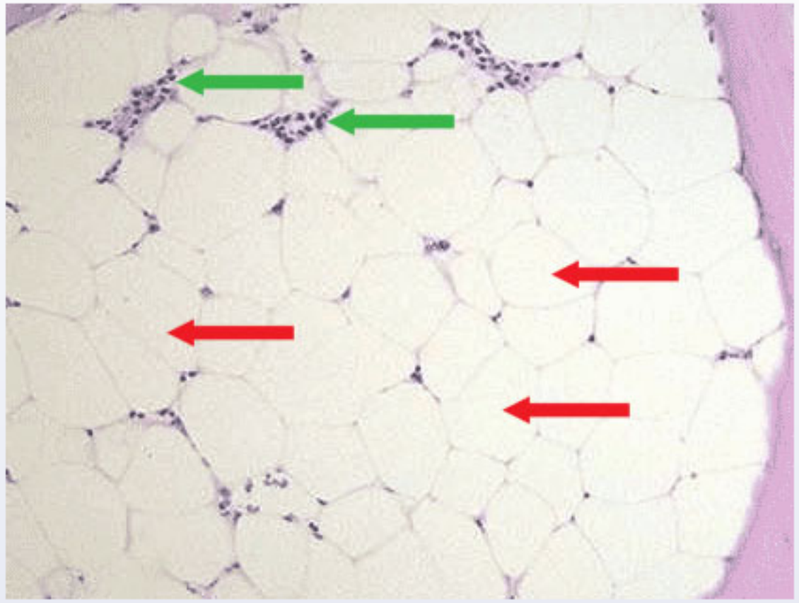

Aplastic anemia (AA) is defined by **pancytopenia** with **bone marrow hypocellularity**. Bone marrow biopsy, shown in the image above, reveals an abundance of fat cells (red arrows) and scattered clusters of morphologically normal white blood cells (green arrows). This hypocellularity contrasts with healthy bone marrow, which has an approximate 1:1 ratio of fat to hematopoietic elements.

Most cases of AA are **acquired** from a direct toxic insult or T-cell response leading to apoptosis of pluripotent stem cells. The etiology is unknown in most children, but the damage may result from drug exposures (eg, chemotherapy, benzene [gasoline, tobacco smoke], carbamazepine [anti-epileptic]) and viral infections (eg, hepatitis, Epstein-Barr virus).

AA presents with progressive signs and symptoms of pancytopenia, such as bleeding from thrombocytopenia, pallor and fatigue from anemia, and bacterial infections from leukopenia/neutropenia. Splenomegaly is notably absent due to a lack of available hematopoietic progenitor cells and, therefore, a lack of extramedullary hematopoiesis.

(Choice A) Acute lymphoblastic leukemia is the most common childhood malignancy. It can present with lymphadenopathy and hepatosplenomegaly due to leukemic cell infiltration as well as anemia, thrombocytopenia, and leukopenia/leukocytosis. Hypercellularity and

Aplastic anemia (AA) is defined by **pancytopenia** with **bone marrow hypocellularity**. Bone marrow biopsy, shown in the image above, reveals an abundance of fat cells (red arrows) and scattered clusters of morphologically normal white blood cells (green arrows). This hypocellularity contrasts with healthy bone marrow, which has an approximate 1:1 ratio of fat to hematopoietic elements.

Most cases of AA are **acquired** from a direct toxic insult or T-cell response leading to apoptosis of pluripotent stem cells. The etiology is unknown in most children, but the damage may result from drug exposures (eg, chemotherapy, benzene [gasoline, tobacco smoke], carbamazepine [anti-epileptic]) and viral infections (eg, hepatitis, Epstein-Barr virus).

AA presents with progressive signs and symptoms of pancytopenia, such as bleeding from thrombocytopenia, pallor and fatigue from anemia, and bacterial infections from leukopenia/neutropenia. Splenomegaly is notably absent due to a lack of available hematopoietic progenitor cells and, therefore, a lack of extramedullary hematopoiesis.

(Choice A) Acute lymphoblastic leukemia is the most common childhood malignancy. It can present with lymphadenopathy and hepatosplenomegaly due to leukemic cell infiltration as well as anemia, thrombocytopenia, and leukopenia/leukocytosis. Hypercellularity and lymphoblasts (immature lymphocytes [black arrows]) are noted on bone marrow aspirate.

(Choice B) Fanconi anemia is an inherited cause of AA that presents with short stature and absent thumbs and is associated with an increased risk of malignancy (eg, myelodysplastic syndrome, acute myeloid leukemia).

(Choice D) Myelodysplastic syndrome (MDS) is caused by a defect in stem cell maturation leading to ineffective differentiation of cell lines and, therefore, pancytopenia. Bone marrow biopsy will be hypercellular with abnormally differentiated cells (eg, misshapen nuclei). MDS primarily occurs in patients age ≥65.

(Choice E) Parvovirus B19 infects erythrocyte precursors and can cause an aplastic crisis (red cell aplasia only) in patients with preexisting hematologic disease (eg, sickle cell anemia, hereditary spherocytosis). Leukopenia and thrombocytopenia can also be found in immunocompromised patients.

Educational objective:
Aplastic anemia is most commonly due to a toxic effect or autoimmune response causing apoptosis of pluripotent stem cells (pancytopenia). Bone marrow biopsy reveals hypocellularity with an abundance of fat cells.

1
2
3
4
5
6
7
8
9
10
11
12
13
14
15
16
17
18
19
20
21
22
23
24
25
26
27
28
29
30

Exhibit Display

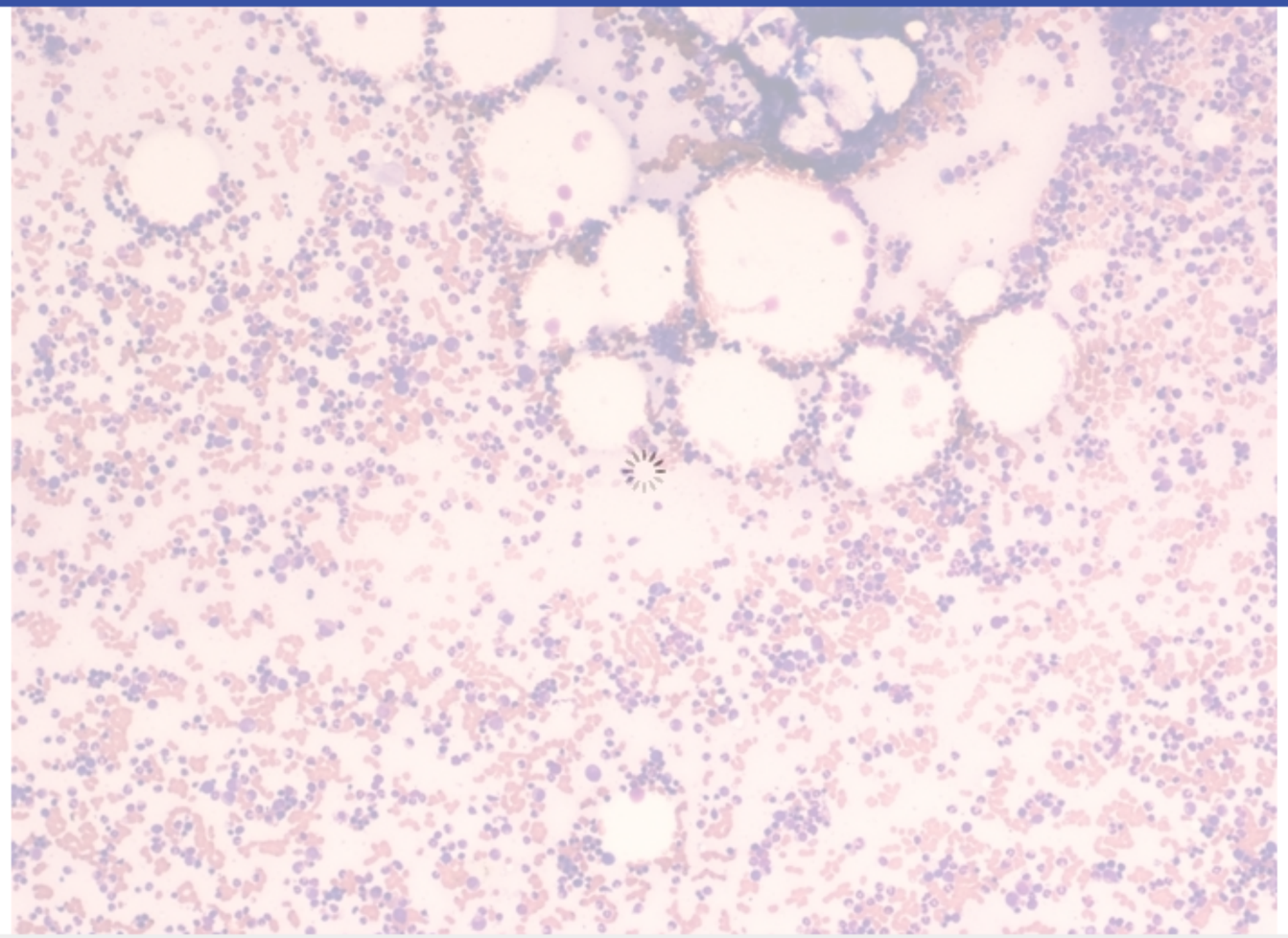

Zoom In | Zoom Out | Reset | Add To New Card | Existing Card

AA presents with progressive signs and symptoms of pancytopenia, such as bleeding from thrombocytopenia, pallor and fatigue from anemia, and bacterial infections from leukopenia/neutropenia. Splenomegaly is notably absent due to a lack of available hematopoietic progenitor cells and, therefore, a lack of extramedullary hematopoiesis.

(Choice A) Acute lymphoblastic leukemia is the most common childhood malignancy. It can present with lymphadenopathy and hepatosplenomegaly due to leukemic cell infiltration as well as anemia, thrombocytopenia, and leukopenia/leukocytosis. Hypercellularity and lymphoblasts (immature lymphocytes [black arrows]) are noted on bone marrow aspirate.

(Choice B) Fanconi anemia is an inherited cause of AA that presents with short stature and absent thumbs and is associated with an increased risk of malignancy (eg, myelodysplastic syndrome, acute myeloid leukemia).

(Choice D) Myelodysplastic syndrome (MDS) is caused by a defect in stem cell maturation leading to ineffective differentiation of cell lines and, therefore, pancytopenia. Bone marrow biopsy will be hypercellular with abnormally differentiated cells (eg, misshapen nuclei). MDS primarily occurs in patients age ≥65.

(Choice E) Parvovirus B19 infects erythrocyte precursors and can cause an aplastic crisis (red cell aplasia only) in patients with preexisting hematologic disease (eg, sickle cell anemia, hereditary spherocytosis). Leukopenia and thrombocytopenia can also be found in immunocompromised patients.

Educational objective:
Aplastic anemia is most commonly due to a toxic effect or autoimmune response causing apoptosis of pluripotent stem cells (pancytopenia). Bone marrow biopsy reveals hypocellularity with an abundance of fat cells.

References

- Idiopathic aplastic anemia: diagnosis and classification.

Pathology	Hematology & Oncology	Aplastic anemia
Subject	System	Topic

Copyright © UWorld. All rights reserved.

1
2
3
4
5
6
7
8
9
10
11
12
13
14
15
16
17
18
19
20
21
22
23
24
25
26
27
28
29
30

AA presents with progressive signs and symptoms of pancytopenia, such as bleeding from thrombocytopenia, pallor and fatigue from anemia, and

Exhibit Display

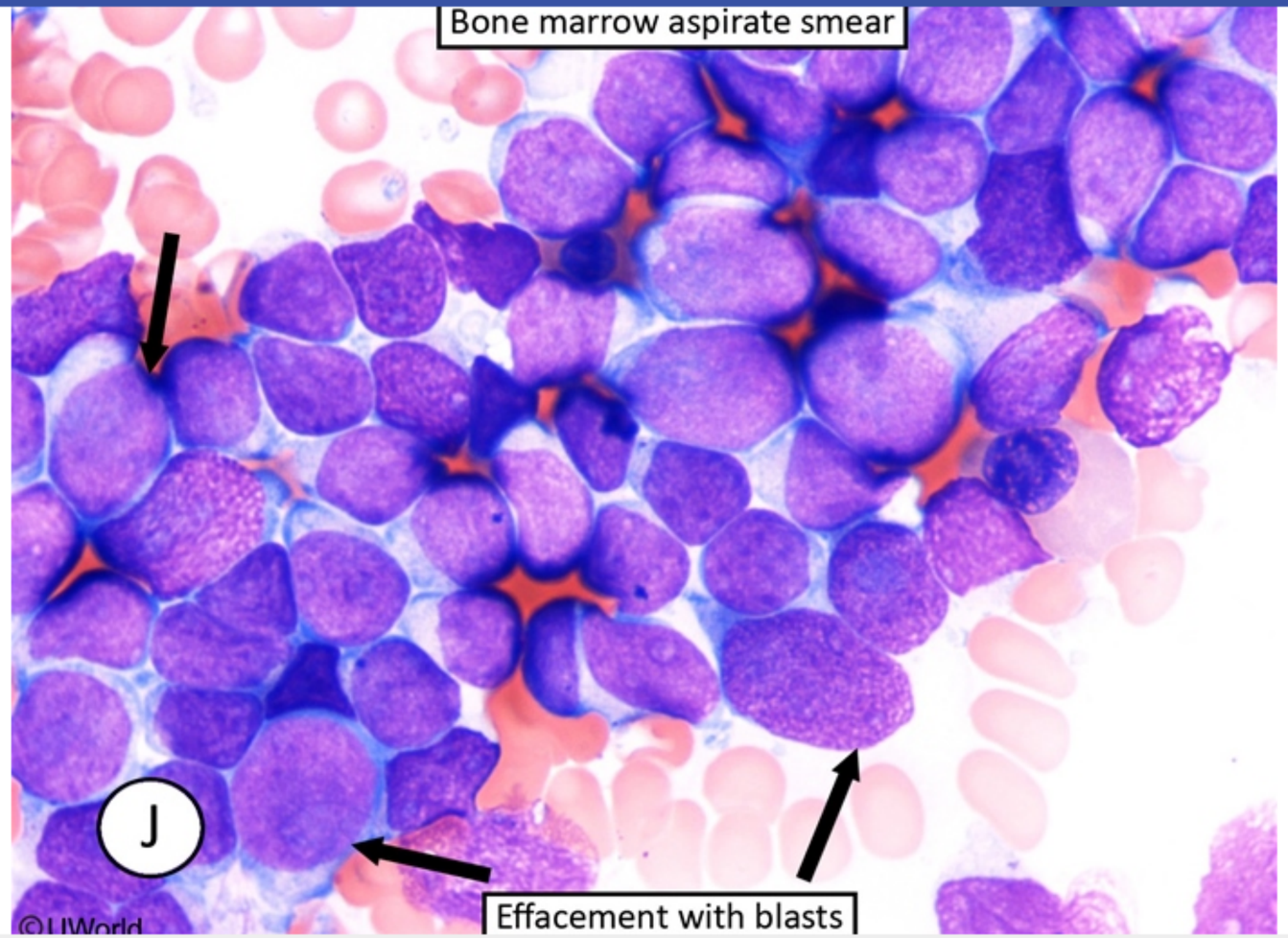

Zoom In | Zoom Out | Reset | Add To New Card | Existing Card

1
2
3
4
5
6
7
8
9
10
11
12
13
14
15
16
17
18
19
20
21
22
23
24
25
26
27
28
29
30

A 6-year-old boy is brought to the emergency department due to bleeding after a dental extraction earlier this morning. The patient's past medical history is significant for painful swelling of his knee joints after minor trauma. Aspiration of the joints during several occasions yielded frank blood, and he was diagnosed with hemarthrosis. He has no known allergies. Currently, hemostasis in this patient most likely can be achieved by the administration of which of the following?

A. Factor XII
B. Fibrinogen
C. Protein C
D. Thrombin
E. Urokinase

Submit

1
2
3
4
5
6
7
8
9
10
11
12
13
14
15
16
17
18
19
20
21
22
23
24
25
26
27
28
29
30

A 6-year-old boy is brought to the emergency department due to bleeding after a dental extraction earlier this morning. The patient's past medical history is significant for painful swelling of his knee joints after minor trauma. Aspiration of the joints during several occasions yielded frank blood, and he was diagnosed with hemarthrosis. He has no known allergies. Currently, hemostasis in this patient most likely can be achieved by the administration of which of the following?

A. Factor XII (15%)

B. Fibrinogen (15%)

C. Protein C (9%)

✓ D. Thrombin (57%)

E. Urokinase (2%)

Omitted
Correct answer
D

57%
Answered correctly

02 secs
Time Spent

06/20/2020
Last Updated

Explanation

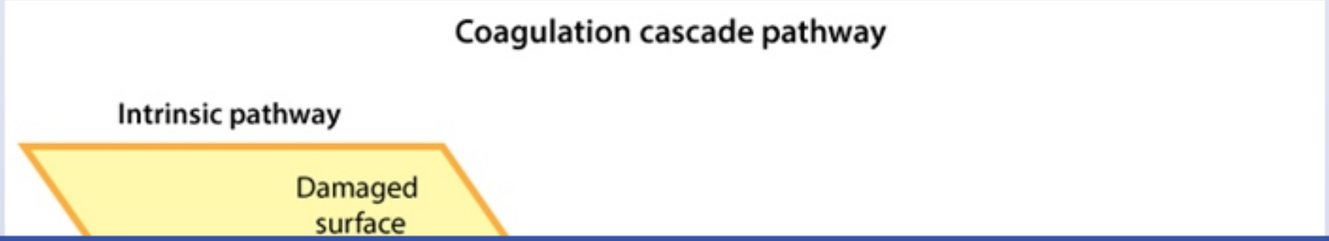

1
2
3
4
5
6
7
8
9
10
11
12
13
14
15
16
17
18
19
20
21
22
23
24
25
26
27
28
29
30

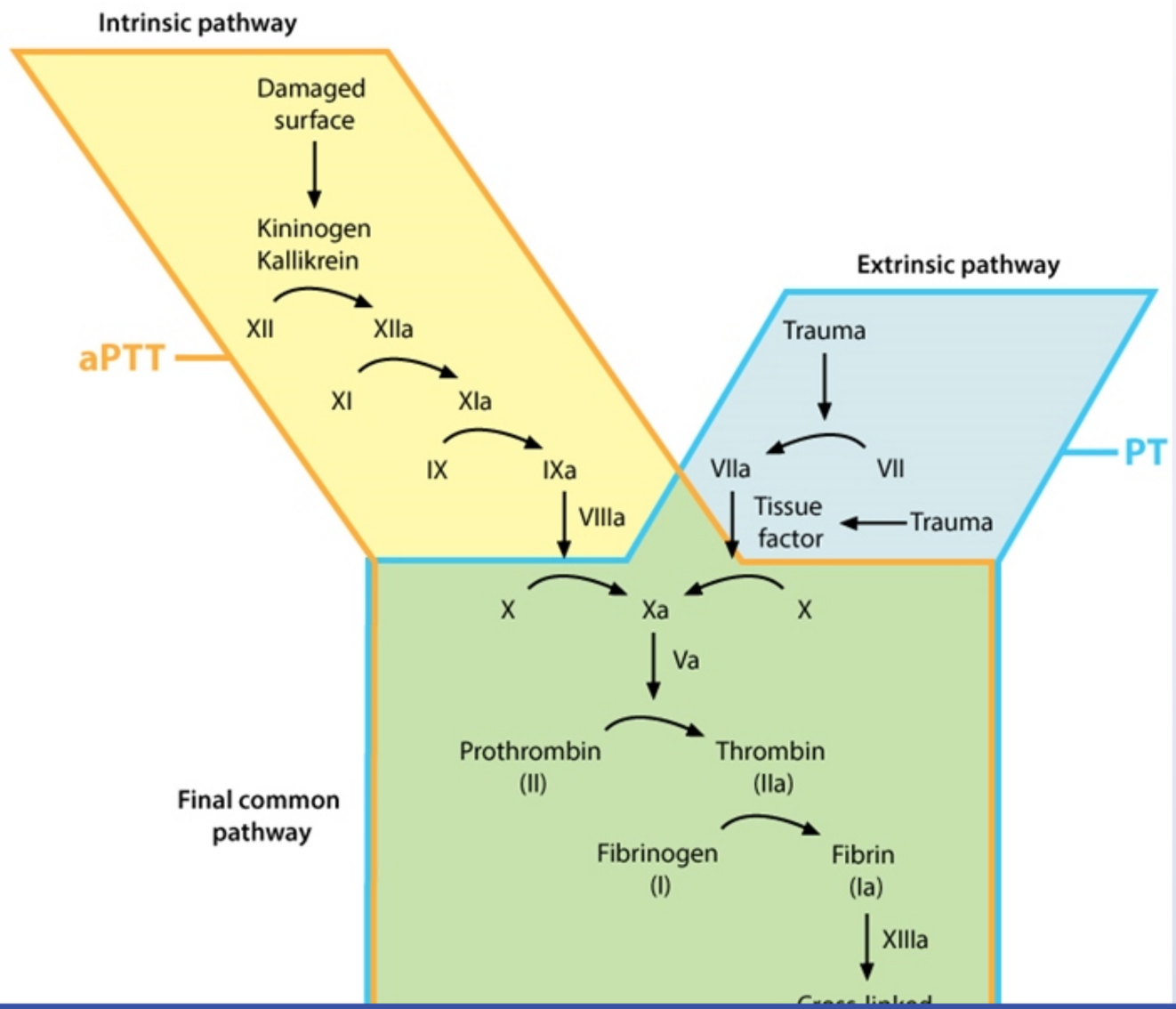

1
2
3
4
5
6
7
8
9
10
11
12
13
14
15
16
17
18
19
20
21
22
23
24
25
26
27
28
29
30

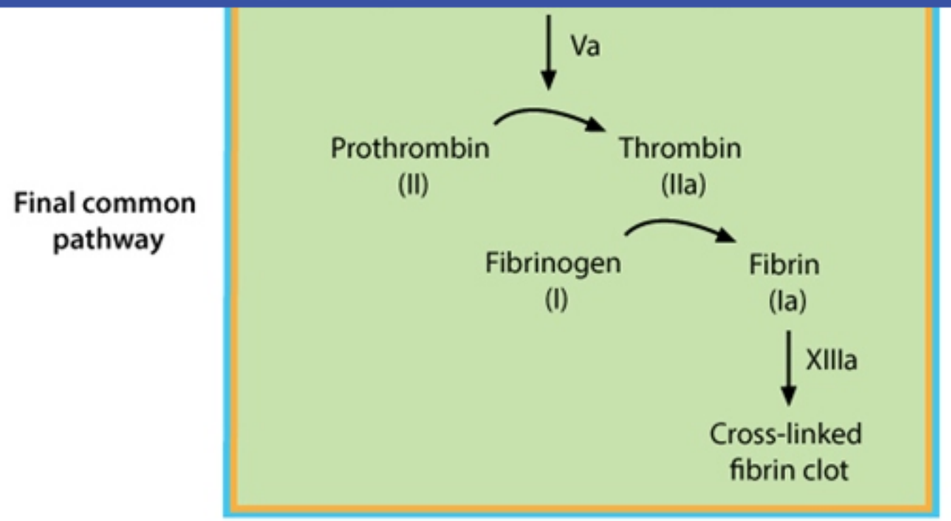

©UWorld

aPTT = activated partial thromboplastin time; **PT** = prothrombin time.

A history of prolonged bleeding following procedures (eg, dental extractions, surgeries) and spontaneous hemorrhages into the joints (hemarthrosis) is typical for **hemophilia**, an X-linked recessive bleeding disorder due to decreased levels of factor VIII (hemophilia A) or factor IX (hemophilia B).

Factors VIII and IX are components of the **intrinsic** coagulation pathway and activate factor X; activated factor X (Xa) then catalyzes the conversion of prothrombin (factor II) into thrombin as part of the final common pathway. In the absence of factors VIII or IX, activation of factor X and subsequent conversion of prothrombin into thrombin do not occur. Administration of **thrombin**, however, will make up for the deficiency and lead to blood clotting. In practice, prothrombin complex concentrates (containing factors II, VII, IX, and X, which lead to thrombin formation) were used for management of hemophilia B, although thrombogenic risks have limited their application.

In both types of hemophilia, the bleeding time and platelet count are normal. The prothrombin time (PT) is also normal as it tests the **e**xtrinsic clotting pathway and reflects the function of factors II, V, VII, and X (mnemonic: P**e**T). However, the activated partial thromboplastin time (PTT) is prolonged as it assesses the activity of factors II, V, VIII, IX, X, XI and XII, the **i**ntrinsic clotting pathway (mnemonic: P**i**TT). Diagnoses of hemophilia A and B are made by measuring plasma levels of factors VIII and IX, respectively.

In both types of hemophilia, the bleeding time and platelet count are normal. The prothrombin time (PT) is also normal as it tests the **e**xtrinsic clotting pathway and reflects the function of factors II, V, VII, and X (mnemonic: P**e**T). However, the activated partial thromboplastin time (PTT) is prolonged as it assesses the activity of factors II, V, VIII, IX, X, XI and XII, the **i**ntrinsic clotting pathway (mnemonic: P**i**TT). Diagnoses of hemophilia A and B are made by measuring plasma levels of factors VIII and IX, respectively.

(Choice A) Factor XII (Hageman) is synthesized by the liver and is activated by endothelial injury. It triggers the intrinsic coagulation pathway by activating factor XI. The addition of factor XII does not clot the blood of patients with hemophilia because the downstream clotting factors VIII or IX are deficient.

(Choice B) Fibrinogen is a protein synthesized by the liver. Thrombin mediates cleavage of fibrinogen to form fibrin, the main component of thrombi; therefore, without thrombin, fibrinogen administration alone would not be helpful.

(Choice C) Protein C is a vitamin K-dependent factor synthesized in the liver. It is a physiologic anticoagulant that degrades factors Va and VIIIa.

(Choice E) Urokinase is a thrombolytic agent used for treatment of myocardial infarction and pulmonary embolism. It acts by converting plasminogen to plasmin, which then breaks down fibrinogen and fibrin into their respective degradation products. The addition of urokinase would prevent thrombosis.

Educational objective:
Bleeding after a tooth extraction and history of hemarthrosis are suggestive of hemophilia. Decreased levels of factor VIII or IX lead to failure to convert prothrombin into thrombin and deficient thrombus formation. The addition of thrombin to the blood of a patient with hemophilia results in clotting.

References

- Prothrombin complex concentrates in emergency bleeding disorders.

Pathology	Hematology & Oncology	Hemophilias
Subject	System	Topic

Copyright © UWorld. All rights reserved.

1
2
3
4
5
6
7
8
9
10
11
12
13
14
15
16
17
18
19
20
21
22
23
24
25
26
27
28
29
30

A 32-year-old Caucasian woman experiences three episodes of deep venous thrombosis in a six year period. She has a history of pulmonary embolism as well. The patient's partial thromboplastin time (PTT) is within normal limits, and remains unchanged when activated protein C is added to her plasma. The most likely cause of this patient's problem is:

A. Immune
B. Nutritional
C. Inherited
D. Infectious
E. Neoplastic

Submit

1
2
3
4
5
6
7
8
9
10
11
12
13
14
15
16
17
18
19
20
21
22
23
24
25
26
27
28
29
30

A 32-year-old Caucasian woman experiences three episodes of deep venous thrombosis in a six year period. She has a history of pulmonary embolism as well. The patient's partial thromboplastin time (PTT) is within normal limits, and remains unchanged when activated protein C is added to her plasma. The most likely cause of this patient's problem is:

A. Immune (18%)
B. Nutritional (4%)
✓ C. Inherited (70%)
D. Infectious (1%)
E. Neoplastic (5%)

Omitted
Correct answer
C

70%
Answered correctly

02 secs
Time Spent

02/03/2020
Last Updated

Explanation

This is a young patient with recurrent deep venous thromboses, features indicative of a hypercoagulable state. Inherited causes of hypercoagulability must be considered in all patients under age 50 who present with thromboses in the absence of any obvious explanation for an acquired prothrombotic state.

The patient's plasma is resistant to the normally antithrombotic effects of activated protein C. Thus, the most likely diagnosis is a mutation in the factor V gene, which renders factor Va resistant to inactivation by activated protein C. Approximately 2–15% of Caucasians carry a specific factor V mutation, the Leiden mutation. The factor V Leiden mutation and mutations in the prothrombin gene are the most common inherited causes of

1
2
3
4
5
6
7
8
9
10
11
12
13
14
15
16
17
18
19
20
21
22
23
24
25
26
27
28
29
30

This is a young patient with recurrent deep venous thromboses, features indicative of a hypercoagulable state. Inherited causes of hypercoagulability must be considered in all patients under age 50 who present with thromboses in the absence of any obvious explanation for an acquired prothrombotic state.

The patient's plasma is resistant to the normally antithrombotic effects of activated protein C. Thus, the most likely diagnosis is a mutation in the factor V gene, which renders factor Va resistant to inactivation by activated protein C. Approximately 2–15% of Caucasians carry a specific factor V mutation, the Leiden mutation. The factor V Leiden mutation and mutations in the prothrombin gene are the most common inherited causes of hypercoagulability. Activated protein C resistance (factor V Leiden mutation) is detected in approximately 20% (range 12–40%) of patients with abnormal venous thromboses.

(Choice A) Antiphospholipid antibody syndrome is a common immune cause of hypercoagulability. This condition is defined by the presence of antiphospholipid antibodies (lupus anticoagulant and/or anticardiolipin antibodies) plus one or more of the following: venous thromboembolism, arterial thromboembolism, or frequent fetal loss. Unlike the patient in the vignette, patients with antiphospholipid antibody syndrome typically have a prolonged baseline aPTT. Lupus anticoagulants are the most common cause of aPTT prolongation.

(Choice B) Folic acid deficiency can cause hyperhomocysteinemia, which is a prothrombotic state. However, activated protein C resistance is not seen with this condition.

(Choice D) Endovascular infections and/or systemic inflammatory states may affect vascular endothelial cells in a way that favors thrombosis. However, infection and inflammatory mediators do not directly promote activated protein C resistance in the aPTT coagulation test.

(Choice E) A paraneoplastic syndrome of hypercoagulability may be seen in some patients with cancer, especially patients with adenocarcinomas of the pancreas, colon, or lung. The mechanism of cancer-induced hypercoagulability is thought to involve release of procoagulant tumor products. Vascular stasis due to obstruction of blood flow by the tumor, patient immobility, hepatic involvement and dysfunction, sepsis, and advanced age may also contribute to the tendency toward thrombosis in cancer patients. None of these mechanisms/factors directly promotes activated protein C resistance in the aPTT coagulation test.

Educational Objective:
Inherited causes of hypercoagulability should be considered in patients younger than age 50 who present with thrombosis and no obvious

V mutation, the Leiden mutation. The factor V Leiden mutation and mutations in the prothrombin gene are the most common inherited causes of hypercoagulability. Activated protein C resistance (factor V Leiden mutation) is detected in approximately 20% (range 12–40%) of patients with abnormal venous thromboses.

(Choice A) Antiphospholipid antibody syndrome is a common immune cause of hypercoagulability. This condition is defined by the presence of antiphospholipid antibodies (lupus anticoagulant and/or anticardiolipin antibodies) plus one or more of the following: venous thromboembolism, arterial thromboembolism, or frequent fetal loss. Unlike the patient in the vignette, patients with antiphospholipid antibody syndrome typically have a prolonged baseline aPTT. Lupus anticoagulants are the most common cause of aPTT prolongation.

(Choice B) Folic acid deficiency can cause hyperhomocysteinemia, which is a prothrombotic state. However, activated protein C resistance is not seen with this condition.

(Choice D) Endovascular infections and/or systemic inflammatory states may affect vascular endothelial cells in a way that favors thrombosis. However, infection and inflammatory mediators do not directly promote activated protein C resistance in the aPTT coagulation test.

(Choice E) A paraneoplastic syndrome of hypercoagulability may be seen in some patients with cancer, especially patients with adenocarcinomas of the pancreas, colon, or lung. The mechanism of cancer-induced hypercoagulability is thought to involve release of procoagulant tumor products. Vascular stasis due to obstruction of blood flow by the tumor, patient immobility, hepatic involvement and dysfunction, sepsis, and advanced age may also contribute to the tendency toward thrombosis in cancer patients. None of these mechanisms/factors directly promotes activated protein C resistance in the aPTT coagulation test.

Educational Objective:
Inherited causes of hypercoagulability should be considered in patients younger than age 50 who present with thrombosis and no obvious explanation for an acquired prothrombotic state. The factor V Leiden mutation, which causes factor Va resistance to inactivation by activated protein C, may account for approximately 20% of cases of atypical venous thrombosis.

Pathology	Hematology & Oncology	Inherited thrombophilia
Subject	System	Topic

Copyright © UWorld. All rights reserved.

A 45-year-old man comes to the office due to a week of purulent nasal discharge, headache, sore throat, and nonproductive cough. He has no significant past medical history except for an episode of infectious mononucleosis at age 22. The patient smokes a pack of cigarettes daily. His temperature is 38 C (100.4 F). He has maxillary sinus tenderness, pharyngeal erythema, and tender anterior cervical lymphadenopathy. Laboratory results are as follows:

Leukocytes	58,000/mm^3
Neutrophils	42%
Myelocytes	30%
Metamyelocytes	8%
Band forms	1%
Blast cells	1%
Eosinophils	6%
Basophils	4%

The leukocyte alkaline phosphatase score is low. Which of the following is the most likely diagnosis?

A. Acute lymphoblastic leukemia
B. Acute myelogenous leukemia
C. Burkitt lymphoma
D. Chronic lymphocytic leukemia
E. Chronic myelogenous leukemia

Band forms	1%
Blast cells	1%
Eosinophils	6%
Basophils	4%

The leukocyte alkaline phosphatase score is low. Which of the following is the most likely diagnosis?

A. Acute lymphoblastic leukemia
B. Acute myelogenous leukemia
C. Burkitt lymphoma
D. Chronic lymphocytic leukemia
E. Chronic myelogenous leukemia
F. Diffuse large B-cell lymphoma
G. Follicular lymphoma
H. Fungal superinfection
I. Leukemoid reaction
J. Parasitic superinfection

Submit

Band forms	1%
Blast cells	1%
Eosinophils	6%
Basophils	4%

The leukocyte alkaline phosphatase score is low. Which of the following is the most likely diagnosis?

- A. Acute lymphoblastic leukemia (1%)
- B. Acute myelogenous leukemia (14%)
- C. Burkitt lymphoma (13%)
- D. Chronic lymphocytic leukemia (3%)
- ✓ E. Chronic myelogenous leukemia (44%)
- F. Diffuse large B-cell lymphoma (4%)
- G. Follicular lymphoma (1%)
- H. Fungal superinfection (1%)
- I. Leukemoid reaction (12%)
- J. Parasitic superinfection (2%)

Omitted
Correct answer

44%
Answered correctly

08 secs
Time Spent

07/07/2020
Last Updated

Hematopoiesis: Myeloid lineage

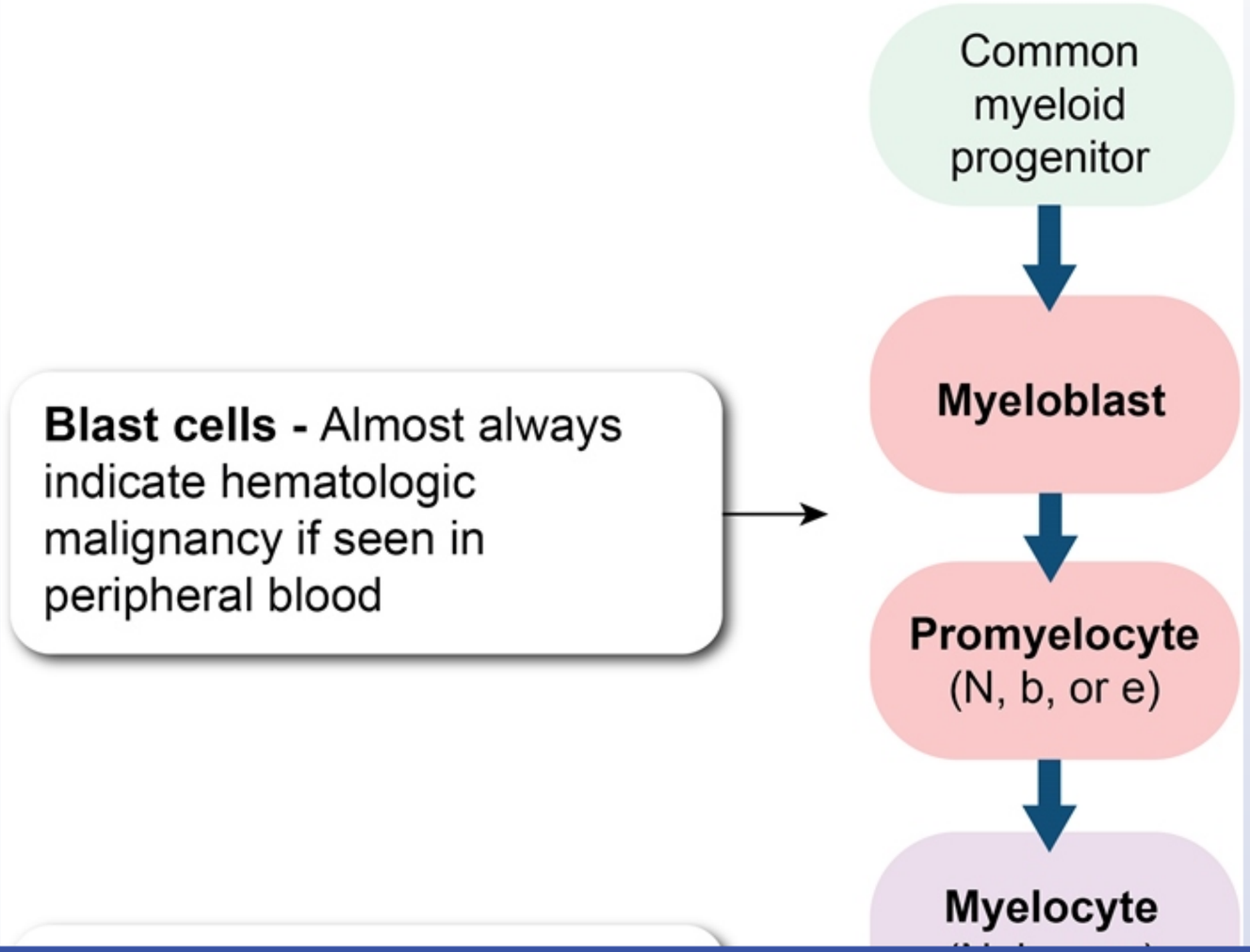

1
2
3
4
5
6
7
8
9
10
11
12
13
14
15
16
17
18
19
20
21
22
23
24
25
26
27
28
29
30

Common myeloid progenitor

↓

Myeloblast

↓

Promyelocyte (N, b, or e)

↓

Myelocyte (N, b, or e)

↓

Blast cells - Almost always indicate hematologic malignancy if seen in peripheral blood

Can sometimes be seen in peripheral blood (eg, leukemoid

1
2
3
4
5
6
7
8
9
10
11
12
13
14
15
16
17
18
19
20
21
22
23
24
25
26
27
28
29
30

Blast cells - Almost always indicate hematologic malignancy if seen in peripheral blood

Can sometimes be seen in peripheral blood (eg, leukemoid reaction, pregnancy)

Myeloblast

↓

Promyelocyte
(N, b, or e)

↓

Myelocyte
(N, b, or e)

↓

Metamyelocyte
(N, b, or e)

↓

Band

1
2
3
4
5
6
7
8
9
10
11
12
13
14
15
16
17
18
19
20
21
22
23
24
25
26
27
28
29
30

Exhibit Display

Hematopoiesis: Myeloid lineage

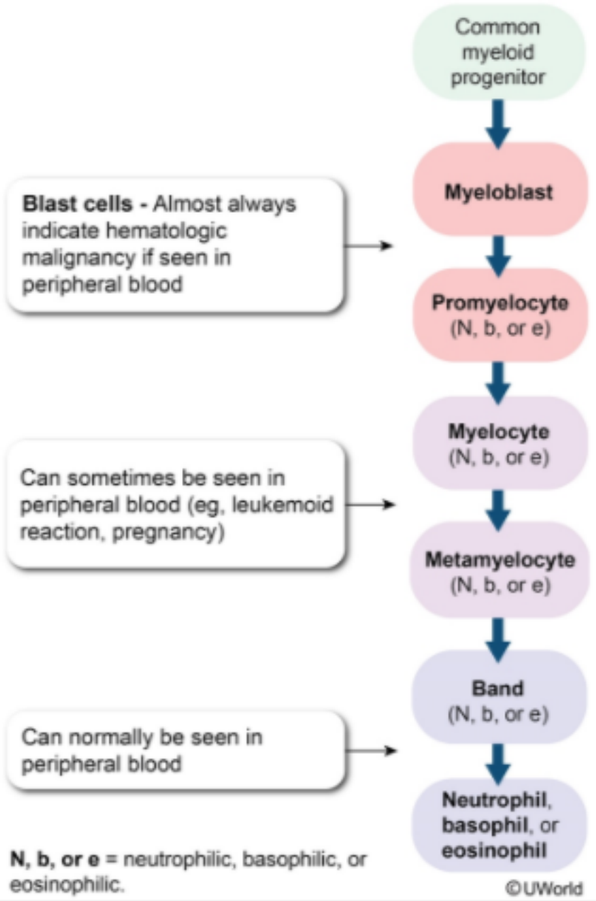

Zoom In | Zoom Out | Reset | Add To New Card | Existing Card

This patient with sinusitis is found to have a markedly elevated white blood cell (WBC) count with an increase in myeloid precursor forms on peripheral blood smear. The differential diagnosis is **chronic myelogenous leukemia** (CML) (uncontrolled mature granulocyte production, mostly neutrophils but also basophils and eosinophils) or leukemoid reaction (over-exuberant WBC response associated with bacterial infection or malignancy, among others). Both cause an **elevated WBC** count ($\geq$50,000/mm^3) with **an increase in precursor forms** (eg, bands, metamyelocytes, myelocytes). However, the enzyme **leukocyte (neutrophil) alkaline phosphatase** is **decreased** in CML (as seen in this patient) because the WBCs are cytochemically abnormal; by contrast, it is normal or elevated in a leukemoid reaction **(Choice I)**.

Other clues to the diagnosis of CML are the predominance of myelocytes compared to more mature forms such as metamyelocytes (**"myelocytic bulge"**) and the absolute **basophilia and eosinophilia**. CML is confirmed by demonstration of the Philadelphia chromosome (translocation between chromosomes 9 and 22) or the *BCR-ABL1* fusion gene or mRNA. Immature blast cells (eg, myeloblasts, promyelocytes) are typically <2%. Management generally includes a tyrosine kinase inhibitor.

(Choice A) This patient has an abnormality of myeloid (not lymphoid) cells and his smear shows only 1% blasts. In general, >25% bone marrow lymphoblasts are seen in acute lymphoblastic leukemia, which is much more common in young children.

(Choice B) Acute myelogenous leukemia is the most common acute leukemia in adults. However, the mean age at diagnosis is around 65, and most patients will have a WBC count of about 15,000-20,000/mm^3 with a significant increase in blast cells (eg, $\geq$20%) rather than the 1% seen in this patient.

(Choices C, F, and G) Follicular lymphoma, Burkitt lymphoma, and diffuse large B-cell lymphoma cause lymph node and/or soft-tissue (not peripheral blood) abnormalities. In addition, these cancers are all lymphoid, not myeloid, in nature.

(Choice D) Patients with chronic lymphocytic leukemia have increased circulating mature lymphoid cells, not increased myeloid cells.

(Choices H and J) Parasitic superinfection (which can lead to eosinophilia) and fungal infection would not explain the predominance of myeloid neutrophil precursor forms in this patient.

Educational objective:
Chronic myelogenous leukemia (CML) and leukemoid reaction can have presentations similar to leukocytosis; however, leukocyte (neutrophil) alkaline phosphatase level is normal or elevated in a leukemoid reaction but decreased in CML. The definitive diagnosis of CML requires demonstration of the Philadelphia chromosome t(9;22) or *BCR-ABL* fusion gene or mRNA.

bulge") and the absolute **basophilia and eosinophilia**. CML is confirmed by demonstration of the Philadelphia chromosome (translocation between chromosomes 9 and 22) or the *BCR-ABL1* fusion gene or mRNA. Immature blast cells (eg, myeloblasts, promyelocytes) are typically <2%. Management generally includes a tyrosine kinase inhibitor.

(Choice A) This patient has an abnormality of myeloid (not lymphoid) cells and his smear shows only 1% blasts. In general, >25% bone marrow lymphoblasts are seen in acute lymphoblastic leukemia, which is much more common in young children.

(Choice B) Acute myelogenous leukemia is the most common acute leukemia in adults. However, the mean age at diagnosis is around 65, and most patients will have a WBC count of about 15,000-20,000/mm^3 with a significant increase in blast cells (eg, ≥20%) rather than the 1% seen in this patient.

(Choices C, F, and G) Follicular lymphoma, Burkitt lymphoma, and diffuse large B-cell lymphoma cause lymph node and/or soft-tissue (not peripheral blood) abnormalities. In addition, these cancers are all lymphoid, not myeloid, in nature.

(Choice D) Patients with chronic lymphocytic leukemia have increased circulating mature lymphoid cells, not increased myeloid cells.

(Choices H and J) Parasitic superinfection (which can lead to eosinophilia) and fungal infection would not explain the predominance of myeloid neutrophil precursor forms in this patient.

Educational objective:
Chronic myelogenous leukemia (CML) and leukemoid reaction can have presentations similar to leukocytosis; however, leukocyte (neutrophil) alkaline phosphatase level is normal or elevated in a leukemoid reaction but decreased in CML. The definitive diagnosis of CML requires demonstration of the Philadelphia chromosome t(9;22) or *BCR-ABL* fusion gene or mRNA.

References

- How I treat newly diagnosed chronic myeloid leukemia in 2015.

Pathology	Hematology & Oncology	Chronic myeloid leukemia
Subject	System	Topic

Copyright © UWorld. All rights reserved.

1
2
3
4
5
6
7
8
9
10
11
12
13
14
15
16
17
18
19
20
21
22
23
24
25
26
27
28
29
30

A 55-year-old Caucasian male is found on colonoscopy to have a solitary mass in his sigmoid colon. Biopsy is consistent with colon cancer, and surgery is scheduled. Which of the following features would carry the worst prognosis in this patient?

A. Presence of clinical symptoms

B. Tumor penetration into the muscularis propria

C. Poor differentiation of tumor cells

D. High degree of tumor cell aneuploidy

E. High number of mitotic figures

Submit

A 55-year-old Caucasian male is found on colonoscopy to have a solitary mass in his sigmoid colon. Biopsy is consistent with colon cancer, and surgery is scheduled. Which of the following features would carry the worst prognosis in this patient?

- A. Presence of clinical symptoms (2%)
- ✓ B. Tumor penetration into the muscularis propria (76%)
- C. Poor differentiation of tumor cells (13%)
- D. High degree of tumor cell aneuploidy (2%)
- E. High number of mitotic figures (5%)

Omitted
Correct answer
B

76%
Answered correctly

01 sec
Time Spent

02/03/2020
Last Updated

Explanation

The extent of tumor expansion is characterized by the ***stage*** of a tumor. The degree of tumor differentiation (from well-differentiated to anaplastic) is referred to as the ***grade***. Tumor stage is the most important criteria for determining prognosis.

If the tumor is confined to the mucosa (stage A), the patient has 90%+ chance of 5-year survival. If it involves the muscular layer, 5-year survival rate is 70-80%. Lymph node involvement (stage C) and distant metastasis (stage D) have poor prognosis.

(Choice A) Colon adenocarcinomas tend to be asymptomatic at early stages, which is why screening colonoscopies are so important. By the time symptoms appear, tumor size is substantial. Clinical manifestations, however, do not correlate as well with prognosis as the stage of an

Omitted
Correct answer
B

76%
Answered correctly

01 sec
Time Spent

02/03/2020
Last Updated

Explanation

The extent of tumor expansion is characterized by the ***stage*** of a tumor. The degree of tumor differentiation (from well-differentiated to anaplastic) is referred to as the ***grade***. Tumor stage is the most important criteria for determining prognosis.

If the tumor is confined to the mucosa (stage A), the patient has 90%+ chance of 5-year survival. If it involves the muscular layer, 5-year survival rate is 70-80%. Lymph node involvement (stage C) and distant metastasis (stage D) have poor prognosis.

(Choice A) Colon adenocarcinomas tend to be asymptomatic at early stages, which is why screening colonoscopies are so important. By the time symptoms appear, tumor size is substantial. Clinical manifestations, however, do not correlate as well with prognosis as the stage of an adenocarcinoma does.

(Choices C, D and E) Tumor cell differentiation, degree of aneuploidy, and number of mitotic figures determines the grade of the tumor. Remember that stage is more important than grade in determining the prognosis of colon cancer.

Educational Objective:
Prognosis of colorectal adenocarcinoma is directly related to the stage of the tumor (not to the grade!).

Pathology	Hematology & Oncology	Colorectal cancer
Subject	System	Topic

Copyright © UWorld. All rights reserved.

1
2
3
4
5
6
7
8
9
10
11
12
13
14
15
16
17
18
19
20
21
22
23
24
25
26
27
28
29
30

A 47-year-old woman, gravida 2 para 2, comes to the office after noticing a pea-sized lump in her right breast while taking a shower. Her medical history is significant for 3 pack-years of cigarette use during her 20s. She underwent infertility treatment and in vitro fertilization for both of her pregnancies. The patient has no family history of breast or ovarian cancer. A clinical breast examination confirms the presence of a firm, fixed nodule in the right breast with a small patch of overlying puckered skin. Mammogram findings are highly suspicious for malignancy, and a needle biopsy reveals infiltrating ductal carcinoma. A right mastectomy and axillary lymph node dissection are scheduled. Overexpression of which of the following markers is most likely to be associated with aggressive disease in this patient?

A. BCL-2

B. Estrogen receptor

C. HER2

D. Mutated p53

E. Progesterone receptor

Submit

A 47-year-old woman, gravida 2 para 2, comes to the office after noticing a pea-sized lump in her right breast while taking a shower. Her medical history is significant for 3 pack-years of cigarette use during her 20s. She underwent infertility treatment and in vitro fertilization for both of her pregnancies. The patient has no family history of breast or ovarian cancer. A clinical breast examination confirms the presence of a firm, fixed nodule in the right breast with a small patch of overlying puckered skin. Mammogram findings are highly suspicious for malignancy, and a needle biopsy reveals infiltrating ductal carcinoma. A right mastectomy and axillary lymph node dissection are scheduled. Overexpression of which of the following markers is most likely to be associated with aggressive disease in this patient?

- A. BCL-2 (6%)
- B. Estrogen receptor (13%)
- ✓ C. HER2 (67%)
- D. Mutated p53 (11%)
- E. Progesterone receptor (1%)

Omitted
Correct answer
C

67%
Answered correctly

02 secs
Time Spent

04/07/2020
Last Updated

Explanation

Human epidermal growth factor receptor 2 (**HER2**, also called ERBB2) is a member of the epidermal growth factor receptor family. It is overexpressed in 20%-30% of **breast cancers**. HER2 is a transmembrane glycoprotein with **tyrosine kinase** activity that acts to increase cell proliferation. It is present in diminutive amounts in normal breast and ovarian cells. In breast cancer, HER2 overexpression (positivity) is associated with **poorly differentiated, rapidly growing tumors**. Clinically, HER2 status is used to predict therapeutic response to anti-HER2

1 2 3 4 5 6 7 8 9 10 11 12 13 14 15 16 17 18 19 20 21 22 23 24 25 26 27 28 29 30

Human epidermal growth factor receptor 2 (**HER2**, also called ERBB2) is a member of the epidermal growth factor receptor family. It is overexpressed in 20%-30% of **breast cancers**. HER2 is a transmembrane glycoprotein with **tyrosine kinase** activity that acts to increase cell proliferation. It is present in diminutive amounts in normal breast and ovarian cells. In breast cancer, HER2 overexpression (positivity) is associated with **poorly differentiated, rapidly growing tumors**. Clinically, HER2 status is used to predict therapeutic response to anti-HER2 monoclonal antibodies (eg, trastuzumab).

(Choice A) Overexpression of the anti-apoptotic BCL-2 protein is classically observed in follicular lymphomas, but it also occurs in a variety of other malignancies, including breast cancer. Unlike in lymphomas, increased expression of BCL-2 in breast cancer is associated with a favorable prognosis.

(Choices B and E) Breast cancers that express high levels of estrogen and/or progesterone receptors are typically associated with improved outcomes. Activation of these receptors acts as a stimulus for tumor growth. Therefore, anti-estrogen therapy (eg, aromatase inhibitors, tamoxifen) is used to treat hormone receptor-positive breast cancer.

(Choice D) Overexpression of a mutated form of p53 is found in many human cancers, including breast cancers. However, the degree of protein expression does not correlate well with clinical outcomes. Rather, the effects on prognosis are more dependent on the specific mutation (eg, nonsense, gain of function).

Educational objective:
Estrogen- or progesterone-receptor positivity in breast cancer indicates expected sensitivity to tamoxifen and aromatase inhibitor treatment. HER2 overexpression in breast cancer suggests a more aggressive tumor that typically responds to therapy with the anti-HER2 monoclonal antibody trastuzumab.

References

- American Society of Clinical Oncology 2007 update of recommendations for the use of tumor markers in breast cancer.

Pathology	Hematology & Oncology	Breast cancer
Subject	System	Topic

Copyright © UWorld. All rights reserved.

angle tenderness is present. The patient is given intravenous antibiotics. Over the next several hours, she has decreased urine output despite aggressive intravenous hydration. Blood is oozing around the central venous catheter. Laboratory results are as follows:

Complete blood count	
Hemoglobin	9.0 g/dL
Platelets	68,000/mm^3
Leukocytes	24,500/mm^3
Coagulation studies	
Prothrombin time	23 sec
Partial thromboplastin time	60 sec
Plasma fibrinogen	100 mg/dL (150-350)

Which of the following is the most likely cause of this patient's hematologic abnormalities?

A. Accumulation of anticardiolipin antibodies
B. Accumulation of ultra-large von Willebrand factor multimers
C. Consumptive coagulopathy
D. Immune-mediated platelet destruction
E. Impaired hepatic synthetic activity

Submit

1 2 3 4 5 6 7 8 9 10 11 12 13 14 15 16 17 18 19 20 21 22 23 24 25 26 27 28 29 30

1 2 3 4 5 6 7 8 9 10 11 12 13 14 15 16 17 18 19 20 21 22 23 24 25 26 27 28 29 30

A 50-year-old woman with a history of systemic lupus erythematosus is admitted with fever, chills, vomiting, and burning pain when urinating. Temperature is 39.3 C (102.7 F), blood pressure is 80/50 mm Hg, pulse is 120/min, and respirations are 20/min. On examination, costovertebral angle tenderness is present. The patient is given intravenous antibiotics. Over the next several hours, she has decreased urine output despite aggressive intravenous hydration. Blood is oozing around the central venous catheter. Laboratory results are as follows:

Complete blood count	
Hemoglobin	9.0 g/dL
Platelets	68,000/mm^3
Leukocytes	24,500/mm^3
Coagulation studies	
Prothrombin time	23 sec
Partial thromboplastin time	60 sec
Plasma fibrinogen	100 mg/dL (150-350)

Which of the following is the most likely cause of this patient's hematologic abnormalities?

A. Accumulation of anticardiolipin antibodies
B. Accumulation of ultra-large von Willebrand factor multimers
C. Consumptive coagulopathy
D. Immune-mediated platelet destruction
E. Impaired hepatic synthetic activity

angle tenderness is present. The patient is given intravenous antibiotics. Over the next several hours, she has decreased urine output despite aggressive intravenous hydration. Blood is oozing around the central venous catheter. Laboratory results are as follows:

Complete blood count	
Hemoglobin	9.0 g/dL
Platelets	68,000/mm^3
Leukocytes	24,500/mm^3
Coagulation studies	
Prothrombin time	23 sec
Partial thromboplastin time	60 sec
Plasma fibrinogen	100 mg/dL (150-350)

Which of the following is the most likely cause of this patient's hematologic abnormalities?

A. Accumulation of anticardiolipin antibodies
B. Accumulation of ultra-large von Willebrand factor multimers
C. Consumptive coagulopathy
D. Immune-mediated platelet destruction
E. Impaired hepatic synthetic activity

Submit

angle tenderness is present. The patient is given intravenous antibiotics. Over the next several hours, she has decreased urine output despite aggressive intravenous hydration. Blood is oozing around the central venous catheter. Laboratory results are as follows:

Complete blood count	
Hemoglobin	9.0 g/dL
Platelets	68,000/mm^3
Leukocytes	24,500/mm^3
Coagulation studies	
Prothrombin time	23 sec
Partial thromboplastin time	60 sec
Plasma fibrinogen	100 mg/dL (150-350)

Which of the following is the most likely cause of this patient's hematologic abnormalities?

A. Accumulation of anticardiolipin antibodies (8%)
B. Accumulation of ultra-large von Willebrand factor multimers (3%)
✓ C. Consumptive coagulopathy (73%)
D. Immune-mediated platelet destruction (11%)
E. Impaired hepatic synthetic activity (2%)

Omitted
Correct answer

73%
Answered correctly

06 secs
Time Spent

06/15/2020
Last Updated

Laboratory characteristics of coagulopathies					
	Platelet count	**Prothrombin time**	**Partial thromboplastin time**	**Plasma fibrinogen values**	**Peripheral blood smear**
von Willebrand disease	Normal	Normal	↑	Normal	Normal
Immune thrombocytopenic purpura	↓	Normal	Normal	Normal	Isolated thrombocytopenia
TTP-HUS	↓	Normal	Normal	Normal	RBC fragmentation
Disseminated intravascular coagulation	↓	↑	↑	↓	RBC fragmentation

HUS = hemolytic uremic syndrome; RBC = red blood cell; TTP = thrombotic thrombocytopenic purpura.

This patient's costovertebral angle tenderness, dysuria, and leukocytosis are indicative of acute pyelonephritis complicated by septic shock (hypotension, tachycardia). Her laboratory results show a consumptive coagulopathy (thrombocytopenia, prolonged PT/PTT, low fibrinogen), which, along with bleeding from the central catheter site, are likely due to **disseminated intravascular coagulation** (DIC).

DIC is a common complication of **sepsis** (particularly with gram-negative organisms) because **lipopolysaccharide** is a **procoagulant** that triggers the coagulation cascade. This leads to the formation of fibrin- and platelet-rich thrombi in the vasculature, which consumes platelets **(thrombocytopenia)**, coagulation factors **(prolonged PT/PTT)**, and fibrinogen. Fibrinolysis is then triggered to degrade the clots, which **elevates D-dimer** (a fibrin degradation product) and depletes protein C, protein S, and antithrombin. The thrombi also often shear red blood cells, leading to **microangiopathic hemolytic anemia** (MAHA).

Most patients with acute DIC have signs of bleeding, such as **oozing from vascular catheters**, mucocutaneous bleeding, ecchymosis, or petechiae. End organ damage (eg, renal insufficiency, pulmonary hemorrhage) is also common.

(Choice A) Anticardiolipin antibody is antiphospholipid antibody often seen in patients with lupus erythematosus. It can cause antiphospholipid antibody syndrome, which is marked by thromboembolism and fetal loss (not bleeding). Although patients often have prolonged PTT (because the

This patient's costovertebral angle tenderness, dysuria, and leukocytosis are indicative of acute pyelonephritis complicated by septic shock (hypotension, tachycardia). Her laboratory results show a consumptive coagulopathy (thrombocytopenia, prolonged PT/PTT, low fibrinogen), which, along with bleeding from the central catheter site, are likely due to **disseminated intravascular coagulation** (DIC).

DIC is a common complication of **sepsis** (particularly with gram-negative organisms) because **lipopolysaccharide** is a **procoagulant** that triggers the coagulation cascade. This leads to the formation of fibrin- and platelet-rich thrombi in the vasculature, which consumes platelets **(thrombocytopenia)**, coagulation factors **(prolonged PT/PTT)**, and fibrinogen. Fibrinolysis is then triggered to degrade the clots, which **elevates D-dimer** (a fibrin degradation product) and depletes protein C, protein S, and antithrombin. The thrombi also often shear red blood cells, leading to **microangiopathic hemolytic anemia** (MAHA).

Most patients with acute DIC have signs of bleeding, such as **oozing from vascular catheters**, mucocutaneous bleeding, ecchymosis, or petechiae. End organ damage (eg, renal insufficiency, pulmonary hemorrhage) is also common.

(Choice A) Anticardiolipin antibody is antiphospholipid antibody often seen in patients with lupus erythematosus. It can cause antiphospholipid antibody syndrome, which is marked by thromboembolism and fetal loss (not bleeding). Although patients often have prolonged PTT (because the antiphospholipid interferes with the PTT test), PT is normal.

(Choice B) Thrombotic thrombocytopenic purpura (TTP) is caused by reduced activity of von Willebrand factor–cleaving protein ADAMTS13, leading to the accumulation of ultra-large von Willebrand factor multimers that trap platelets and generate platelet-rich thrombi in the microvasculature. Although patients usually develop thrombocytopenia, MAHA, fever, confusion, and organ damage (eg, acute renal failure), the coagulation cascade is unaffected; therefore, PT/PTT and fibrinolysis (fibrinogen level) are normal, and bleeding does not occur.

(Choice D) Immune (idiopathic) thrombocytopenic purpura (ITP) is marked by autoantibodies to platelets/megakaryocytes; thrombocytopenia is the only peripheral blood abnormality. Coagulation studies (eg, PT, PTT) and fibrinogen levels are normal. Spontaneous bleeding is very uncommon unless the platelet count is <10,000/mm^3.

(Choice E) The liver generates thrombopoietin and the majority of clotting factors. Therefore, patients with significantly impaired hepatic function (eg, cirrhosis) sometimes have mild thrombocytopenia and prolonged coagulation studies. However, fibrinogen level is usually normal and this patient has no other signs of advanced hepatic dysfunction (eg, ascites, jaundice).

Educational objective:

Most patients with acute DIC have signs of bleeding, such as **oozing from vascular catheters**, mucocutaneous bleeding, ecchymosis, or petechiae. End organ damage (eg, renal insufficiency, pulmonary hemorrhage) is also common.

(Choice A) Anticardiolipin antibody is antiphospholipid antibody often seen in patients with lupus erythematosus. It can cause antiphospholipid antibody syndrome, which is marked by thromboembolism and fetal loss (not bleeding). Although patients often have prolonged PTT (because the antiphospholipid interferes with the PTT test), PT is normal.

(Choice B) Thrombotic thrombocytopenic purpura (TTP) is caused by reduced activity of von Willebrand factor–cleaving protein ADAMTS13, leading to the accumulation of ultra-large von Willebrand factor multimers that trap platelets and generate platelet-rich thrombi in the microvasculature. Although patients usually develop thrombocytopenia, MAHA, fever, confusion, and organ damage (eg, acute renal failure), the coagulation cascade is unaffected; therefore, PT/PTT and fibrinolysis (fibrinogen level) are normal, and bleeding does not occur.

(Choice D) Immune (idiopathic) thrombocytopenic purpura (ITP) is marked by autoantibodies to platelets/megakaryocytes; thrombocytopenia is the only peripheral blood abnormality. Coagulation studies (eg, PT, PTT) and fibrinogen levels are normal. Spontaneous bleeding is very uncommon unless the platelet count is <10,000/mm^3.

(Choice E) The liver generates thrombopoietin and the majority of clotting factors. Therefore, patients with significantly impaired hepatic function (eg, cirrhosis) sometimes have mild thrombocytopenia and prolonged coagulation studies. However, fibrinogen level is usually normal and this patient has no other signs of advanced hepatic dysfunction (eg, ascites, jaundice).

Educational objective:
Disseminated intravascular coagulation commonly occurs in the setting of sepsis and is characterized by widespread activation of the coagulation cascade with formation of microthrombi. Laboratory results reveal prolonged PT/PTT, thrombocytopenia, and low fibrinogen (ie, a consumptive coagulopathy), and patients usually have signs of bleeding (eg, oozing from venipuncture sites).

Pathology	Hematology & Oncology	DIC
Subject	System	Topic

Copyright © UWorld. All rights reserved.

1
2
3
4
5
6
7
8
9
10
11
12
13
14
15
16
17
18
19
20
21
22
23
24
25
26
27
28
29
30

A 41-year-old previously healthy woman comes to the office due to weakness and easy fatigability. She also has had several episodes of epistaxis and gum bleeding. Physical examination reveals mucosal pallor. Further evaluation demonstrates that the patient has a clonal proliferation of white blood cells containing an abnormal protein. In an experiment, the abnormal cells from the patient are purified and cultured in 2 different plates, one with a vitamin A derivative (plate 1) and the other with control (plate 2). After several days of incubation, cells in plate 1 are well differentiated compared to those in plate 2, and clonal proliferation is inhibited. This patient most likely has which of the following conditions?

A. Acute lymphocytic leukemia

B. Acute myeloid leukemia

C. Chronic lymphocytic leukemia

D. Chronic myeloid leukemia

E. High-grade non-Hodgkin lymphoma

Submit

1
2
3
4
5
6
7
8
9
10
11
12
13
14
15
16
17
18
19
20
21
22
23
24
25
26
27
28
29
30

A 41-year-old previously healthy woman comes to the office due to weakness and easy fatigability. She also has had several episodes of epistaxis and gum bleeding. Physical examination reveals mucosal pallor. Further evaluation demonstrates that the patient has a clonal proliferation of white blood cells containing an abnormal protein. In an experiment, the abnormal cells from the patient are purified and cultured in 2 different plates, one with a vitamin A derivative (plate 1) and the other with control (plate 2). After several days of incubation, cells in plate 1 are well differentiated compared to those in plate 2, and clonal proliferation is inhibited. This patient most likely has which of the following conditions?

A. Acute lymphocytic leukemia (4%)
✓ B. Acute myeloid leukemia (83%)
C. Chronic lymphocytic leukemia (3%)
D. Chronic myeloid leukemia (7%)
E. High-grade non-Hodgkin lymphoma (1%)

Omitted
Correct answer
B

83%
Answered correctly

02 secs
Time Spent

05/05/2020
Last Updated

Explanation

Acute promyelocytic leukemia (APL), type M3 of acute myelogenous leukemia in the French-American-British classification system, results from a **t(15;17) mutation** whereby the gene for retinoic acid receptor alpha (*RARα*) is transferred from chromosome 17 to chromosome 15, where it fuses with the promyelocytic leukemia (*PML*) gene. This leads to the formation of a new gene called ***PML/RARα***. Normally, *RARα* plays a role in the proper differentiation of myeloid precursors, as the receptor interacts with retinoic acid to affect transcription of genes required for maturation. However, the t(15;17) mutation in APML causes transcription repression and produces an **abnormal receptor** that is unable to signal for the

1 2 3 4 5 6 7 8 9 10 11 12 13 14 15 16 17 18 19 20 21 22 23 24 25 26 27 28 29 30

Acute promyelocytic leukemia (APL), type M3 of acute myelogenous leukemia in the French-American-British classification system, results from a **t(15;17) mutation** whereby the gene for retinoic acid receptor alpha (*RARα*) is transferred from chromosome 17 to chromosome 15, where it fuses with the promyelocytic leukemia (*PML*) gene. This leads to the formation of a new gene called ***PML/RARα***. Normally, *RARα* plays a role in the proper differentiation of myeloid precursors, as the receptor interacts with retinoic acid to affect transcription of genes required for maturation. However, the t(15;17) mutation in APML causes transcription repression and produces an **abnormal receptor** that is unable to signal for the differentiation of myeloid precursors at physiologic doses of retinoic acid.

Treatment with **all-trans-retinoic acid** (ATRA), a vitamin A derivative, overcomes this (partly by inducing PML/RARα proteolysis) and stimulates differentiation of myeloblasts into mature granulocytes. ATRA therapy induces remission in about 90% of patients with APL. APL is associated with disseminated intravascular coagulation.

(Choice A) Acute lymphocytic leukemia predominantly affects children. Blast cells positive for the CD10 antigen (CALLA) suggest a good prognosis.

(Choice C) Chronic lymphocytic leukemia is frequently seen in elderly patients. It presents with lymphadenopathy, hepatosplenomegaly, and anemia, and has an indolent course. Neoplastic cells resemble mature B lymphocytes.

(Choice D) In chronic myeloid leukemia (also commonly manifesting in elderly patients with fatigue, leukocytosis, and splenomegaly), myeloid precursors in different stages of differentiation proliferate. This disease is caused by a t(9;22) translocation that forms the *BCR-ABL* fusion gene, which codes for an abnormal tyrosine kinase.

(Choice E) Several high-grade non-Hodgkin lymphomas are associated with cytogenetic abnormalities. t(8;14), t(2;8), and t(8;22) are typical for Burkitt lymphoma; these translocations involve the c-*myc* oncogene. Burkitt lymphoma is associated with Epstein-Barr virus infection and classically has a "starry sky" histologic appearance.

Educational objective:
Acute promyelocytic leukemia is the M3 variant of acute myelogenous leukemia. It affects adult patients and may present with disseminated intravascular coagulation. The cytogenetic abnormality t(15;17) leads to formation of the promyelocytic leukemia-retinoic acid receptor alpha (*PML/RARα*) fusion gene, which is unable to signal for proper cellular differentiation, unlike the normal retinoic acid receptor.

However, the t(15;17) mutation in APML causes transcription repression and produces an **abnormal receptor** that is unable to signal for the differentiation of myeloid precursors at physiologic doses of retinoic acid.

Treatment with **all-trans-retinoic acid** (ATRA), a vitamin A derivative, overcomes this (partly by inducing PML/RARα proteolysis) and stimulates differentiation of myeloblasts into mature granulocytes. ATRA therapy induces remission in about 90% of patients with APL. APL is associated with disseminated intravascular coagulation.

(Choice A) Acute lymphocytic leukemia predominantly affects children. Blast cells positive for the CD10 antigen (CALLA) suggest a good prognosis.

(Choice C) Chronic lymphocytic leukemia is frequently seen in elderly patients. It presents with lymphadenopathy, hepatosplenomegaly, and anemia, and has an indolent course. Neoplastic cells resemble mature B lymphocytes.

(Choice D) In chronic myeloid leukemia (also commonly manifesting in elderly patients with fatigue, leukocytosis, and splenomegaly), myeloid precursors in different stages of differentiation proliferate. This disease is caused by a t(9;22) translocation that forms the *BCR-ABL* fusion gene, which codes for an abnormal tyrosine kinase.

(Choice E) Several high-grade non-Hodgkin lymphomas are associated with cytogenetic abnormalities. t(8;14), t(2;8), and t(8;22) are typical for Burkitt lymphoma; these translocations involve the c-*myc* oncogene. Burkitt lymphoma is associated with Epstein-Barr virus infection and classically has a "starry sky" histologic appearance.

Educational objective:
Acute promyelocytic leukemia is the M3 variant of acute myelogenous leukemia. It affects adult patients and may present with disseminated intravascular coagulation. The cytogenetic abnormality t(15;17) leads to formation of the promyelocytic leukemia-retinoic acid receptor alpha (*PML/RARα*) fusion gene, which is unable to signal for proper cellular differentiation, unlike the normal retinoic acid receptor.

Pathology	Hematology & Oncology	Acute myeloid leukemia
Subject	System	Topic

Copyright © UWorld. All rights reserved.

1
2
3
4
5
6
7
8
9
10
11
12
13
14
15
16
17
18
19
20
21
22
23
24
25
26
27
28
29
30

An 8-year-old boy with a one-week history of fever and throat pain is brought to the emergency department with severe dyspnea, tachypnea, and inspiratory stridor. He has also experienced worsening dysphagia with solid foods over the last two weeks. Laboratory evaluation reveals many immature hematopoietic cells (blasts) in the peripheral blood smear. The neoplastic cells causing this patient's condition normally give rise to which of the following?

A. B-lymphocytes
B. T-lymphocytes
C. Monocytes
D. Erythrocytes
E. Platelets

Submit

An 8-year-old boy with a one-week history of fever and throat pain is brought to the emergency department with severe dyspnea, tachypnea, and inspiratory stridor. He has also experienced worsening dysphagia with solid foods over the last two weeks. Laboratory evaluation reveals many immature hematopoietic cells (blasts) in the peripheral blood smear. The neoplastic cells causing this patient's condition normally give rise to which of the following?

A. B-lymphocytes (44%)
✓ B. T-lymphocytes (38%)
C. Monocytes (8%)
D. Erythrocytes (7%)
E. Platelets (0%)

Omitted
Correct answer
B

38%
Answered correctly

02 secs
Time Spent

05/08/2020
Last Updated

Explanation

Blast cells in the peripheral blood are strongly suggestive of leukemia. The most common pediatric malignancy is acute lymphoblastic leukemia (ALL). The neoplastic cells of ALL arise from lymphocytic precursors that are of either pre-B or pre-T lineage.

Clinical manifestations of ALL include fever, fatigue, pallor, petechiae, and bleeding. Leukemic spread can cause lymphadenopathy, hepatosplenomegaly, and bone pain. T-cell ALL is more likely to present with a large anterior mediastinal mass that can compress the great vessels, causing superior vena cava syndrome. The mediastinal mass can also compress the esophagus causing dysphagia, while compression

1 2 3 4 5 6 7 8 9 10 11 12 13 14 15 16 17 18 19 20 21 22 23 24 25 26 27 28 29 30

Blast cells in the peripheral blood are strongly suggestive of leukemia. The most common pediatric malignancy is acute lymphoblastic leukemia (ALL). The neoplastic cells of ALL arise from lymphocytic precursors that are of either pre-B or pre-T lineage.

Clinical manifestations of ALL include fever, fatigue, pallor, petechiae, and bleeding. Leukemic spread can cause lymphadenopathy, hepatosplenomegaly, and bone pain. T-cell ALL is more likely to present with a large anterior mediastinal mass that can compress the great vessels, causing superior vena cava syndrome. The mediastinal mass can also compress the esophagus causing dysphagia, while compression of the trachea may lead to dyspnea and stridor. This patient's clinical presentation is therefore most suggestive of T-cell ALL, which most commonly affects males in late childhood through young adulthood.

Because pre-B and pre-T lymphoblasts can look identical on peripheral blood smear, immunohistochemical staining is used to differentiate the two cell lineages. Both lineages contain TdT (an antigen of lymphocyte precursors). Cell surface markers for pre-B lymphoblasts include CD10+, CD 19+, and CD20+; while pre-T lymphoblasts express CD2+, CD3+, CD4+, CD5+, CD7+, and CD8+.

(Choice A) B-cell ALL is responsible for approximately 70-80% of all cases of ALL, whereas T-cell ALL accounts for 15-17% of all cases of ALL. B-cell ALL manifests with fever, malaise, bleeding, bone pain, and hepatosplenomegaly. Generally, B-cell ALL is not associated with symptoms of mediastinal compression.

(Choice C) Acute myeloid leukemia (AML) subtypes M4 and M5 arise from monocytic precursors. This is rarely seen in children and usually does not present as a mediastinal mass, though extramedullary disease is not an uncommon finding.

(Choice D) The rare AML M6 subtype arises from erythroid precursors and typically affects elderly patients.

(Choice E) The rare AML M7 subtype arises from primitive megakaryoblasts and is associated with t(1;22) and Down syndrome in children.

Educational objective:
Acute lymphoblastic leukemia (ALL) is the most common malignancy of childhood. B-cell ALL is responsible for approximately 70-80% of all cases of ALL, whereas T-cell ALL accounts for 15-17% of all cases of ALL. T-cell ALL often presents as a mediastinal mass that can cause respiratory symptoms, dysphagia, or superior vena cava syndrome.

Pathology Hematology & Oncology Acute lymphoblastic leukemia

1 2 3 4 5 6 7 8 9 10 11 12 13 14 15 16 17 18 19 20 21 22 23 24 25 26 27 28 29 30

Clinical manifestations of ALL include fever, fatigue, pallor, petechiae, and bleeding. Leukemic spread can cause lymphadenopathy, hepatosplenomegaly, and bone pain. T-cell ALL is more likely to present with a large anterior mediastinal mass that can compress the great vessels, causing superior vena cava syndrome. The mediastinal mass can also compress the esophagus causing dysphagia, while compression of the trachea may lead to dyspnea and stridor. This patient's clinical presentation is therefore most suggestive of T-cell ALL, which most commonly affects males in late childhood through young adulthood.

Because pre-B and pre-T lymphoblasts can look identical on peripheral blood smear, immunohistochemical staining is used to differentiate the two cell lineages. Both lineages contain TdT (an antigen of lymphocyte precursors). Cell surface markers for pre-B lymphoblasts include CD10+, CD 19+, and CD20+; while pre-T lymphoblasts express CD2+, CD3+, CD4+, CD5+, CD7+, and CD8+.

(Choice A) B-cell ALL is responsible for approximately 70-80% of all cases of ALL, whereas T-cell ALL accounts for 15-17% of all cases of ALL. B-cell ALL manifests with fever, malaise, bleeding, bone pain, and hepatosplenomegaly. Generally, B-cell ALL is not associated with symptoms of mediastinal compression.

(Choice C) Acute myeloid leukemia (AML) subtypes M4 and M5 arise from monocytic precursors. This is rarely seen in children and usually does not present as a mediastinal mass, though extramedullary disease is not an uncommon finding.

(Choice D) The rare AML M6 subtype arises from erythroid precursors and typically affects elderly patients.

(Choice E) The rare AML M7 subtype arises from primitive megakaryoblasts and is associated with t(1;22) and Down syndrome in children.

Educational objective:
Acute lymphoblastic leukemia (ALL) is the most common malignancy of childhood. B-cell ALL is responsible for approximately 70-80% of all cases of ALL, whereas T-cell ALL accounts for 15-17% of all cases of ALL. T-cell ALL often presents as a mediastinal mass that can cause respiratory symptoms, dysphagia, or superior vena cava syndrome.

Pathology	Hematology & Oncology	Acute lymphoblastic leukemia
Subject	System	Topic

Copyright © UWorld. All rights reserved.

1
2
3
4
5
6
7
8
9
10
11
12
13
14
15
16
17
18
19
20
21
22
23
24
25
26
27
28
29
30

A 63-year-old man comes to the office due to fatigue and easy bruising. He has no lymphadenopathy on physical examination. Laboratory results are as follows:

Complete blood count

Hemoglobin	8.0 g/dL
Platelets	40,000/mm^3
Leukocytes	20,500/mm^3

The patient's peripheral blood smear is shown in the image below:

1
2
3
4
5
6
7
8
9
10
11
12
13
14
15
16
17
18
19
20
21
22
23
24
25
26
27
28
29
30

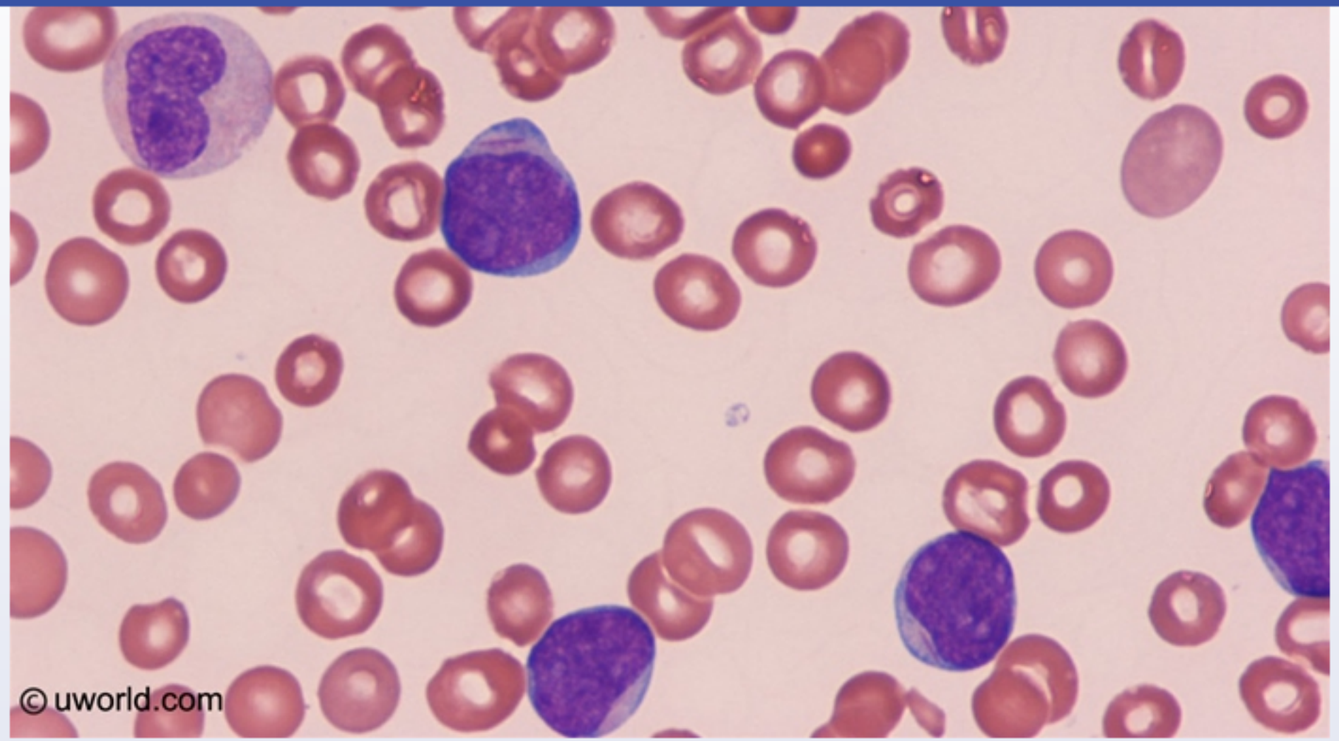

Which of the following is the most likely diagnosis?

- A. Acute lymphoblastic leukemia
- B. Acute myelogenous leukemia
- C. Chronic lymphocytic leukemia
- D. Chronic myelogenous leukemia
- E. Hairy cell leukemia
- F. Hodgkin lymphoma

1
2
3
4
5
6
7
8
9
10
11
12
13
14
15
16
17
18
19
20
21
22
23
24
25
26
27
28
29
30

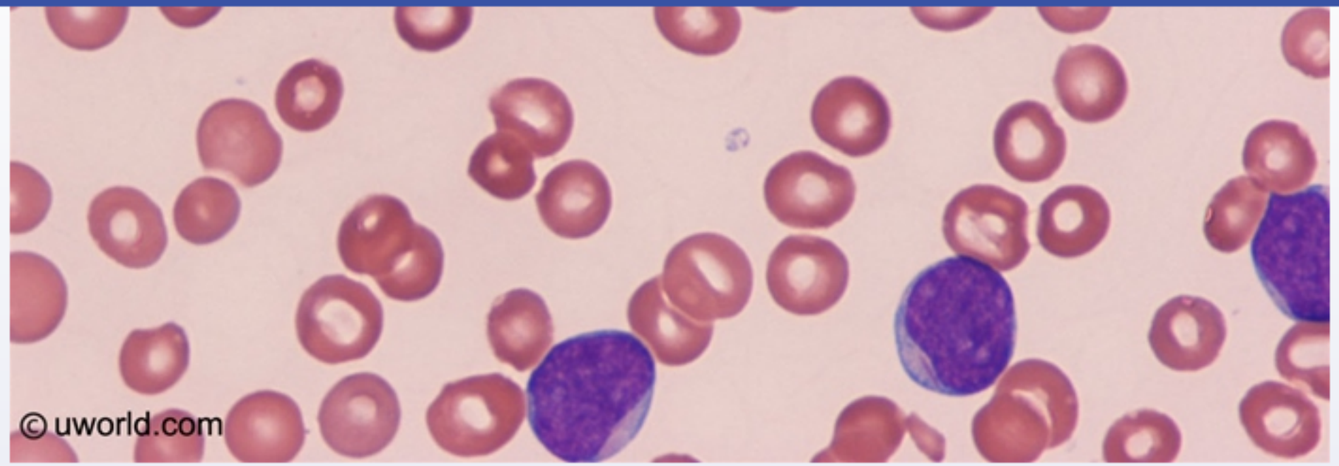

Which of the following is the most likely diagnosis?

- A. Acute lymphoblastic leukemia
- B. Acute myelogenous leukemia
- C. Chronic lymphocytic leukemia
- D. Chronic myelogenous leukemia
- E. Hairy cell leukemia
- F. Hodgkin lymphoma
- G. Infectious mononucleosis

Submit

1
2
3
4
5
6
7
8
9
10
11
12
13
14
15
16
17
18
19
20
21
22
23
24
25
26
27
28
29
30

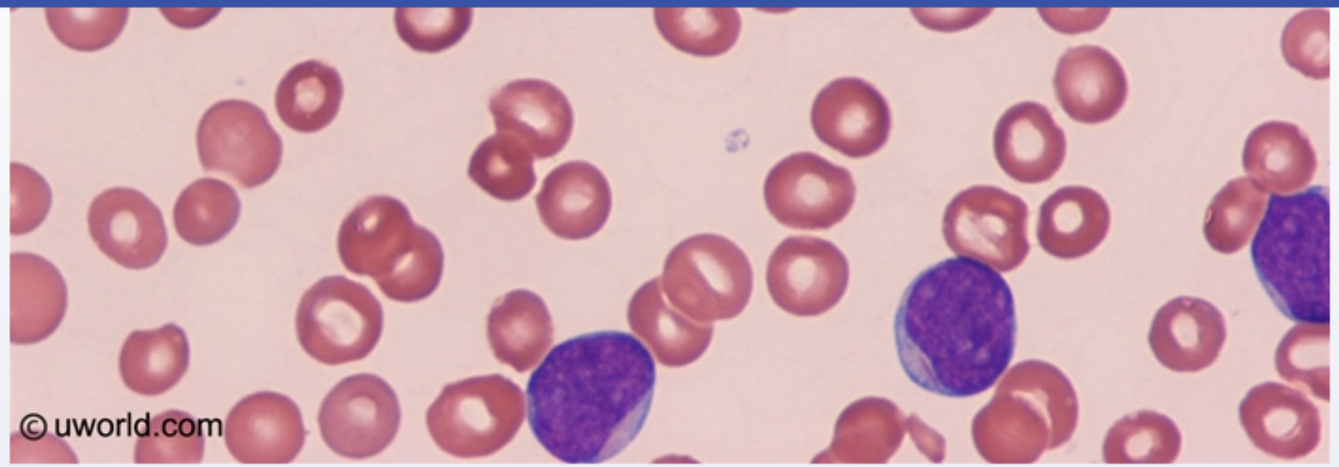

Which of the following is the most likely diagnosis?

- A. Acute lymphoblastic leukemia (6%)
- ✓ B. Acute myelogenous leukemia (51%)
- C. Chronic lymphocytic leukemia (18%)
- D. Chronic myelogenous leukemia (16%)
- E. Hairy cell leukemia (1%)
- F. Hodgkin lymphoma (3%)
- G. Infectious mononucleosis (2%)

Omitted
Correct answer

51%
Answered correctly

05 secs
Time Spent

06/06/2020
Last Updated

Acute myeloid leukemia without maturation

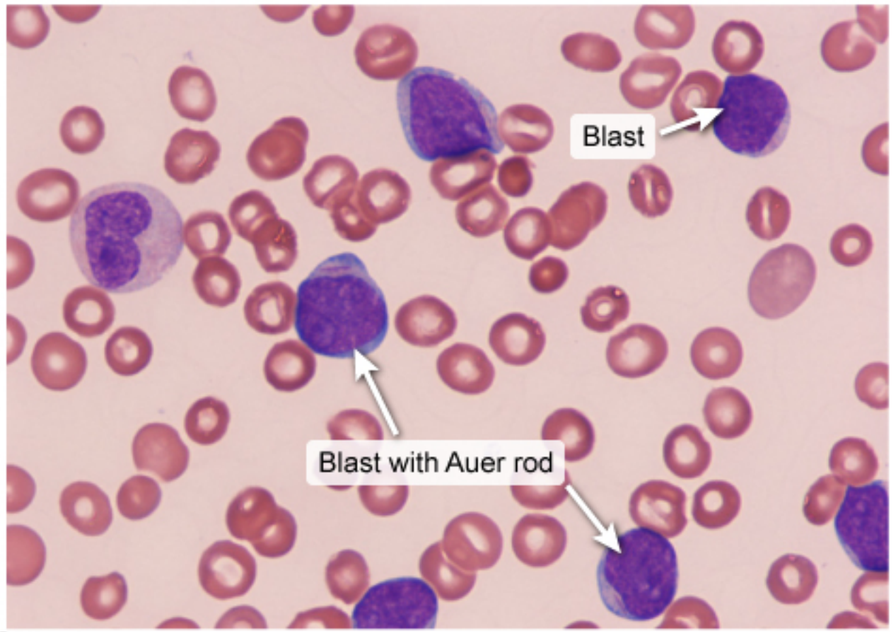

©UWorld

This patient's peripheral blood smear shows very large nucleated cells (see red cell size for comparison) with scant cytoplasm. These are **blast cells**, the finding of which makes acute leukemia likely. Closer examination of the smear reveals linear, purple-red inclusions in some of the cells, called **Auer rods**. These may be single or multiple within immature myeloid precursors. Auer rods are highly suggestive of **acute myelogenous leukemia (AML)** but not of acute lymphoblastic leukemia (ALL) **(Choice A)**. Although Auer rods are most commonly associated with the M1, M2, and M3 subtypes of AML, they may be found in any type of AML.

The vast majority of AML cases occur in adults, with a median age of 65. Most patients present with complications of pancytopenia (eg, fatigue from anemia, bruising/bleeding from thrombocytopenia, infection from possible functional neutropenia despite leukocytosis). The median white blood cell count is around 15,000/mm^3 at diagnosis. Current World Health Organization diagnostic criteria require the presence of ≥20% myeloblasts in the bone marrow.

This patient's peripheral blood smear shows very large nucleated cells (see red cell size for comparison) with scant cytoplasm. These are **blast cells**, the finding of which makes acute leukemia likely. Closer examination of the smear reveals linear, purple-red inclusions in some of the cells, called **Auer rods**. These may be single or multiple within immature myeloid precursors. Auer rods are highly suggestive of **acute myelogenous leukemia (AML)** but not of acute lymphoblastic leukemia (ALL) **(Choice A)**. Although Auer rods are most commonly associated with the M1, M2, and M3 subtypes of AML, they may be found in any type of AML.

The vast majority of AML cases occur in adults, with a median age of 65. Most patients present with complications of pancytopenia (eg, fatigue from anemia, bruising/bleeding from thrombocytopenia, infection from possible functional neutropenia despite leukocytosis). The median white blood cell count is around 15,000/mm^3 at diagnosis. Current World Health Organization diagnostic criteria require the presence of $\geq$20% myeloblasts in the bone marrow.

(Choices C and D) Chronic leukemia causes a prevalence of mature cells in the peripheral blood. In chronic myelogenous leukemia (CML), peripheral smears show many mature granulocytes and few blasts (generally <2%). In chronic lymphocytic leukemia (CLL), smears show many mature lymphocytes.

(Choice E) Patients with hairy cell leukemia have splenomegaly, cytopenias, and circulating hairy cells. On peripheral blood smear, hairy cells take the appearance of small- to medium-sized lymphoid cells with circumferential "hairy" projections.

(Choice F) Patients with Hodgkin lymphoma generally present with a mass (eg, mediastinal mass, enlarged lymph nodes). The finding of circulating neoplastic cells is extremely rare. Histologically, Reed-Sternberg cells are characteristic. These are large cells with an abundant basophilic cytoplasm and $\geq$2 nuclear lobes or nuclei.

(Choice G) Patients with infectious mononucleosis have fatigue, lymphadenopathy, and splenomegaly. Thrombocytopenia can be a complication of this infection. Peripheral blood smear will show few circulating atypical lymphocytes, but no blasts.

Educational objective:
The finding of Auer rods (linear purple-red inclusions within immature myeloid precursors) is helpful in making the diagnosis of acute myeloid leukemia. Auer rods are not found in acute lymphoblastic leukemia. In chronic myelogenous leukemia, there are more mature cells and fewer blasts.

and M3 subtypes of AML, they may be found in any type of AML.

The vast majority of AML cases occur in adults, with a median age of 65. Most patients present with complications of pancytopenia (eg, fatigue from anemia, bruising/bleeding from thrombocytopenia, infection from possible functional neutropenia despite leukocytosis). The median white blood cell count is around 15,000/mm^3 at diagnosis. Current World Health Organization diagnostic criteria require the presence of ≥20% myeloblasts in the bone marrow.

(Choices C and D) Chronic leukemia causes a prevalence of mature cells in the peripheral blood. In chronic myelogenous leukemia (CML), peripheral smears show many mature granulocytes and few blasts (generally <2%). In chronic lymphocytic leukemia (CLL), smears show many mature lymphocytes.

(Choice E) Patients with hairy cell leukemia have splenomegaly, cytopenias, and circulating hairy cells. On peripheral blood smear, hairy cells take the appearance of small- to medium-sized lymphoid cells with circumferential "hairy" projections.

(Choice F) Patients with Hodgkin lymphoma generally present with a mass (eg, mediastinal mass, enlarged lymph nodes). The finding of circulating neoplastic cells is extremely rare. Histologically, Reed-Sternberg cells are characteristic. These are large cells with an abundant basophilic cytoplasm and ≥2 nuclear lobes or nuclei.

(Choice G) Patients with infectious mononucleosis have fatigue, lymphadenopathy, and splenomegaly. Thrombocytopenia can be a complication of this infection. Peripheral blood smear will show few circulating atypical lymphocytes, but no blasts.

Educational objective:
The finding of Auer rods (linear purple-red inclusions within immature myeloid precursors) is helpful in making the diagnosis of acute myeloid leukemia. Auer rods are not found in acute lymphoblastic leukemia. In chronic myelogenous leukemia, there are more mature cells and fewer blasts.

Pathology	Hematology & Oncology	Acute myeloid leukemia
Subject	System	Topic

Copyright © UWorld. All rights reserved.

and M3 subtypes of AML, they may be found in any type of AML.

Exhibit Display

Hodgkin lymphoma

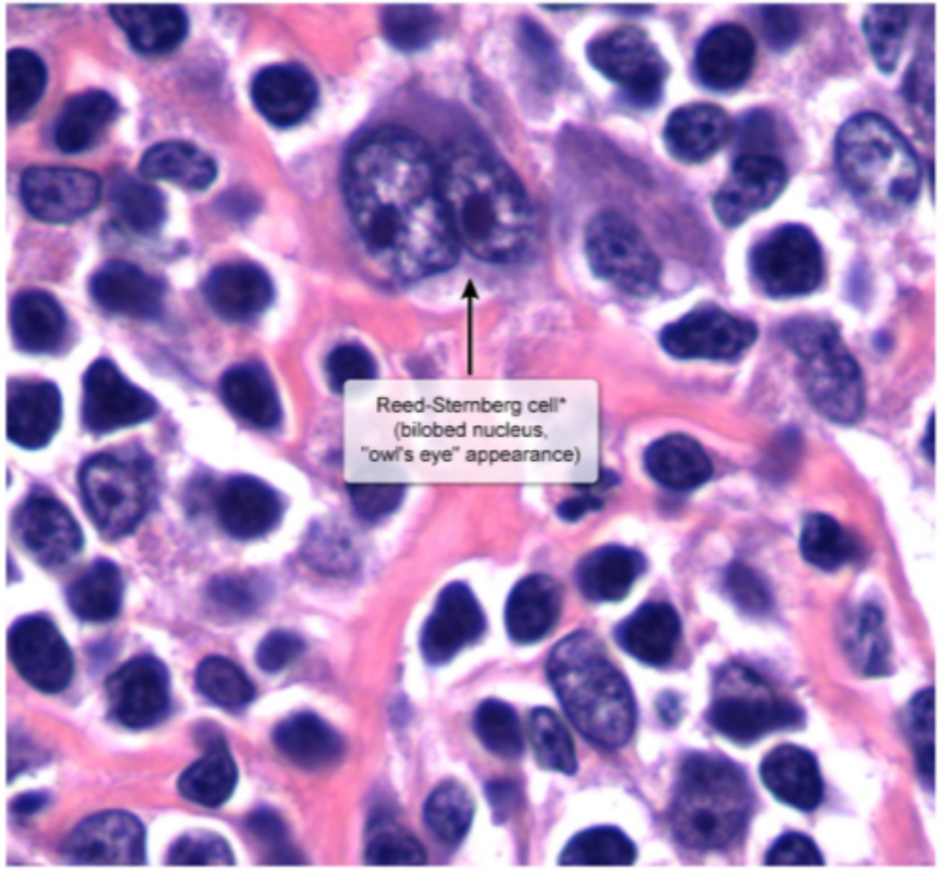

*Derived from CD 20/45 negative B cells

©UWorld

Zoom In | Zoom Out | Reset | Add To New Card | Existing Card

and M3 subtypes of AML, they may be found in any type of AML.

Exhibit Display

Atypical CD8+ T lymphocyte

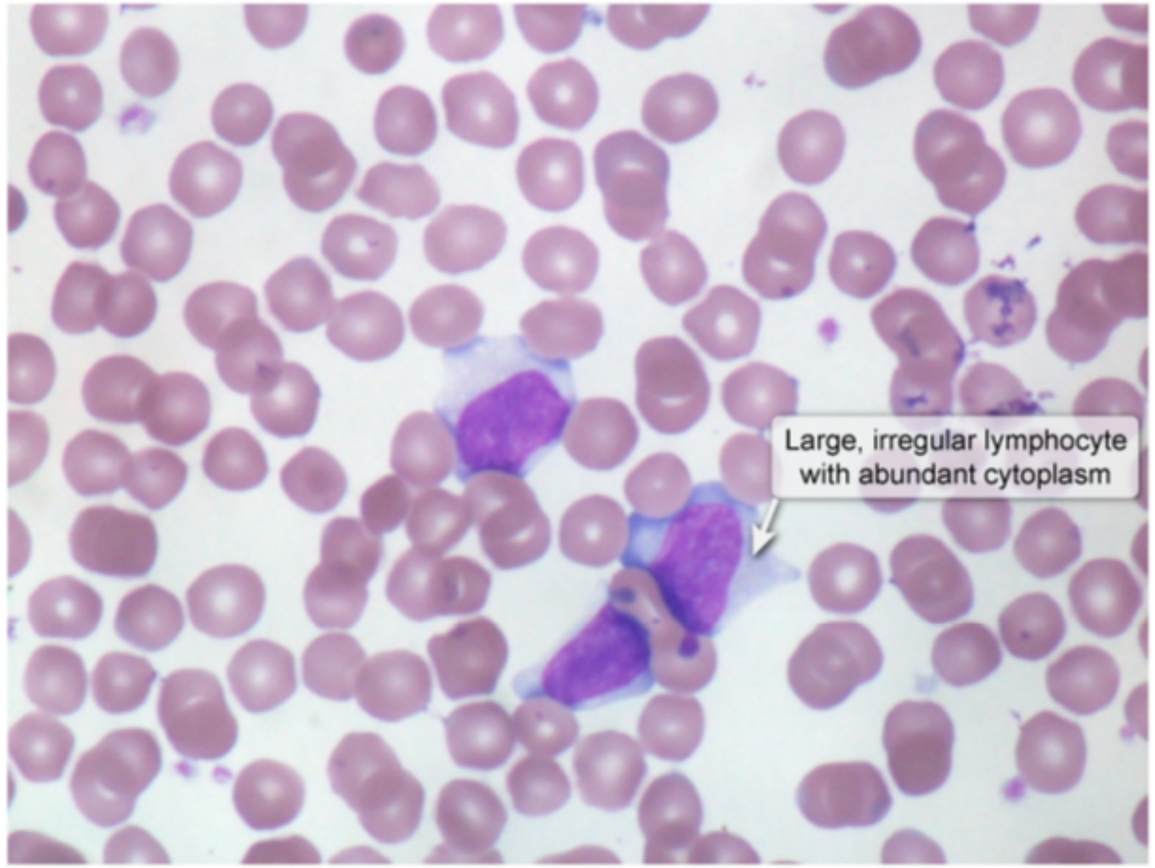

Zoom In | Zoom Out | Reset | Add To New Card | Existing Card

1
2
3
4
5
6
7
8
9
10
11
12
13
14
15
16
17
18
19
20
21
22
23
24
25
26
27
28
29
30

An external stimulus applied to a cell increases the activity of several enzymes, including dihydrofolate reductase and DNA polymerase. Which of the following immediately precedes the observed effect?

A. p27 protein upregulation

B. Retinoblastoma protein phosphorylation

C. Caspase enzyme cleavage

D. GDP binding to Ras protein

E. Protein kinase A phosphorylation

Submit

An external stimulus applied to a cell increases the activity of several enzymes, including dihydrofolate reductase and DNA polymerase. Which of the following immediately precedes the observed effect?

- A. p27 protein upregulation (5%)
- ✓ B. Retinoblastoma protein phosphorylation (44%)
- C. Caspase enzyme cleavage (6%)
- D. GDP binding to Ras protein (20%)
- E. Protein kinase A phosphorylation (23%)

Omitted
Correct answer
B

44%
Answered correctly

02 secs
Time Spent

02/03/2020
Last Updated

Explanation

An increase in the activity of enzymes responsible for DNA synthesis signifies that the cell is in the S phase of the cell cycle. The transition from G1 to S phase is one of the two primary cell cycle checkpoints that ensure "quality control" of the DNA. Cells with damaged DNA are not allowed to enter the S phase.

Retinoblastoma (Rb) protein is a regulator of the G1→S phase transition. The Rb protein is present in one of two forms: active (hypophosphorylated) or inactive (hyperphosphorylated). The resting cells in the G0 phase contain active (hypophosphorylated) Rb protein.

1. When the cell is stimulated by growth factor, activation of cyclin D, cyclin E and the corresponding cyclin kinases (CDK 4 and 6) occurs and

1 2 3 4 5 6 7 8 9 10 11 12 13 14 15 16 17 18 19 20 21 22 23 24 25 26 27 28 29 30

An increase in the activity of enzymes responsible for DNA synthesis signifies that the cell is in the S phase of the cell cycle. The transition from G1 to S phase is one of the two primary cell cycle checkpoints that ensure "quality control" of the DNA. Cells with damaged DNA are not allowed to enter the S phase.

Retinoblastoma (Rb) protein is a regulator of the G1→S phase transition. The Rb protein is present in one of two forms: active (hypophosphorylated) or inactive (hyperphosphorylated). The resting cells in the G0 phase contain active (hypophosphorylated) Rb protein.

1. When the cell is stimulated by growth factor, activation of cyclin D, cyclin E and the corresponding cyclin kinases (CDK 4 and 6) occurs and the Rb protein is hyperphosphorylated (rendering it inactive). Hyperphosphorylated Rb releases E2F transcription factor, which allows the cell to progress through the G1→S checkpoint.
2. If the Rb protein is hypophosphorylated (active), it binds to the E2F transcription factor. This complex inhibits the transcription of genes necessary for G1→S transition. Active Rb protein, therefore, serves as a "brake" that stops the cell from dividing.

(Choice A) The p27 protein is a cell cycle inhibitor. It acts during G1 phase by inhibiting cyclin-dependent kinases. Normal tissues contain high levels of p27, while malignant tissues contain very low levels of p27. Upregulation of p27 would stop the cell cycle.

(Choice C) Caspases are cysteine proteases, enzymes essential for apoptosis. Caspases are not associated with the G1→S transition in the cell cycle.

(Choice D) Ras protein is a component of the MAP-kinase signal transduction system. It transmits the stimulus from the receptor on the cell surface into the nucleus. Ras protein is not associated with the G1→S transition in the cell cycle.

(Choice E) Protein kinase A is a component of the cAMP signaling system. It is not associated with the G1→S transition in the cell cycle.

Educational Objective:
Proliferation signals activate CDK4 (cyclin-dependent kinase-4), resulting in hyperphosphorylation of the Rb protein. Because hyperphosphorylated Rb is inactive, cells are allowed to transition unchecked from the G1 phase to the S phase in the cell cycle.

Pathology	Hematology & Oncology	Cell cycle
Subject	System	Topic

G1 to S phase is one of the two primary cell cycle checkpoints that ensure "quality control" of the DNA. Cells with damaged DNA are not allowed to enter the S phase.

Retinoblastoma (Rb) protein is a regulator of the G1→S phase transition. The Rb protein is present in one of two forms: active (hypophosphorylated) or inactive (hyperphosphorylated). The resting cells in the G0 phase contain active (hypophosphorylated) Rb protein.

1. When the cell is stimulated by growth factor, activation of cyclin D, cyclin E and the corresponding cyclin kinases (CDK 4 and 6) occurs and the Rb protein is hyperphosphorylated (rendering it inactive). Hyperphosphorylated Rb releases E2F transcription factor, which allows the cell to progress through the G1→S checkpoint.
2. If the Rb protein is hypophosphorylated (active), it binds to the E2F transcription factor. This complex inhibits the transcription of genes necessary for G1→S transition. Active Rb protein, therefore, serves as a "brake" that stops the cell from dividing.

(Choice A) The p27 protein is a cell cycle inhibitor. It acts during G1 phase by inhibiting cyclin-dependent kinases. Normal tissues contain high levels of p27, while malignant tissues contain very low levels of p27. Upregulation of p27 would stop the cell cycle.

(Choice C) Caspases are cysteine proteases, enzymes essential for apoptosis. Caspases are not associated with the G1→S transition in the cell cycle.

(Choice D) Ras protein is a component of the MAP-kinase signal transduction system. It transmits the stimulus from the receptor on the cell surface into the nucleus. Ras protein is not associated with the G1→S transition in the cell cycle.

(Choice E) Protein kinase A is a component of the cAMP signaling system. It is not associated with the G1→S transition in the cell cycle.

Educational Objective:
Proliferation signals activate CDK4 (cyclin-dependent kinase-4), resulting in hyperphosphorylation of the Rb protein. Because hyperphosphorylated Rb is inactive, cells are allowed to transition unchecked from the G1 phase to the S phase in the cell cycle.

Pathology	Hematology & Oncology	Cell cycle
Subject	System	Topic

Copyright © UWorld. All rights reserved.

1 2 3 4 5 6 7 8 9 10 11 12 13 14 15 16 17 18 19 20 21 22 23 24 25 26 27 28 29 30

1
2
3
4
5
6
7
8
9
10
11
12
13
14
15
16
17
18
19
20
21
22
23
24
25
26
27
28
29
30

A 9-year-old boy with beta thalassemia major comes to the office for a routine red blood cell transfusion. He was diagnosed at age 6 months and has since received numerous blood transfusions and chelation therapies. The patient has tolerated each transfusion and chelation therapy well with no immediate reactions or side effects. Vital signs are normal. On physical examination, the boy has mild frontal bossing, hepatosplenomegaly, and jaundice. A recent liver biopsy showed Kupffer cells containing coarse, yellowish-brown cytoplasmic granules. The granules are most likely composed of which of the following?

A. Amyloid
B. Bilirubin
C. Copper
D. Glycogen
E. Glycolipid
F. Hemosiderin
G. Lipofuscin

Submit

A 9-year-old boy with beta thalassemia major comes to the office for a routine red blood cell transfusion. He was diagnosed at age 6 months and has since received numerous blood transfusions and chelation therapies. The patient has tolerated each transfusion and chelation therapy well with no immediate reactions or side effects. Vital signs are normal. On physical examination, the boy has mild frontal bossing, hepatosplenomegaly, and jaundice. A recent liver biopsy showed Kupffer cells containing coarse, yellowish-brown cytoplasmic granules. The granules are most likely composed of which of the following?

- A. Amyloid (0%)
- B. Bilirubin (7%)
- C. Copper (2%)
- D. Glycogen (0%)
- E. Glycolipid (0%)
- ✓ F. Hemosiderin (80%)
- G. Lipofuscin (7%)

Omitted
Correct answer
F

80%
Answered correctly

01 sec
Time Spent

04/13/2020
Last Updated

Explanation

Patients with **chronic hemolytic anemia** (eg, beta thalassemia major) depend on recurrent **red blood cell (RBC) transfusions** to maintain an adequate hemoglobin level. **Iron overload (hemosiderosis)** from increased iron absorption is a common complication resulting from both the

Patients with **chronic hemolytic anemia** (eg, beta thalassemia major) depend on recurrent **red blood cell (RBC) transfusions** to maintain an adequate hemoglobin level. **Iron overload (hemosiderosis)** from increased iron absorption is a common complication resulting from both the primary condition (eg, hemolysis) and its treatment (frequent RBC transfusions).

Circulating iron is carried by transferrin. Once deposited in cells, iron binds to apoferritin to form ferritin micelles. Because iron is utilized poorly in patients with thalassemia and cannot be excreted actively, the ferritin micelles accumulate in macrophages of the reticuloendothelial system. The resulting iron-storage complex is known as **hemosiderin** and microscopically appears as **brown or yellowish-brown pigments** in either granular or crystalline form. Hemosiderin can be identified histologically with a Prussian-blue stain. In the liver, hemosiderin is typically seen in **Kupffer cells** (hepatic macrophages that line the walls of the sinusoids and participate in RBC breakdown).

Patients receiving regular transfusions should undergo routine iron **chelation therapy** to reduce the overall iron load within the body and improve survival. Eventually, the iron burden will overwhelm the reticuloendothelial cells' capacity to sequester iron, resulting in parenchymal iron overload in the liver, myocardium, skin, and pancreas (eg, "bronze diabetes").

(Choice A) Amyloid protein has a pale rose color after Congo red staining. Accumulation of amyloid fibrils can result in a variety of sequelae (eg, cardiomyopathy, nephrotic syndrome).

(Choice B) Bilirubin is the primary pigment found within bile and is a byproduct of hemoglobin breakdown. Hemolytic anemia commonly results in indirect hyperbilirubinemia and jaundice.

(Choice C) Copper accumulation is seen in Wilson disease, an autosomal recessive disease characterized by cirrhosis and neurologic complications.

(Choice D) Glycogen appears as clear cytoplasmic vacuoles and stains pinkish purple with the periodic acid-Schiff reaction. Glycogen is abundant in the liver shortly after a meal.

(Choice E) Patients with Gaucher disease (glucocerebrosidase enzyme deficiency) have pancytopenia, hepatosplenomegaly, and pathologic fractures. The cardinal histologic finding are Gaucher cells (black arrows), which are macrophages laden with cerebrosides and other glycolipids.

(Choice G) Lipofuscin is an insoluble yellow-brown pigment composed of lipids and phospholipids complexed with proteins. This pigment accumulates with age and "wear and tear" of multiple organs.

Exhibit Display

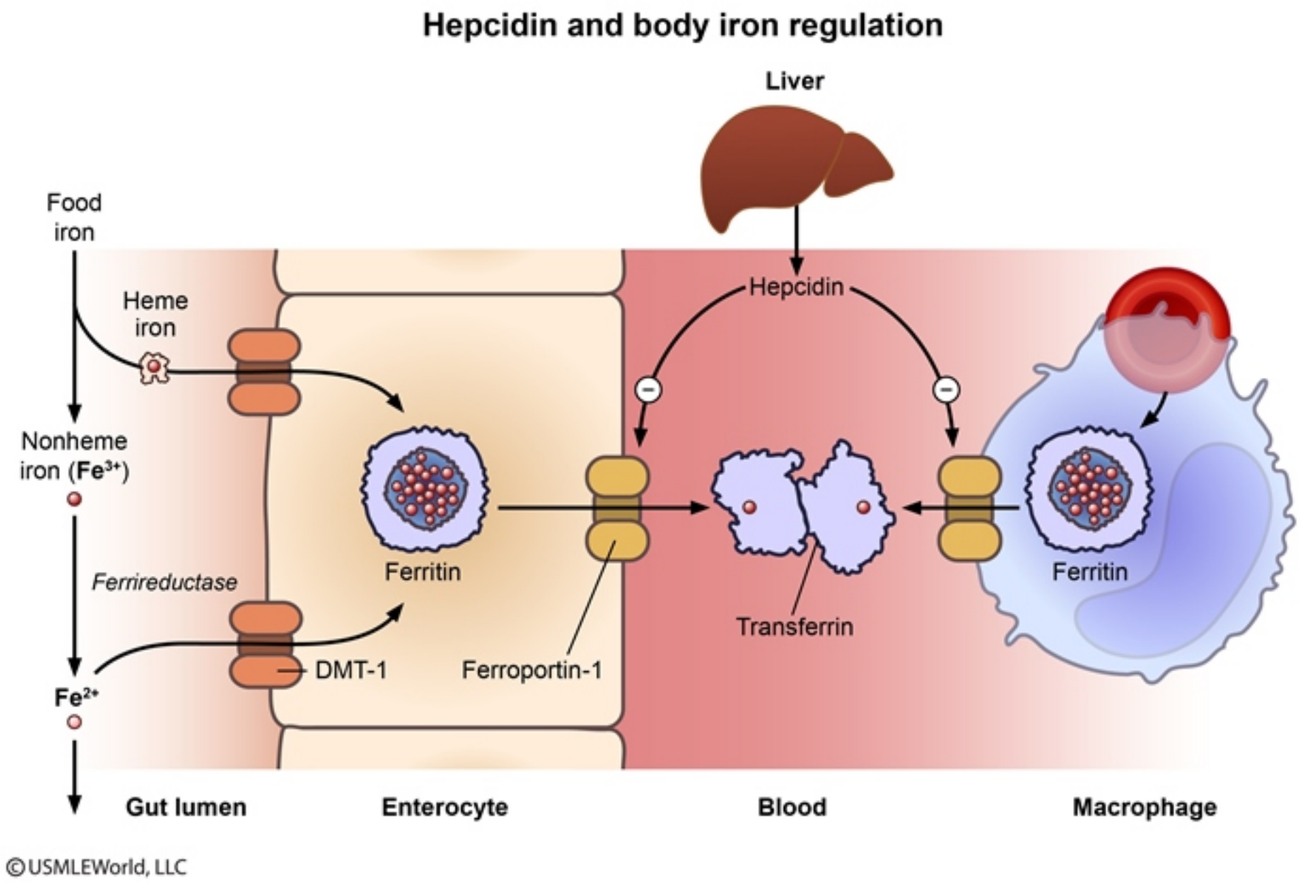

Zoom In | Zoom Out | Reset | Add To New Card | Existing Card

accumulates with age and "wear and tear" of multiple organs

1
2
3
4
5
6
7
8
9
10
11
12
13
14
15
16
17
18
19
20
21
22
23
24
25
26
27
28
29
30

Exhibit Display

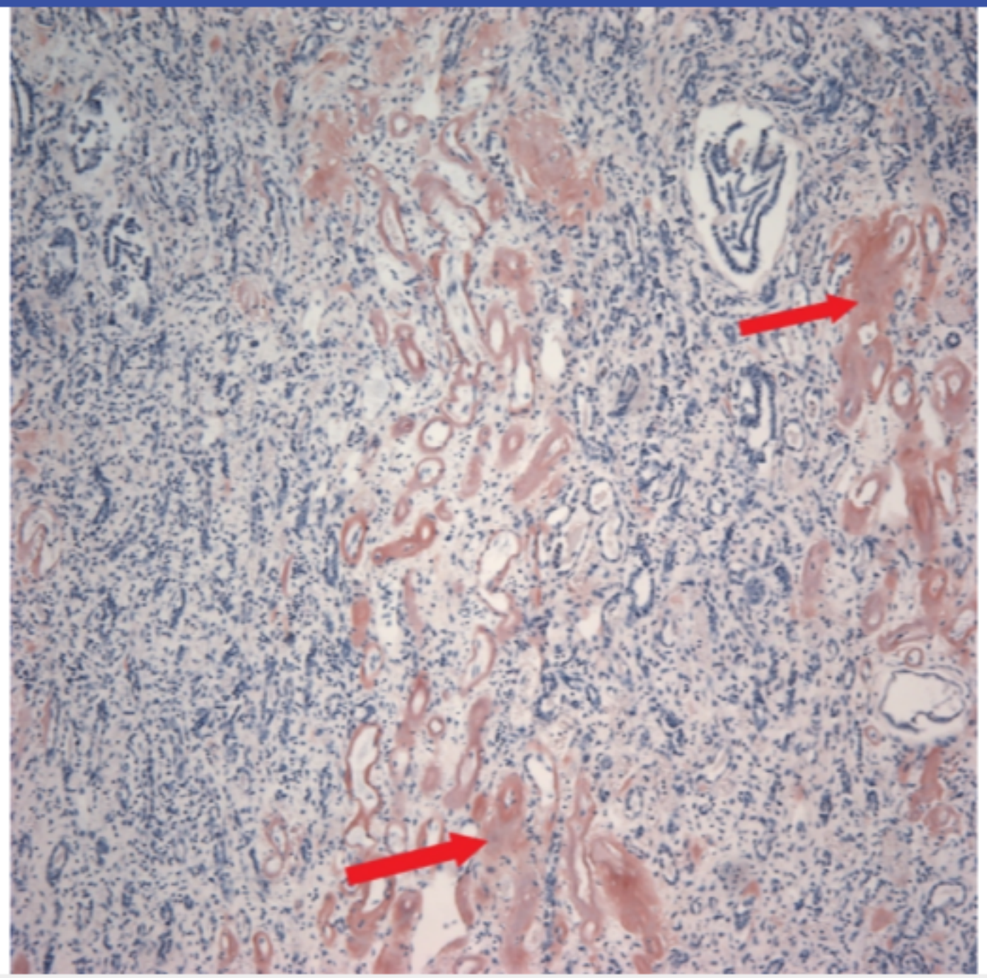

Zoom In | Zoom Out | Reset | Add To New Card | Existing Card

accumulates with age and "wear and tear" of multiple organs

(Choice A) Amyloid protein has a pale rose color after Congo red staining. Accumulation of amyloid fibrils can result in a variety of sequelae (eg, cardiomyopathy, nephrotic syndrome).

(Choice B) Bilirubin is the primary pigment found within bile and is a byproduct of hemoglobin breakdown. Hemolytic anemia commonly results in indirect hyperbilirubinemia and jaundice.

(Choice C) Copper accumulation is seen in Wilson disease, an autosomal recessive disease characterized by cirrhosis and neurologic complications.

(Choice D) Glycogen appears as clear cytoplasmic vacuoles and stains pinkish purple with the periodic acid-Schiff reaction. Glycogen is abundant in the liver shortly after a meal.

(Choice E) Patients with Gaucher disease (glucocerebrosidase enzyme deficiency) have pancytopenia, hepatosplenomegaly, and pathologic fractures. The cardinal histologic finding are Gaucher cells (black arrows), which are macrophages laden with cerebrosides and other glycolipids.

(Choice G) Lipofuscin is an insoluble yellow-brown pigment composed of lipids and phospholipids complexed with proteins. This pigment accumulates with age and "wear and tear" of multiple organs.

Educational objective:
Iron overload (hemosiderosis) is a common and serious complication of chronic hemolytic anemia and frequent blood transfusions. Hemosiderin accumulation is the cardinal histologic finding. Chelation therapy is indicated to reduce parenchymal iron deposition.

References

- Iron overload syndromes and the liver.
- Iron overload in Beta thalassaemia major and intermedia patients.

Pathology	Hematology & Oncology	Hemolytic anemia
Subject	System	Topic

Copyright © UWorld. All rights reserved.

(Choice A) Amyloid protein has a pale rose color after Congo red staining. Accumulation of amyloid fibrils can result in a variety of sequelae (eg,

Exhibit Display

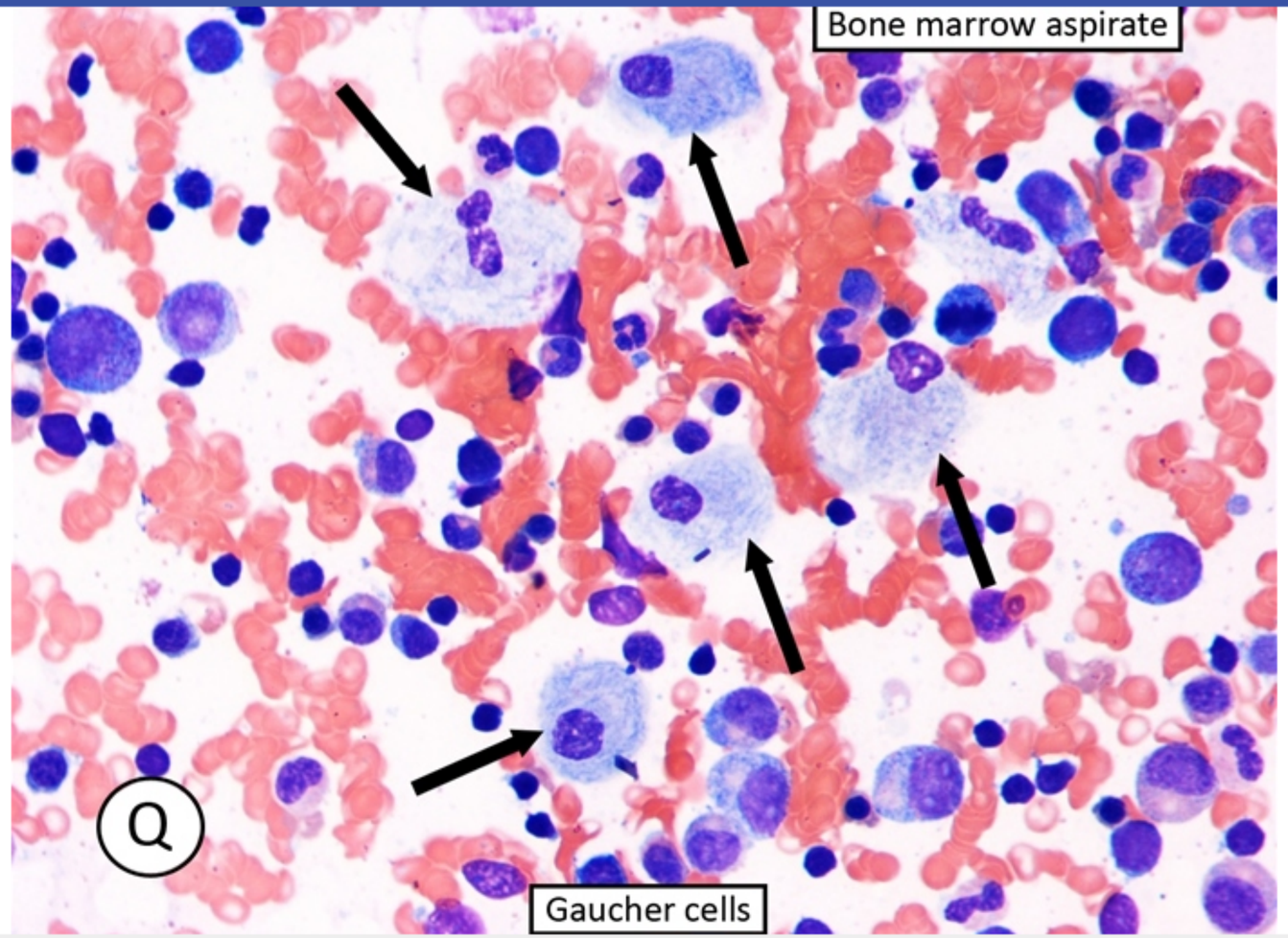

Zoom In | Zoom Out | Reset | Add To New Card | Existing Card

(Choice A) Amyloid protein has a pale rose color after Congo red staining. Accumulation of amyloid fibrils can result in a variety of sequelae (eg,

Exhibit Display

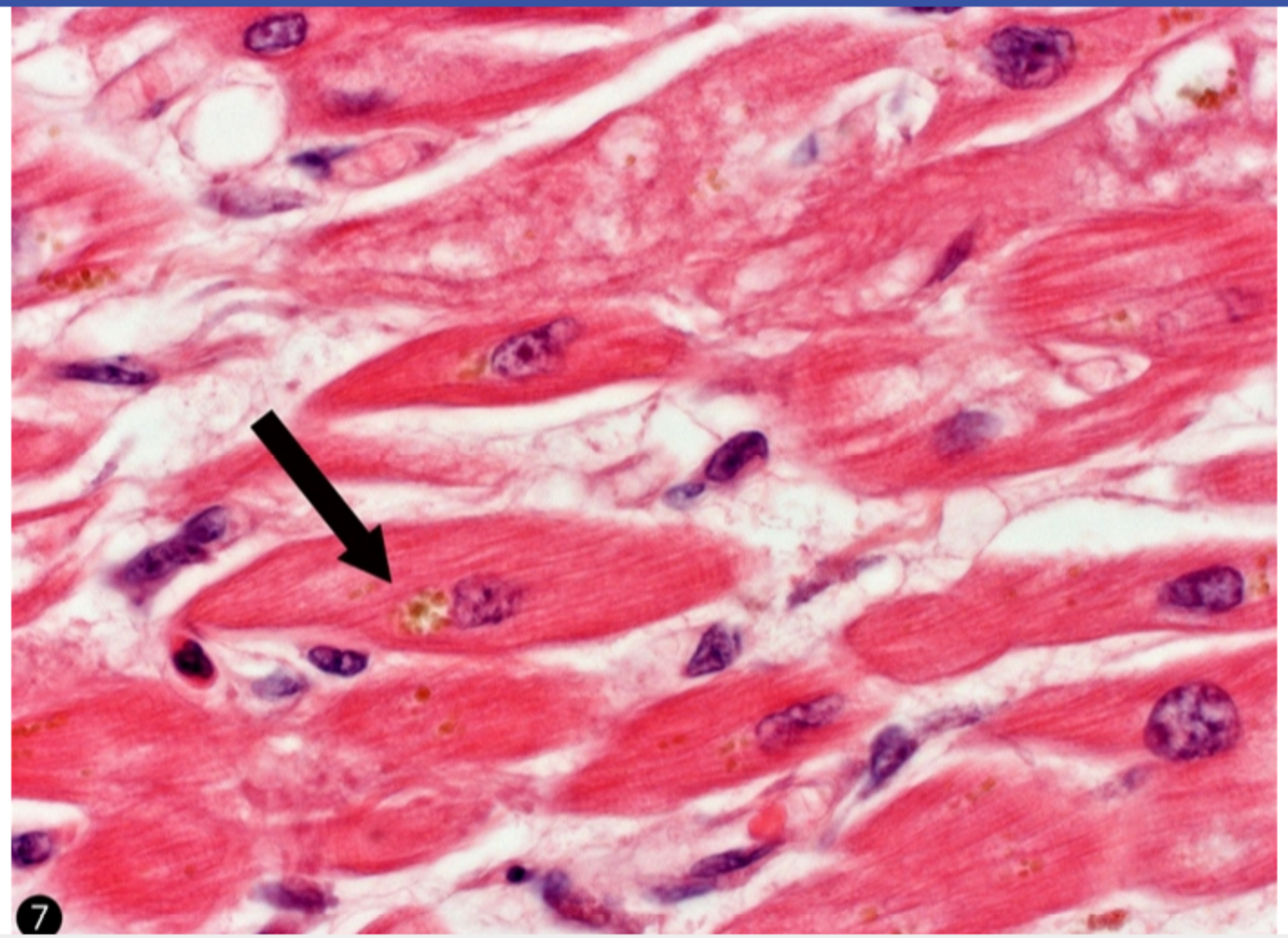

Zoom In Zoom Out Reset Add To New Card | Existing Card

7
8
9
10
11
12
13
14
15
16
17
18
19
20
21
22
23
24
25
26
27
28
29
30
31
32
33
34
35
36

A 6-year-old boy is brought to the office for fatigue and abdominal distension. His parents also say that the patient bruises easily and appears pale. Physical examination reveals subconjunctival pallor and several ecchymoses on the boy's extremities. His abdomen is distended with nontender massive splenomegaly and moderate hepatomegaly. Laboratory studies show that his hemoglobin level is 8 g/dL, leukocyte count is 3,800 cells/mm^3, and platelet count is 90,000 cells/mm^3. Bone marrow aspirate results are shown in the exhibit. Which of the following is the most likely diagnosis?

A. Acute lymphoblastic leukemia

B. Epstein-Barr virus

C. Fanconi anemia

D. Gaucher disease

E. Parvovirus B19

Submit

7
8
9
10
11
12
13
14
15
16
17
18
19
20
21
22
23
24
25
26
27
28
29
30
31
32
33
34
35
36

A 6-year-old boy is brought to the office for fatigue and abdominal distension. His parents also say that the patient bruises easily and appears pale. Physical examination reveals subconjunctival pallor and several ecchymoses on the boy's extremities. His abdomen is distended with nontender massive splenomegaly and moderate hepatomegaly. Laboratory studies show that his hemoglobin level is 8 g/dL, leukocyte count is 3,800 cells/mm^3, and platelet count is 90,000 cells/mm^3. Bone marrow aspirate results are shown in the exhibit. Which of the following is the most likely diagnosis?

A. Acute lymphoblastic leukemia (35%)
B. Epstein-Barr virus (5%)
C. Fanconi anemia (10%)
✓ D. Gaucher disease (35%)
E. Parvovirus B19 (12%)

Omitted
Correct answer
D

35%
Answered correctly

02 secs
Time Spent

01/27/2020
Last Updated

Explanation

Gaucher disease is the most prevalent genetic disorder among Ashkenazi Jews. This **autosomal recessive** lysosomal storage disorder is caused by **β-glucocerebrosidase deficiency**. This deficiency leads to accumulation of glucocerebroside, a glycolipid component of leukocyte and erythrocyte membranes. The **lipid-laden macrophages** (or **Gaucher cells**) are classically described as "wrinkled tissue paper," "wrinkled silk," or "crumpled newspaper" in a bone marrow aspirate (black arrows). These cells are found throughout the body in sites such as the liver, bone marrow, and lymphatic tissue (eg, spleen, lymph nodes, tonsils).

7 8 9 10 11 12 13 14 15 16 17 18 19 20 21 22 23 24 25 26 27 28 29 30 31 32 33 34 35 36

Gaucher disease is the most prevalent genetic disorder among Ashkenazi Jews. This **autosomal recessive** lysosomal storage disorder is caused by **β-glucocerebrosidase deficiency**. This deficiency leads to accumulation of glucocerebroside, a glycolipid component of leukocyte and erythrocyte membranes. The **lipid-laden macrophages** (or **Gaucher cells**) are classically described as "wrinkled tissue paper," "wrinkled silk," or "crumpled newspaper" in a bone marrow aspirate (black arrows). These cells are found throughout the body in sites such as the liver, bone marrow, and lymphatic tissue (eg, spleen, lymph nodes, tonsils).

The onset of symptoms varies from childhood to early adulthood. The typical presentation of Gaucher disease includes bone pain due to bone marrow invasion/inflammation, abdominal distension due to **hepatosplenomegaly**, and easy bleeding and bruising, pallor, and fatigue due to **pancytopenia**. Splenic enlargement usually develops prior to hepatic enlargement and can be massive. Anemia and thrombocytopenia are more common than leukopenia, but all 3 can be present concomitantly.

(Choice A) Acute lymphoblastic leukemia (ALL) is one of the most common childhood cancers. ALL can present with pancytopenia and hepatosplenomegaly; however, bone marrow or peripheral blood will reveal blasts. Patients may also have systemic signs and symptoms (eg, fever, lymphadenopathy).

(Choice B) Epstein-Barr virus (EBV) infection can be asymptomatic, cause infectious mononucleosis (IM), or contribute to malignancy (eg, Burkitt lymphoma). EBV most commonly causes IM and presents with fever, pharyngitis, cervical lymphadenopathy, fatigue, and splenomegaly. Atypical lymphocytes are found on peripheral blood smear.

(Choice C) Fanconi anemia is an inherited cause of aplastic anemia. In addition to pancytopenia, patients have an increased risk of malignancy (eg, acute myeloid leukemia) and often have hypo/hyperpigmented patches, short stature, and hypoplastic thumbs.

(Choice E) Parvovirus B19, a common cause of erythema infectiosum, can trigger a transient aplastic crisis in those with an underlying hematologic abnormality (eg, sickle cell disease, hereditary spherocytosis).

Educational objective:
Gaucher disease is an autosomal recessive lysosomal storage disorder that is characterized by β-glucocerebrosidase deficiency and presents with pancytopenia and hepatosplenomegaly. Glucocerebroside accumulation leads to distended macrophages with a "wrinkled tissue paper" appearance, also known as Gaucher cells.

References

Gaucher disease is the most prevalent genetic disorder among Ashkenazi Jews. This **autosomal recessive** lysosomal storage disorder is

Exhibit Display

Gaucher's disease Gaucher's disease

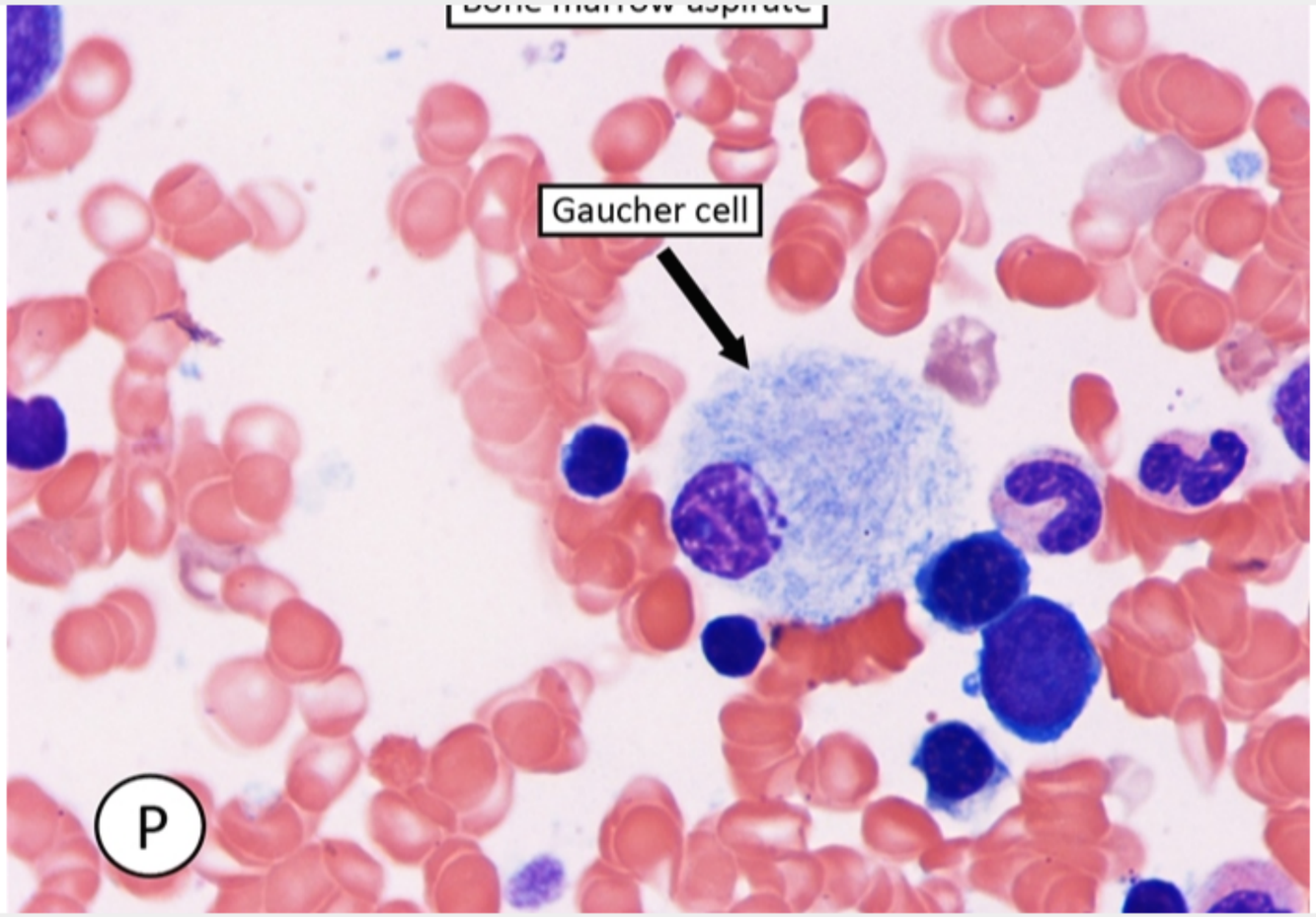

Zoom In Zoom Out Reset Add To New Card | Existing Card

References

Gaucher disease is the most prevalent genetic disorder among Ashkenazi Jews. This **autosomal recessive** lysosomal storage disorder is

Exhibit Display

Gaucher's disease Gaucher's disease

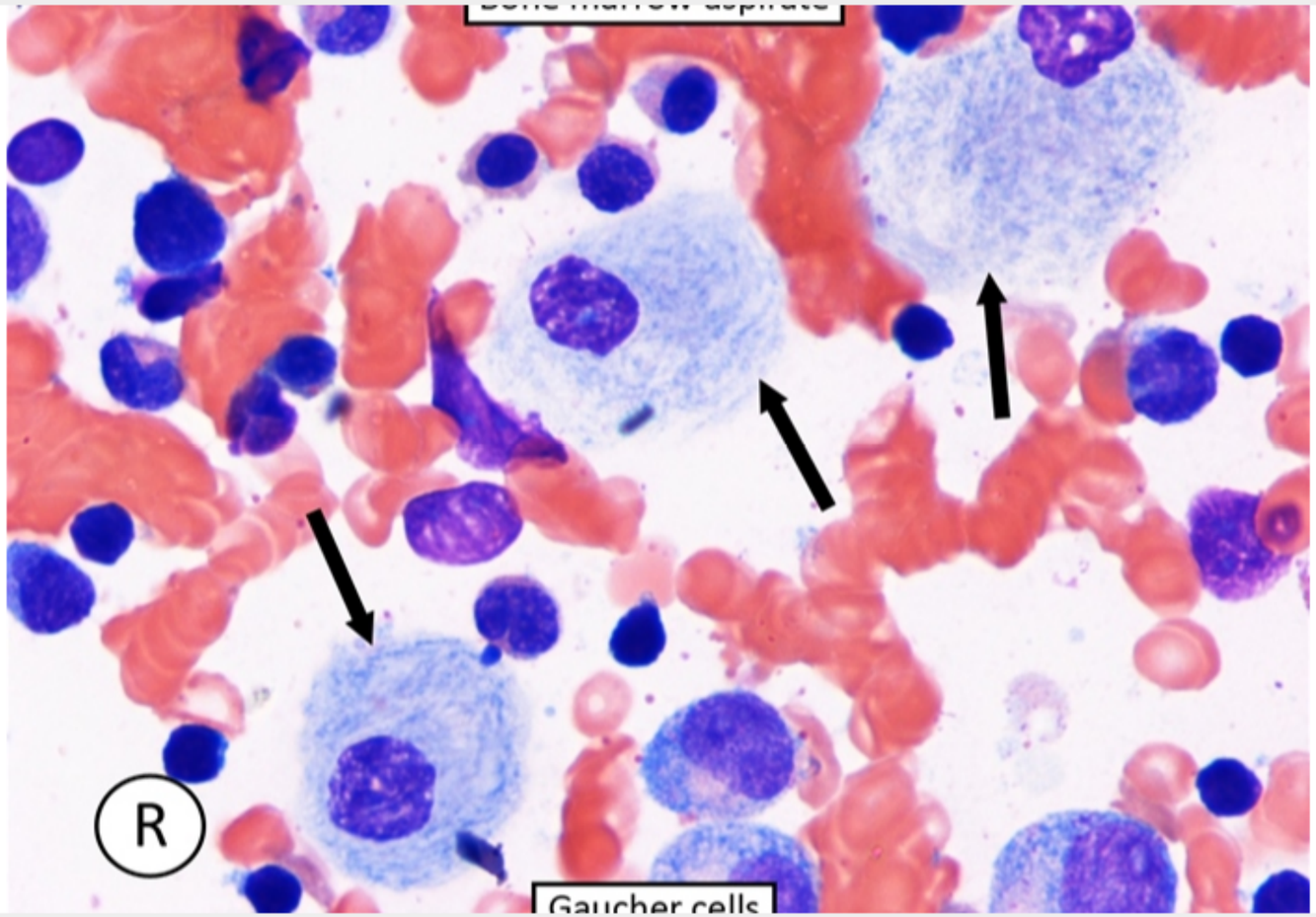

Zoom In Zoom Out Reset Add To New Card | Existing Card

References

Gaucher disease is the most prevalent genetic disorder among Ashkenazi Jews. This **autosomal recessive** lysosomal storage disorder is

Exhibit Display

Gaucher's disease Gaucher's disease

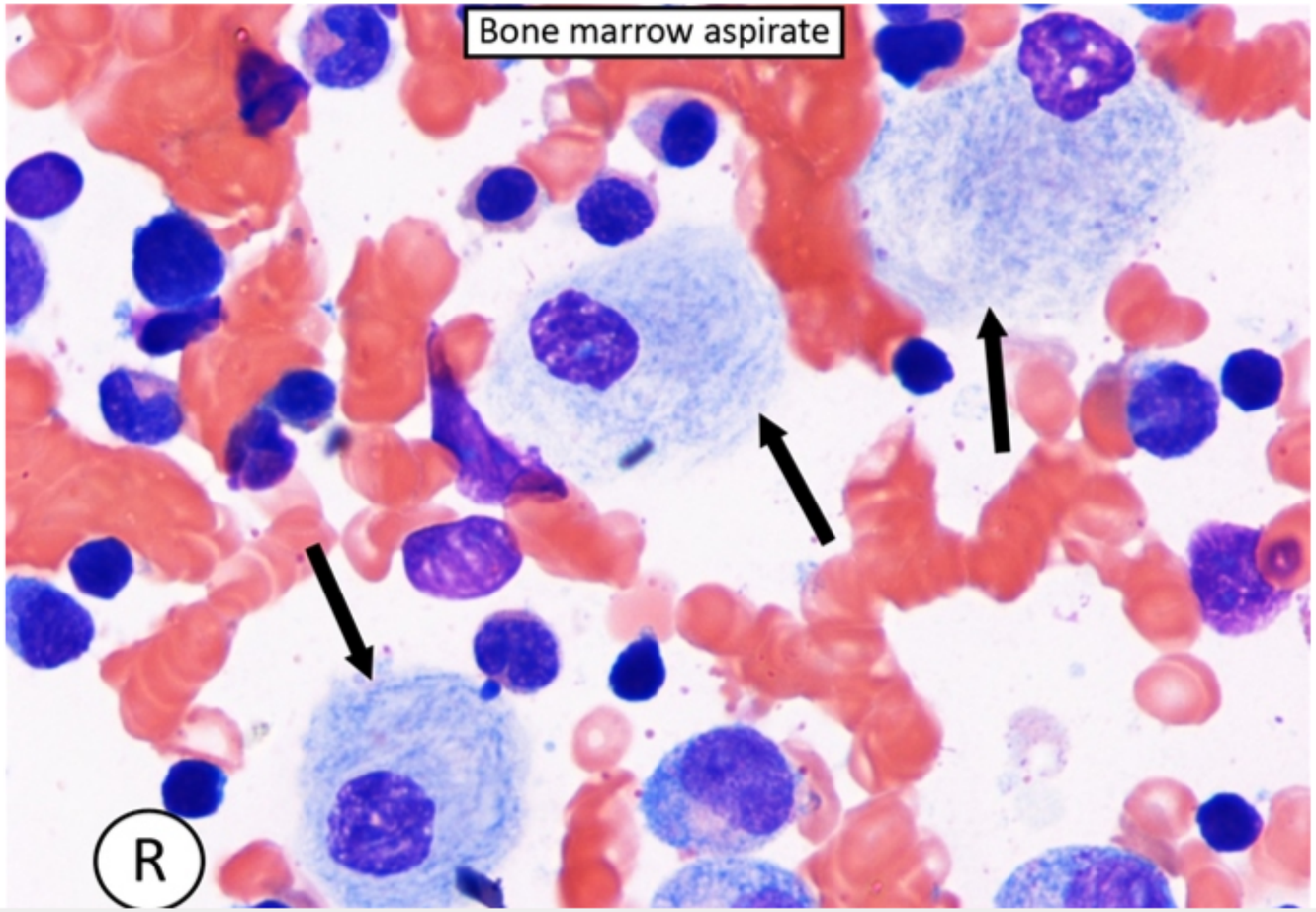

Zoom In Zoom Out Reset Add To New Card | Existing Card

References

7
8
9
10
11
12
13
14
15
16
17
18
19
20
21
22
23
24
25
26
27
28
29
30
31
32
33
34
35
36

A 15-year-old previously healthy patient arrives at the emergency department due to progressive shortness of breath. Chest x-ray shows a large mediastinal mass and bilateral pleural effusions. Leukocyte count is elevated, and peripheral blood smear reveals abnormal white blood cells, as shown below. These cells are positive for terminal deoxynucleotidyl transferase and CD3 and negative for CD19. Which of the following is the most likely diagnosis?

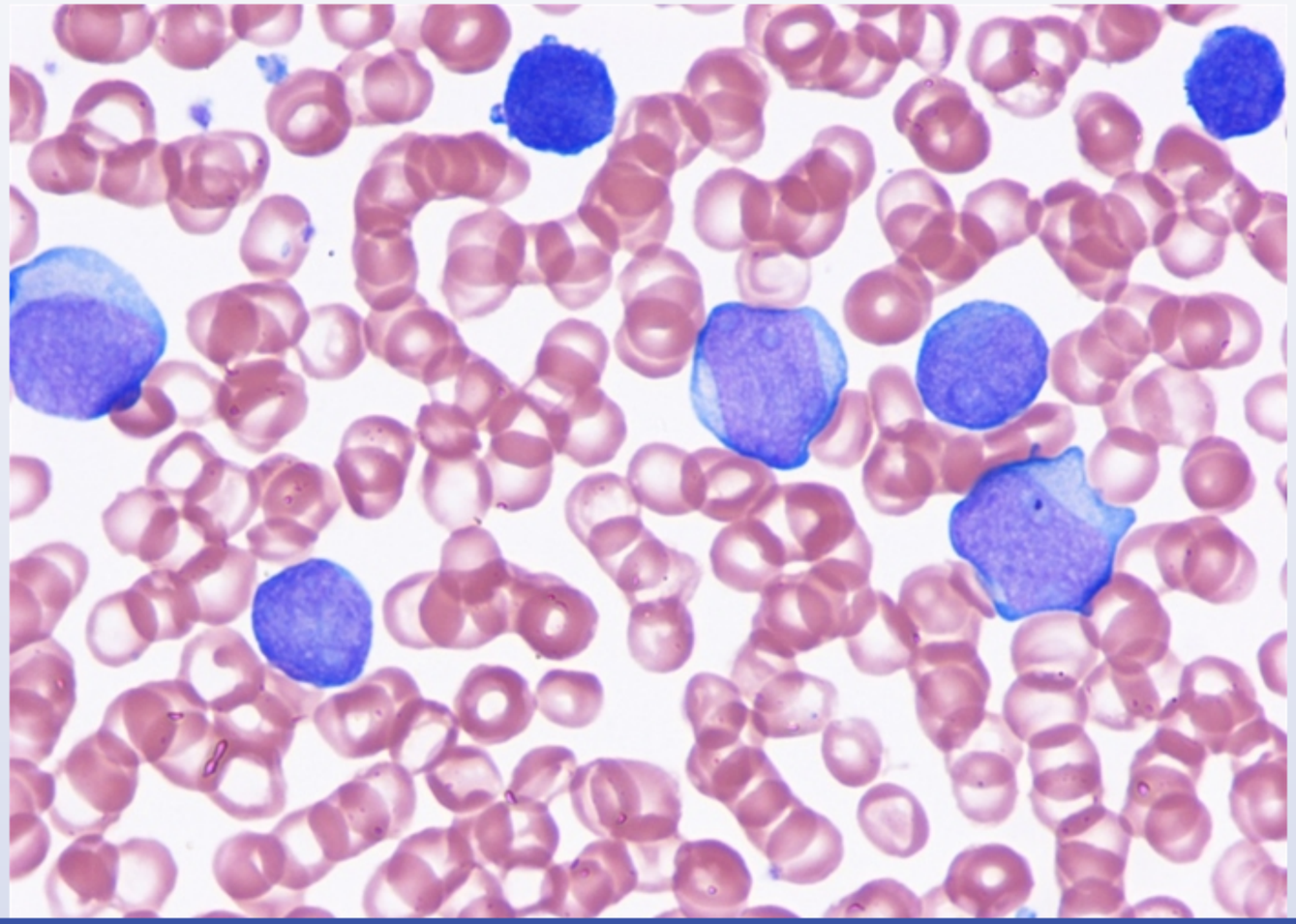

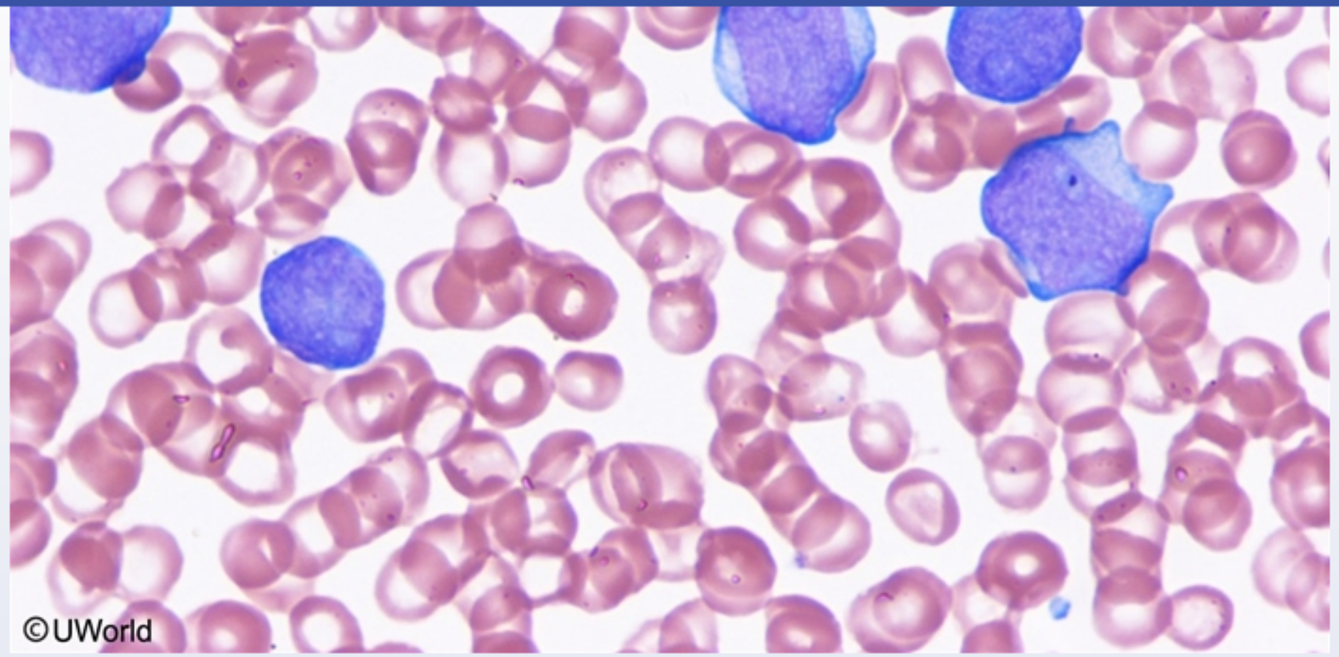

A. Acute lymphoblastic leukemia

B. Acute myeloid leukemia

C. Burkitt lymphoma

D. Hodgkin lymphoma

E. Mantle cell lymphoma

Submit

7
8
9
10
11
12
13
14
15
16
17
18
19
20
21
22
23
24
25
26
27
28
29
30
31
32
33
34
35
36

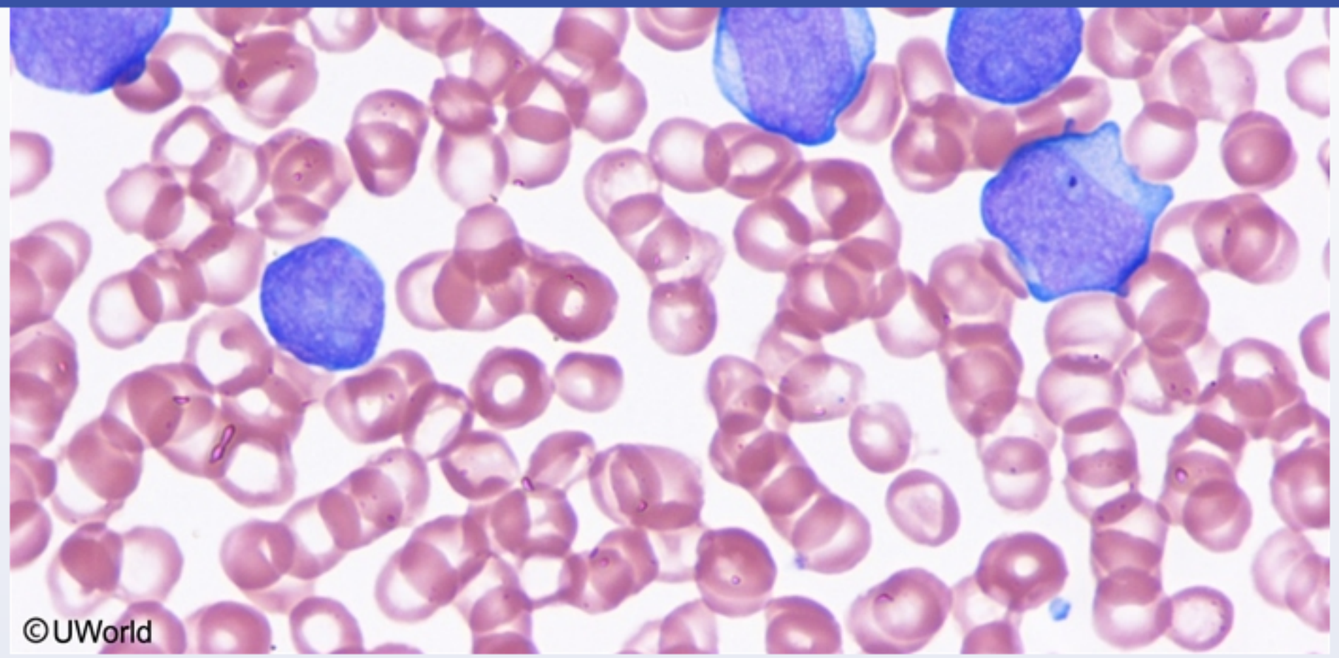

- ✓ A. Acute lymphoblastic leukemia (86%)
- B. Acute myeloid leukemia (5%)
- C. Burkitt lymphoma (2%)
- D. Hodgkin lymphoma (2%)
- E. Mantle cell lymphoma (2%)

Omitted
Correct answer

86%
Answered correctly

07 secs
Time Spent

02/06/2020
Last Updated

7 8 9 10 11 12 13 14 15 16 17 18 19 20 21 22 23 24 25 26 27 28 29 30 31 32 33 34 35 36

This patient's peripheral blood smear demonstrates blast cells with large, irregular nuclei and granular chromatin. Blast cells are early hematologic precursors that may be either lymphoid or myeloid in origin. The presence of **terminal deoxynucleotidyl transferase** (TDT), a DNA polymerase involved in V(D)J recombination that is expressed only by lymphoid progenitor cells, indicates that the cells are lymphoblasts. Lymphoblasts are then further differentiated by the presence or absence of specific surface markers unique to B cells (eg, CD19, CD20) or T cells (eg, **CD3**).

This patient with circulating blasts that are positive for TDT (indicating lymphoid origin) and CD3 (indicating T-cell origin) has **T-cell acute lymphoblastic leukemia** (ALL). Unlike B-cell ALL, which usually occurs in early childhood, **T-cell ALL** is most common in the **teenage years** or early adulthood. Tumors classically develop in the thymus, the organ charged with T-cell development, and often result in the formation of a **mediastinal mass** that compresses the airway (causing cough and dyspnea) or nearby blood vessels (causing superior vena cava syndrome). Pleural effusions are also common due to inflammation from tumor growth/cytokine release.

(Choice B) Acute myeloid leukemia is a hematologic malignancy that arises from myeloid precursors. Although myeloblasts can occasionally be confused with lymphoblasts, myeloblasts never express TDT. Auer rods are a specific finding in myeloblastic leukemia.

(Choice C) Burkitt lymphoma is an aggressive B-cell, non-Hodgkin lymphoma that is strongly associated with Epstein-Barr virus. Jaw/facial bone and abdominal involvement are common; a mediastinal mass would be atypical. In addition, Burkitt lymphoma cells express B-cell, not T-cell, tumor markers and are not associated with circulating blasts.

(Choice D) Hodgkin lymphoma is a neoplasm that arises from germinal or post-germinal center B cells. Most patients have painless, peripheral lymphadenopathy, particularly in the cervical region. Reed-Sternberg cells (large lymphocytes with multiple or bilobed nuclei and eosinophilic nucleoli) are characteristically seen in bone marrow. Circulating blasts are not a typical feature of this disease, and cells would express B-cell, not T-cell, markers.

(Choice E) Mantle cell lymphoma is a mature B-cell, non-Hodgkin lymphoma that usually presents with lymphadenopathy, splenomegaly, and cytopenia. This tumor type would express B-cell, not T-cell, surface markers, and peripheral blasts would be atypical.

Educational objective:
Acute lymphoblastic leukemia (ALL) is marked by a high concentration of circulating lymphoblasts. Flow cytometry can be used to distinguish between B-cell (CD19-expressing) and T-cell (CD3-expressing) lineages. T-cell ALL usually arises in teenagers or individuals in their 20s and often presents with a large mediastinal mass.

Explanation

Exhibit Display

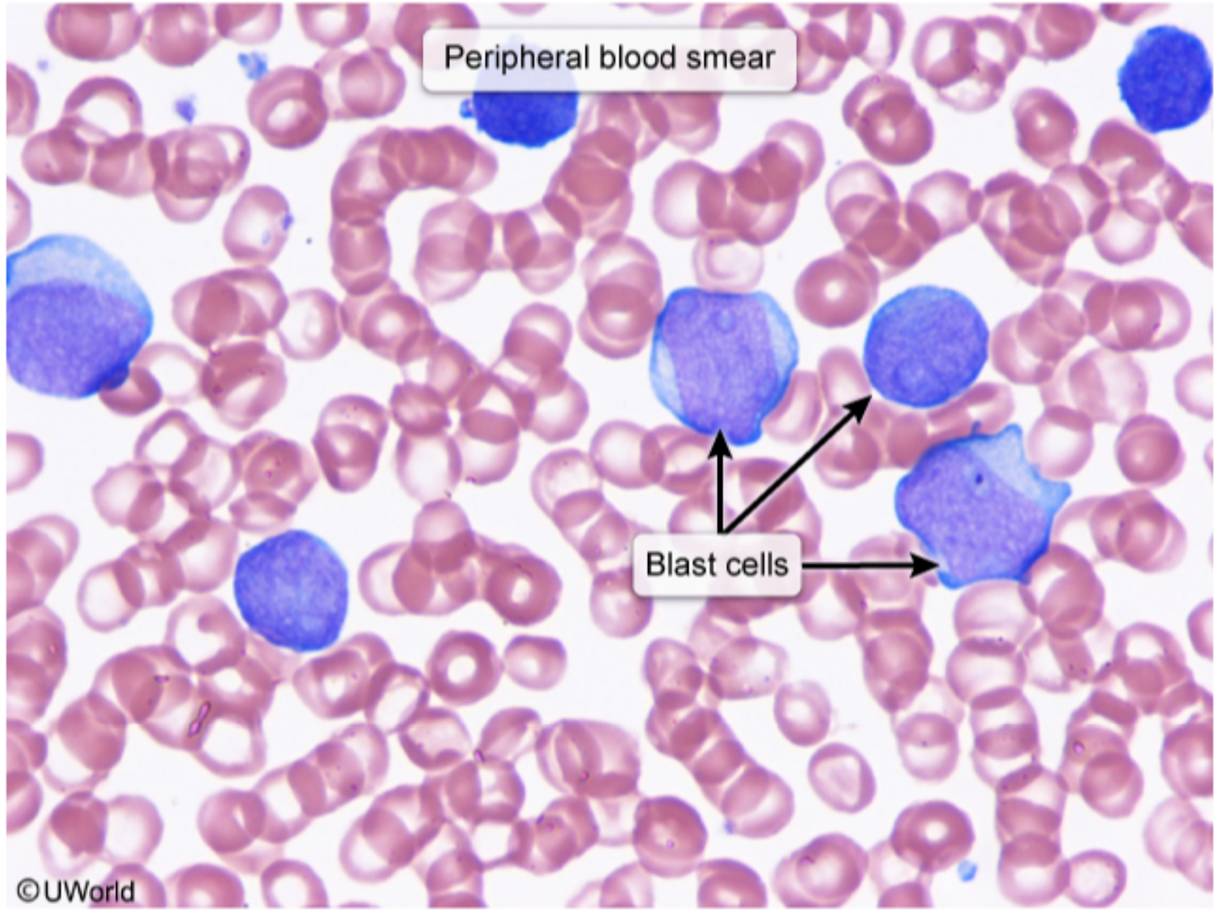

Zoom In | Zoom Out | Reset | Add To New Card | Existing Card

between B-cell (CD19-expressing) and T-cell (CD3-expressing) lineages. T-cell ALL usually arises in teenagers or individuals in their 20s and

This patient with circulating blasts that are positive for TDT (indicating lymphoid origin) and CD3 (indicating T-cell origin) has **T-cell acute lymphoblastic leukemia** (ALL). Unlike B-cell ALL, which usually occurs in early childhood, **T-cell ALL** is most common in the **teenage years** or early adulthood. Tumors classically develop in the thymus, the organ charged with T-cell development, and often result in the formation of a **mediastinal mass** that compresses the airway (causing cough and dyspnea) or nearby blood vessels (causing superior vena cava syndrome). Pleural effusions are also common due to inflammation from tumor growth/cytokine release.

(Choice B) Acute myeloid leukemia is a hematologic malignancy that arises from myeloid precursors. Although myeloblasts can occasionally be confused with lymphoblasts, myeloblasts never express TDT. Auer rods are a specific finding in myeloblastic leukemia.

(Choice C) Burkitt lymphoma is an aggressive B-cell, non-Hodgkin lymphoma that is strongly associated with Epstein-Barr virus. Jaw/facial bone and abdominal involvement are common; a mediastinal mass would be atypical. In addition, Burkitt lymphoma cells express B-cell, not T-cell, tumor markers and are not associated with circulating blasts.

(Choice D) Hodgkin lymphoma is a neoplasm that arises from germinal or post-germinal center B cells. Most patients have painless, peripheral lymphadenopathy, particularly in the cervical region. Reed-Sternberg cells (large lymphocytes with multiple or bilobed nuclei and eosinophilic nucleoli) are characteristically seen in bone marrow. Circulating blasts are not a typical feature of this disease, and cells would express B-cell, not T-cell, markers.

(Choice E) Mantle cell lymphoma is a mature B-cell, non-Hodgkin lymphoma that usually presents with lymphadenopathy, splenomegaly, and cytopenia. This tumor type would express B-cell, not T-cell, surface markers, and peripheral blasts would be atypical.

Educational objective:
Acute lymphoblastic leukemia (ALL) is marked by a high concentration of circulating lymphoblasts. Flow cytometry can be used to distinguish between B-cell (CD19-expressing) and T-cell (CD3-expressing) lineages. T-cell ALL usually arises in teenagers or individuals in their 20s and often presents with a large mediastinal mass.

Pathology	Hematology & Oncology	Acute lymphoblastic leukemia
Subject	System	Topic

Copyright © UWorld. All rights reserved.

This patient with circulating blasts that are positive for TdT (indicating lymphoid origin) and CD3 (indicating T-cell origin) has **T-cell acute lymphoblastic leukemia** (ALL). Unlike B-cell ALL, which usually occurs in early childhood, **T-cell ALL** is most common in the teenage years or

Exhibit Display

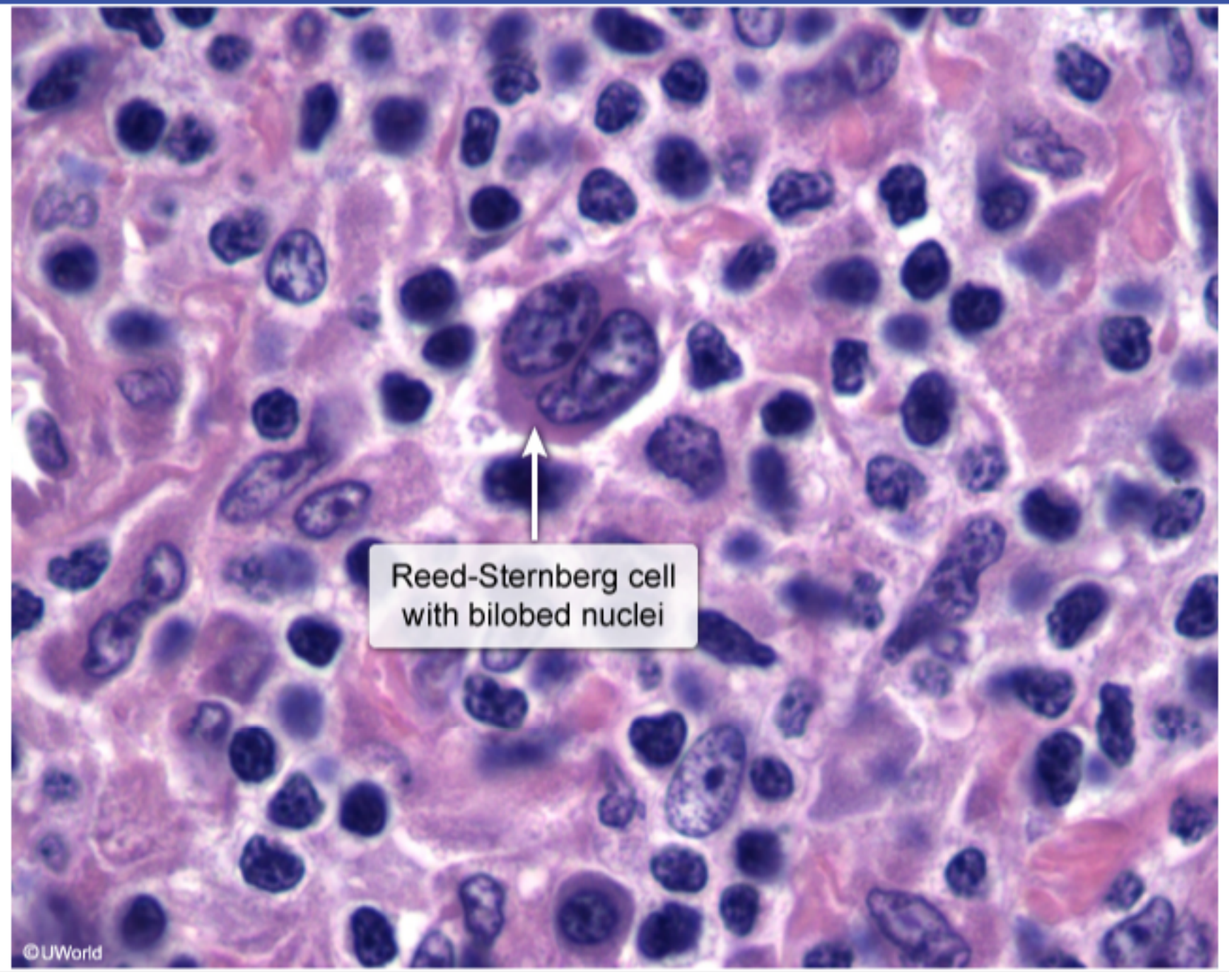

Zoom In | Zoom Out | Reset | Add To New Card | Existing Card

6
7
8
9
10
11
12
13
14
15
16
17
18
19
20
21
22
23
24
25
26
27
28
29
30
31
32
33
34
35
36

This patient with circulating blasts that are positive for TdT (indicating lymphoid origin) and CD3 (indicating T-cell origin) has **T-cell acute lymphoblastic leukemia** (ALL). Unlike B-cell ALL, which usually occurs in early childhood, **T-cell ALL** is most common in the teenage years or

Exhibit Display

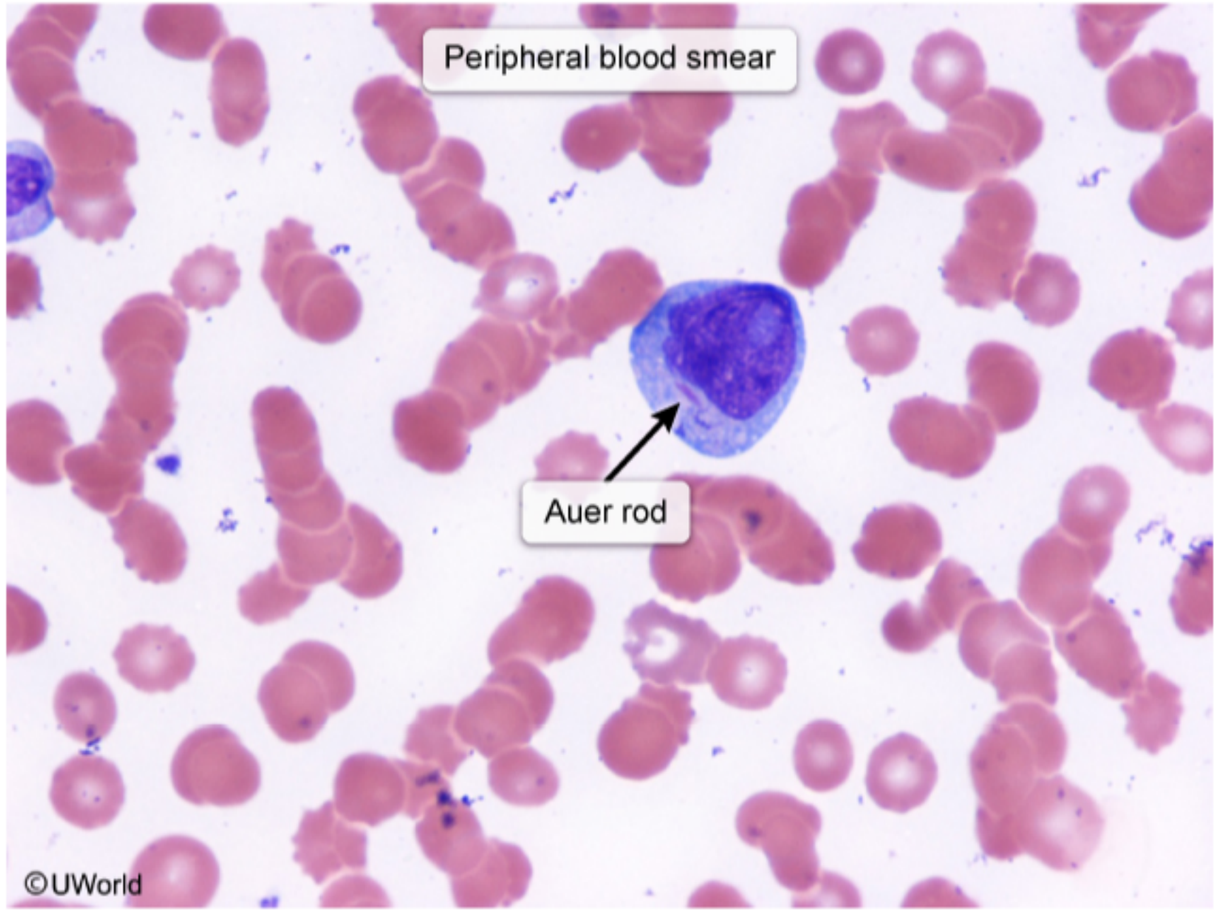

Zoom In | Zoom Out | Reset | Add To New Card | Existing Card

7
8
9
10
11
12
13
14
15
16
17
18
19
20
21
22
23
24
25
26
27
28
29
30
31
32
33
34
35
36

Exhibit Display

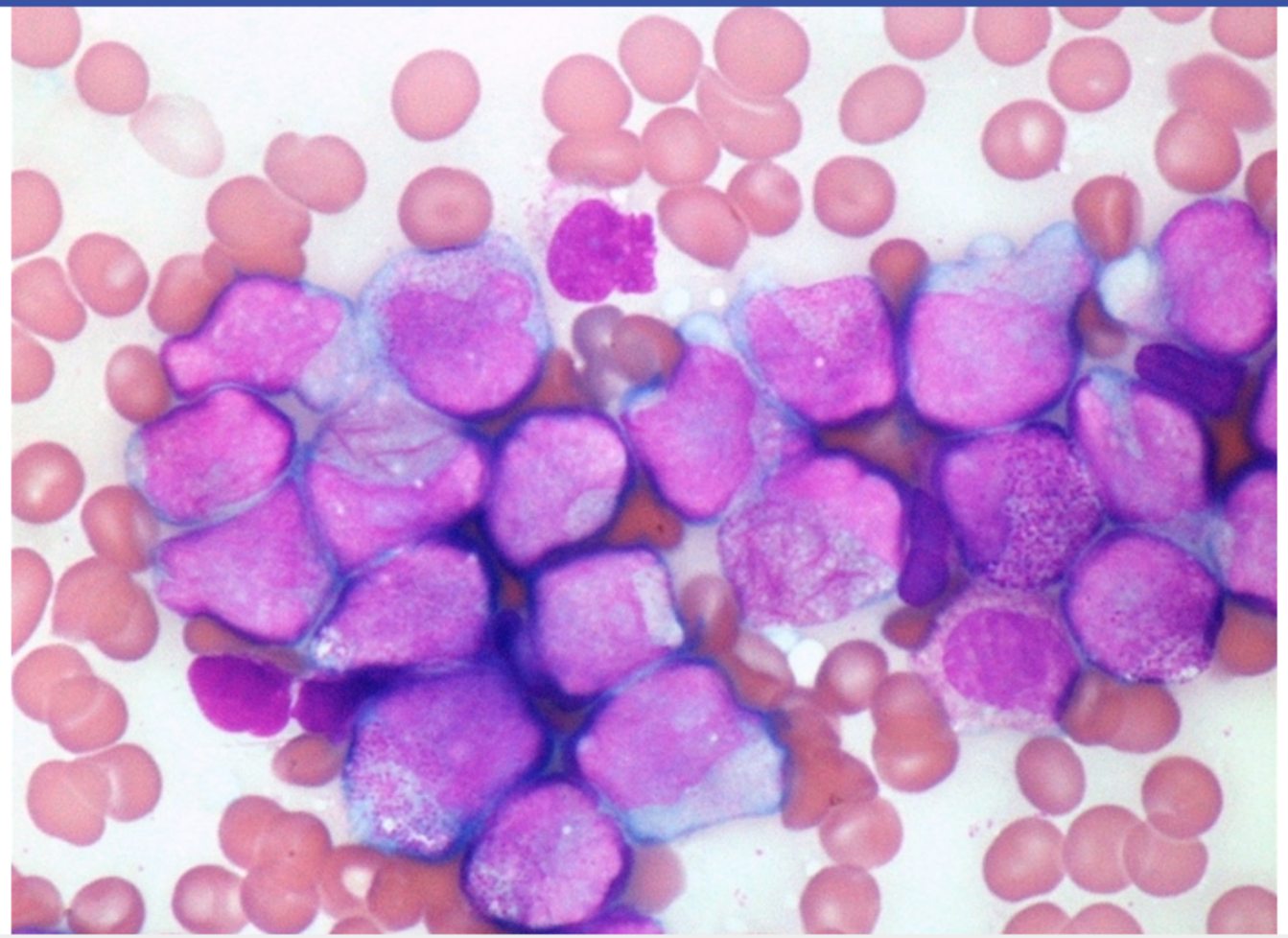

Zoom In | Zoom Out | Reset | Add To New Card | Existing Card

These cells contain structures that would stain positive for which of the following?

7
8
9
10
11
12
13
14
15
16
17
18
19
20
21
22
23
24
25
26
27
28
29
30
31
32
33
34
35
36

A 36-year-old man presents to your office with persistent fever, bleeding gums, and a sore throat. Peripheral blood microscopy findings are shown in the image below.

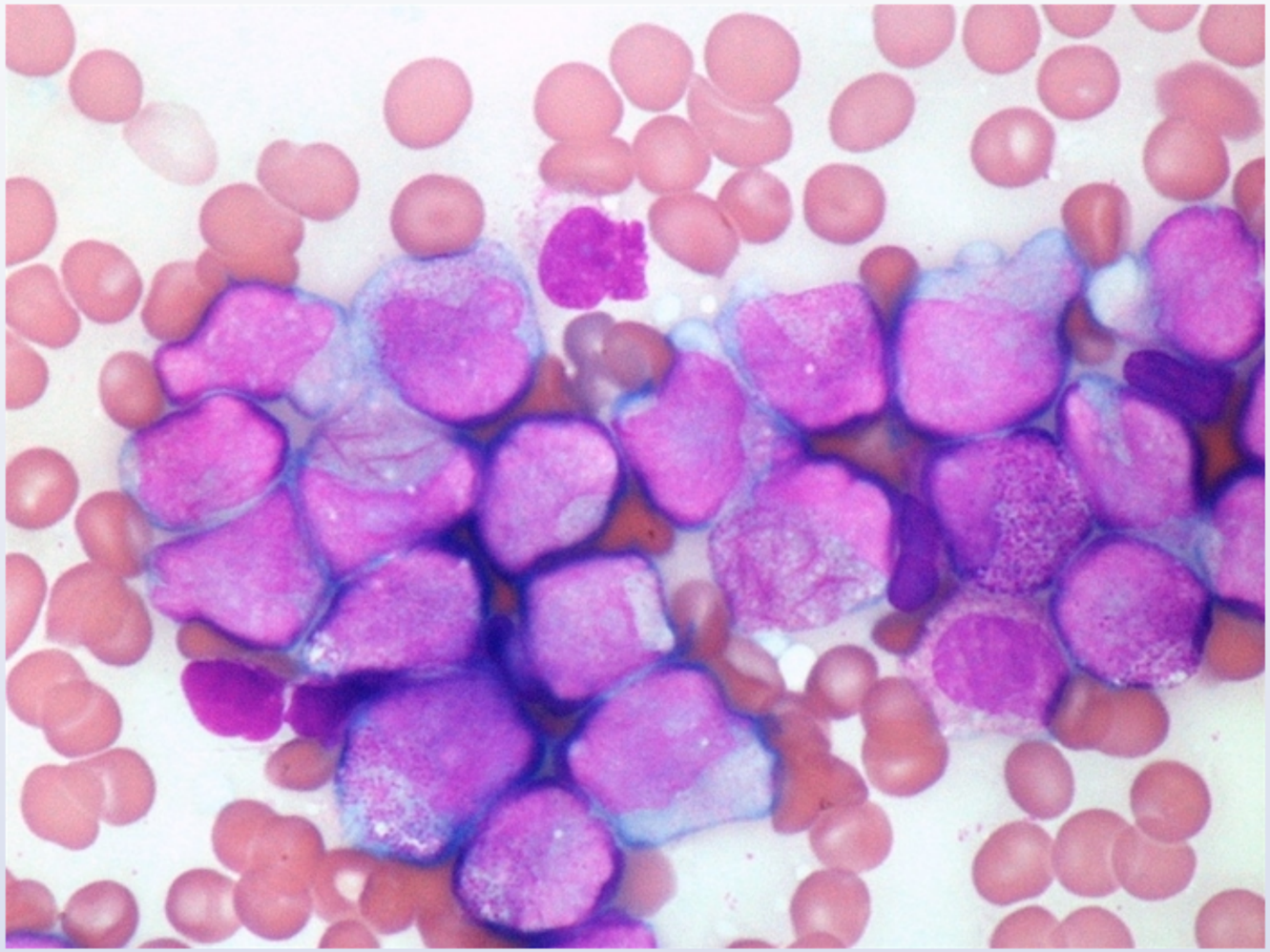

These cells contain structures that would stain positive for which of the following?

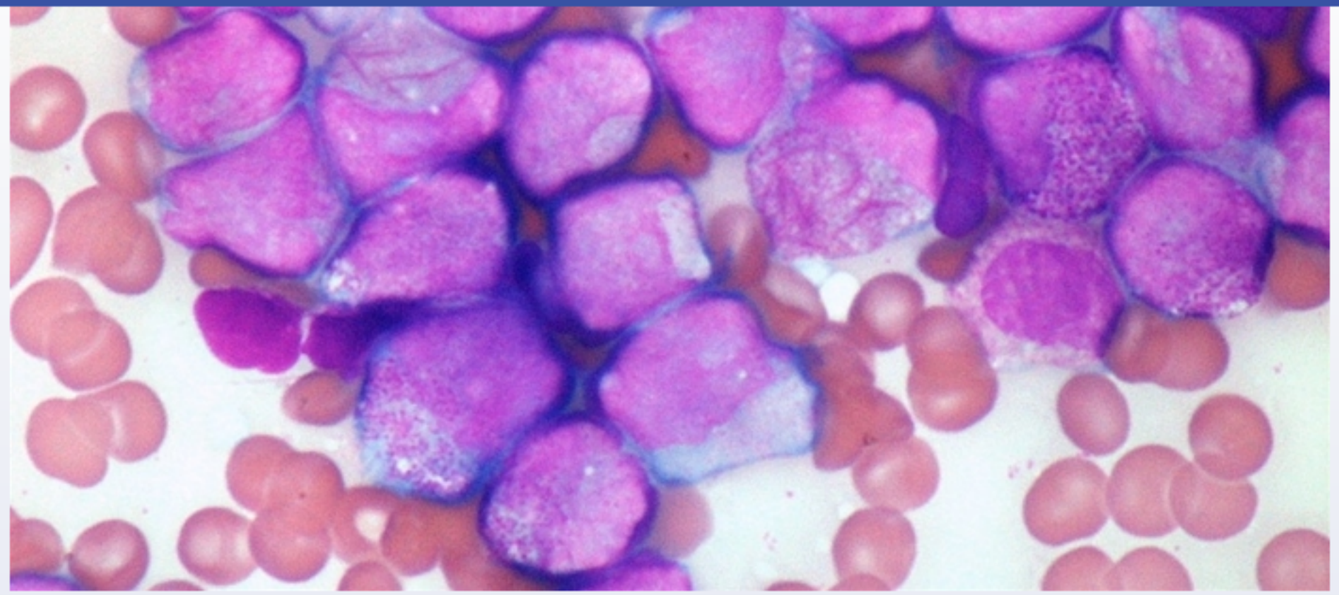

These cells contain structures that would stain positive for which of the following?

- A. Major basic protein
- B. Myeloperoxidase
- C. Platelet-derived growth factor
- D. Tartrate resistant acid phosphatase
- E. Terminal deoxynucleotidyl transferase

Submit

7
8
9
10
11
12
13
14
15
16
17
18
19
20
21
22
23
24
25
26
27
28
29
30
31
32
33
34
35
36

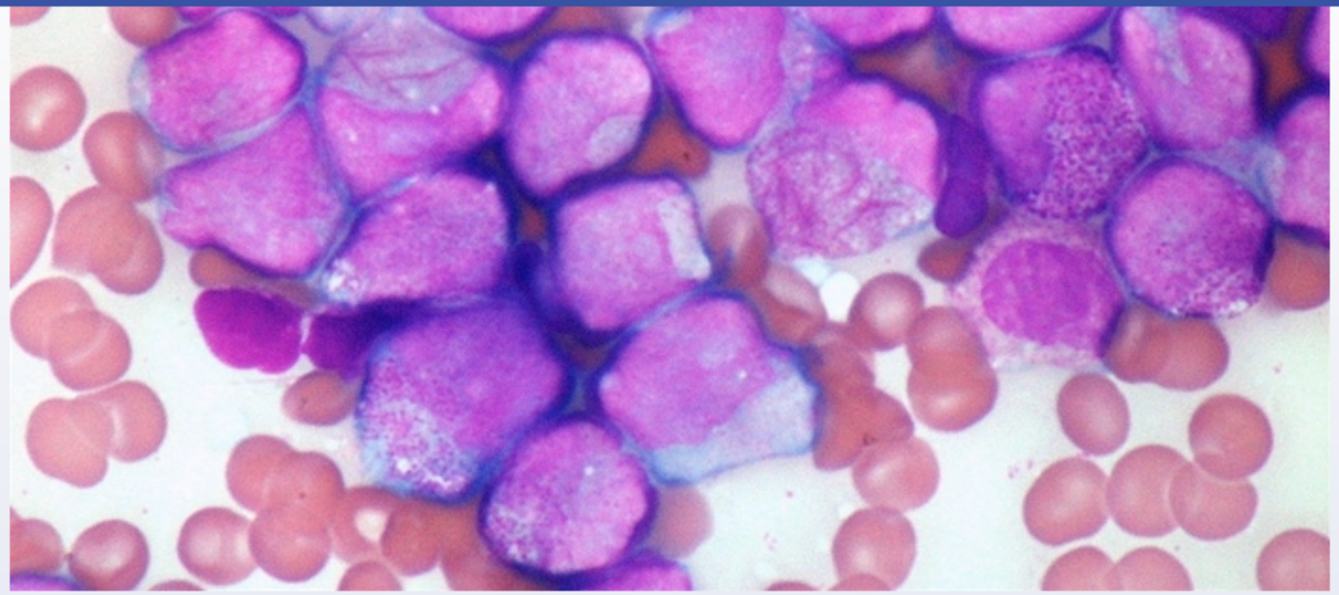

These cells contain structures that would stain positive for which of the following?

- A. Major basic protein (7%)
- ✓ B. Myeloperoxidase (64%)
- C. Platelet-derived growth factor (4%)
- D. Tartrate resistant acid phosphatase (10%)
- E. Terminal deoxynucleotidyl transferase (13%)

Omitted
Correct answer

64%
Answered correctly

07 secs
Time Spent

04/16/2020
Last Updated

7
8
9
10
11
12
13
14
15
16
17
18
19
20
21
22
23
24
25
26
27
28
29
30
31
32
33
34
35
36

7
8
9
10
11
12
13
14
15
16
17
18
19
20
21
22
23
24
25
26
27
28
29
30
31
32
33
34
35
36

Acute promyelocytic leukemia

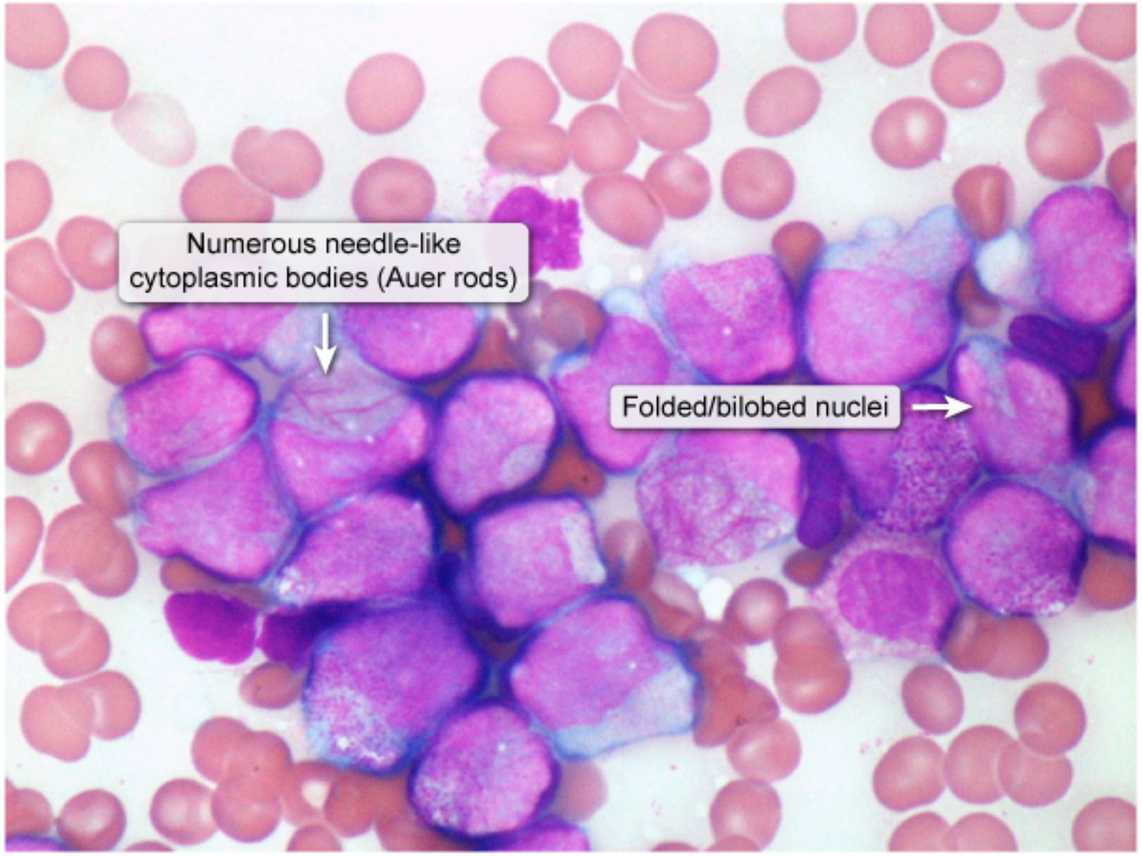

©UWorld

This peripheral blood smear shows **myeloblasts**, which are large myelogenous cells with abundant basophilic cytoplasm and large nuclei that can be folded or bilobed. Myeloblasts often have a number of coarse rod/needle-shaped intracytoplasmic granules (eg, **Auer rods**) that stain positive for **myeloperoxidase**. Auer rods indicate myeloid differentiation.

This peripheral blood smear shows **myeloblasts**, which are large myelogenous cells with abundant basophilic cytoplasm and large nuclei that can be folded or bilobed. Myeloblasts often have a number of coarse rod/needle-shaped intracytoplasmic granules (eg, **Auer rods**) that stain positive for **myeloperoxidase**. Auer rods indicate myeloid differentiation.

Acute promyelogenous leukemia (APL) is a variant of acute myelogenous leukemia (AML), in which immature cells of myeloid origin are unable to differentiate and mature. They proliferate in the bone marrow and suppress the growth and multiplication of other hematopoietic precursors. The clinical manifestations of APL, such as anemia (fatigue, pallor), **thrombocytopenia** (petechiae, hemorrhages), and **neutropenia** (fever, opportunistic infections), result from marrow replacement by leukemic cells.

(Choice A) Major basic protein is found in eosinophil granules and helps to defend against parasites.

(Choice C) Platelet-derived growth factor receptor mutations play a role in gastrointestinal stromal tumors.

(Choice D) Hairy cell leukemia stains positively for tartrate resistant acid phosphatase (TRAP). The neoplastic cells are B lymphocyte precursors and are $CD20^+$. Hairy cell leukemia presents with splenomegaly, fatigue and pancytopenia.

(Choice E) Terminal deoxynucleotidyl transferase (TdT) is responsible for adding nucleotides to the V, D and J regions of the antibody gene for antibody diversity. It is a marker of immature lymphocytes, both B and T cells. Neoplastic cells in acute lymphoblastic leukemia (ALL) are TdT positive. ALL mainly affects children.

Educational Objective:
Auer rods are deformed azurophilic granules found in the cytoplasm of myeloblasts that stain positively for myeloperoxidase. Auer rods are found in abundance in AML M3 (acute promyelocytic leukemia).

Pathology	Hematology & Oncology	Acute myeloid leukemia
Subject	System	Topic

Copyright © UWorld. All rights reserved.

6
7
8
9
10
11
12
13
14
15
16
17
18
19
20
21
22
23
24
25
26
27
28
29
30
31
32
33
34
35
36

A 45-year-old woman comes to the office due to 2 weeks of persistent back pain. She has also had excessive fatigue, anorexia, and unintentional weight loss over the past several months. The patient has no prior medical problems but has a history of cancer in the family. An imaging study reveals a lytic lesion in the T10 vertebral body. Analysis of the biopsy sample shows cell lineage with abnormally high replicative potential. A genetic study reveals a single nucleotide substitution causing an activating mutation. Which of the following genes is most likely involved in this patient's disease?

- A. *APC*
- B. *BRCA1*
- C. *KRAS*
- D. *RB*
- E. *TP53*

Submit

A 45-year-old woman comes to the office due to 2 weeks of persistent back pain. She has also had excessive fatigue, anorexia, and unintentional weight loss over the past several months. The patient has no prior medical problems but has a history of cancer in the family. An imaging study reveals a lytic lesion in the T10 vertebral body. Analysis of the biopsy sample shows cell lineage with abnormally high replicative potential. A genetic study reveals a single nucleotide substitution causing an activating mutation. Which of the following genes is most likely involved in this patient's disease?

- A. *APC* (7%)
- B. *BRCA1* (18%)
- ✓ C. *KRAS* (45%)
- D. *RB* (13%)
- E. *TP53* (15%)

Omitted
Correct answer
C

45%
Answered correctly

02 secs
Time Spent

06/23/2020
Last Updated

Explanation

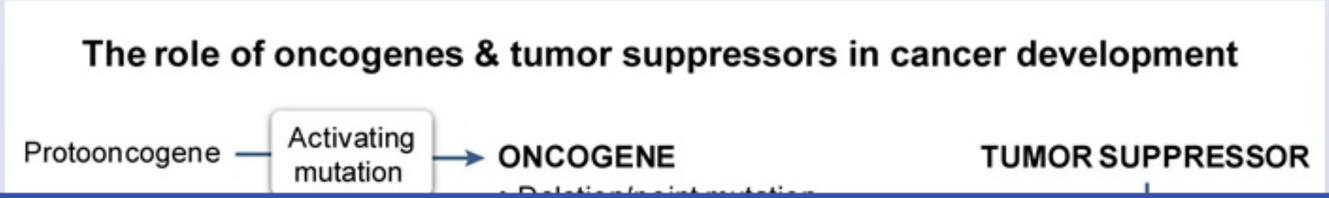

Explanation

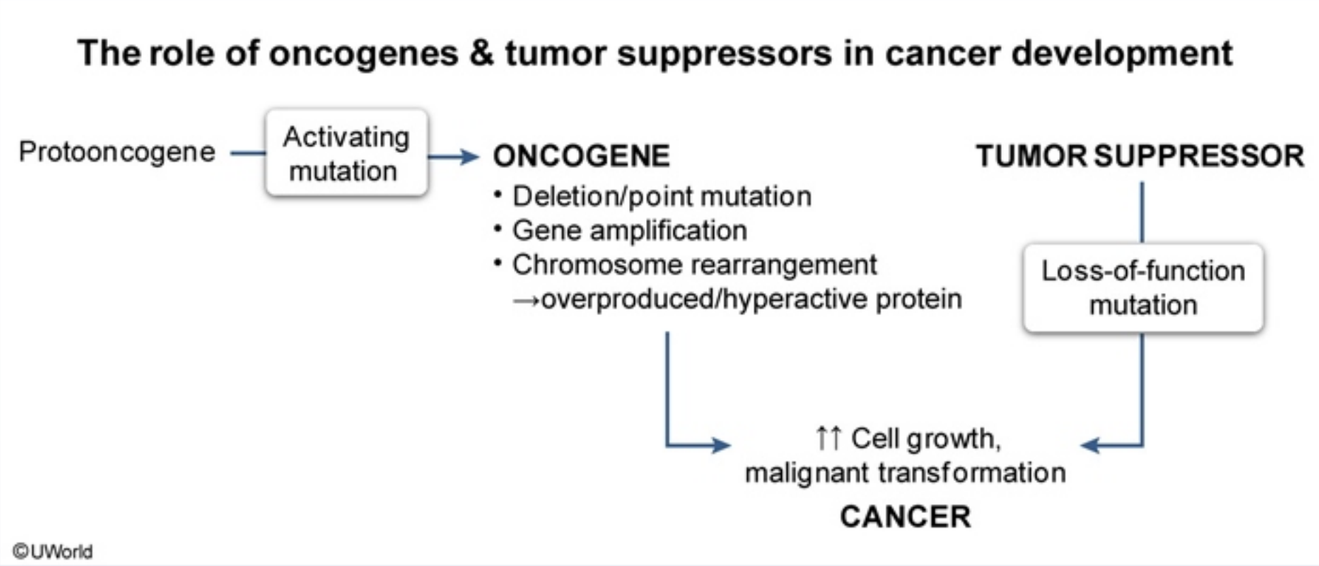

Abnormal growth of neoplastic cells can arise due to mutation of either proto-oncogenes or anti-oncogenes (tumor suppressors). **Proto-oncogenes** stimulate cell proliferation, and their overexpression/amplification (eg, **activating** mutation) leads to increased cellular proliferation and neoplastic growth. ***KRAS*** is a proto-oncogene often activated in tumor cells, thereby increasing the cellular response to mitogenic stimuli.

In contrast, anti-oncogenes are **tumor suppressors** as they inhibit cellular proliferation. Their inactivation (eg, **loss-of-function** mutation) contributes to tumor development. *APC, BRCA1, RB*, and *TP53* are anti-oncogenes and are therefore more likely to be inactivated in neoplastic cells:

- *APC* is inactivated in familial adenomatous polyposis syndrome. Similar mutations are found in many sporadic colon cancers **(Choice A)**
- *BRCA1* is responsible for DNA repair. Its inactivation increases the risk of developing breast and ovarian cancer **(Choice B)**
- When active, *RB* suppresses the transition of cells from the G1 to S phase of the cell cycle, thereby inhibiting cellular proliferation. An inactivated *RB* is found in many tumors **(Choice D)**
- Mutated *TP53* is the most common abnormality associated with cancer development. *TP53* is a tumor suppressor gene that produces p53,

↑↑ Cell growth,
malignant transformation
CANCER

©UWorld

Abnormal growth of neoplastic cells can arise due to mutation of either proto-oncogenes or anti-oncogenes (tumor suppressors). **Proto-oncogenes** stimulate cell proliferation, and their overexpression/amplification (eg, **activating** mutation) leads to increased cellular proliferation and neoplastic growth. ***KRAS*** is a proto-oncogene often activated in tumor cells, thereby increasing the cellular response to mitogenic stimuli.

In contrast, anti-oncogenes are **tumor suppressors** as they inhibit cellular proliferation. Their inactivation (eg, **loss-of-function** mutation) contributes to tumor development. *APC, BRCA1, RB*, and *TP53* are anti-oncogenes and are therefore more likely to be inactivated in neoplastic cells:

- *APC* is inactivated in familial adenomatous polyposis syndrome. Similar mutations are found in many sporadic colon cancers **(Choice A)**
- *BRCA1* is responsible for DNA repair. Its inactivation increases the risk of developing breast and ovarian cancer **(Choice B)**
- When active, *RB* suppresses the transition of cells from the G1 to S phase of the cell cycle, thereby inhibiting cellular proliferation. An inactivated *RB* is found in many tumors **(Choice D)**
- Mutated *TP53* is the most common abnormality associated with cancer development. *TP53* is a tumor suppressor gene that produces p53, a protein that inhibits proliferation of cells with genetic abnormalities **(Choice E)**

Some of the important proto-oncogenes, anti-oncogenes, and their associated tumors are listed in the table.

Educational objective:
Most tumors possess multiple cytogenetic abnormalities. Activation of proto-oncogenes results in stimulation of cellular proliferation. Inactivation of anti-oncogenes eliminates oversight of the cell cycle.

Pathology	Hematology & Oncology	Colorectal cancer
Subject	System	Topic

Copyright © UWorld. All rights reserved.

↑↑ Cell growth,

Exhibit Display

Proto-oncogenes/tumor promoters	Anti-oncogenes/tumor suppressors
• *ABL*: Chronic myeloid leukemia, acute lymphoblastic leukemia	• *APC*/β-catenin: Stomach cancer, colon cancer, pancreatic cancer, familial adenomatous polyposis
• *BRAF*: Melanoma	• *BRCA1, BRCA2*: Breast cancer, ovarian cancer
• *HER1*: Squamous cell lung cancer	• *DCC*: Colon cancer
• *HER2*: Breast cancer, ovarian cancer	• *NF1*: Neuroblastoma, neurofibromatosis type 1, sarcoma
• *MYC*: Neuroblastoma (*NMYC*); small cell lung cancer (*LMYC*)	• *RB*: Retinoblastoma, osteosarcoma, other cancers
• *RAS*: Lung cancer, colon cancer, pancreatic cancer (*KRAS*); renal cell cancer, bladder cancer (*HRAS*)	• *TP53*: Most cancers, Li-Fraumeni syndrome
• *SIS*: Astrocytoma, osteosarcoma	• *VHL*: Von Hippel-Lindau syndrome, renal cell cancer
• *TGFA*: Astrocytoma, hepatocellular carcinoma	• *WT1*: Wilms tumor

©UWorld

Zoom In Zoom Out Reset Add To New Card | Existing Card

A 72-year-old woman comes to the office for a routine follow-up appointment. She has no symptoms and her past medical history is insignificant. Her temperature is 36.7 C (98 F), blood pressure is 110/80 mm Hg, and pulse is 76/min and irregular. ECG shows atrial fibrillation with no ischemic changes. Anticoagulation therapy with warfarin is initiated for stroke prevention. Two days later, the patient is hospitalized with severe skin and subcutaneous fat necrosis. Drug effects on which of the following processes are most likely responsible for this patient's skin findings?

- A. Factor IX synthesis
- B. Factor VIIa activity
- C. Factor XIa activity
- D. Fibrinogen conversion
- E. Protein C activity
- F. Prothrombin conversion

Submit

7
8
9
10
11
12
13
14
15
16
17
18
19
20
21
22
23
24
25
26
27
28
29
30
31
32
33
34
35
36

7
8
9
10
11
12
13
14
15
16
17
18
19
20
21
22
23
24
25
26
27
28
29
30
31
32
33
34
35
36

A 72-year-old woman comes to the office for a routine follow-up appointment. She has no symptoms and her past medical history is insignificant. Her temperature is 36.7 C (98 F), blood pressure is 110/80 mm Hg, and pulse is 76/min and irregular. ECG shows atrial fibrillation with no ischemic changes. Anticoagulation therapy with warfarin is initiated for stroke prevention. Two days later, the patient is hospitalized with severe skin and subcutaneous fat necrosis. Drug effects on which of the following processes are most likely responsible for this patient's skin findings?

- A. Factor IX synthesis (2%)
- B. Factor VIIa activity (6%)
- C. Factor XIa activity (0%)
- D. Fibrinogen conversion (2%)
- ✓ E. Protein C activity (83%)
- F. Prothrombin conversion (2%)

Omitted
Correct answer
E

83%
Answered correctly

02 secs
Time Spent

01/28/2020
Last Updated

Explanation

This patient has **warfarin-induced skin necrosis**, a rare but important complication of warfarin initiation. It is thought to be due to a **transient hypercoagulable state** that can occur during the **first few days** of warfarin therapy.

The overall anticoagulant effect of **warfarin** is due primarily to its inhibition of the vitamin K-dependent gamma-carboxylation of clotting factors II, VII, IX, and X ("vitamin K-dependent clotting factors"). However, warfarin also decreases carboxylation of proteins C and S, which normally exert

This patient has **warfarin-induced skin necrosis**, a rare but important complication of warfarin initiation. It is thought to be due to a **transient hypercoagulable state** that can occur during the **first few days** of warfarin therapy.

The overall anticoagulant effect of **warfarin** is due primarily to its inhibition of the vitamin K-dependent gamma-carboxylation of clotting factors II, VII, IX, and X ("vitamin K-dependent clotting factors"). However, warfarin also decreases carboxylation of proteins C and S, which normally exert an anticoagulant effect (through proteolysis and deactivation of factors V and VIII). **Protein C** has a **short half-life**, so its anticoagulant activity is reduced quickly when warfarin therapy is initiated, by about 50% within the first day. During this time, the vitamin K-dependent clotting factors II, IX, and X continue to exert a procoagulant effect as they have longer half-lives (factor VII has a short half-life similar to protein C).

This difference in half-lives translates into a transient hypercoagulable state:

- Decreased protein C (anticoagulant) activity → procoagulant effect
- Persistent clotting factor II, IX, and X activity → procoagulant effect

Thrombosis and clot can interrupt blood flow to the skin and lead to skin necrosis. For this reason, overlapping coadministration of heparin **("heparin bridge")** is commonly used when warfarin is initiated. The risk of warfarin-induced skin necrosis is increased in patients with a preexisting protein C deficiency, as well as in those started on a large loading dose of warfarin.

(Choice A) Warfarin affects coagulation factor carboxylation, not synthesis.

(Choice B) Factor VII inhibition by warfarin has an anticoagulant effect.

(Choice C) Warfarin does not have a major direct effect on factor XI activity that would cause skin necrosis.

(Choices D and F) Fibrinogen and prothrombin activity may be impacted downstream, but this is not the primary process affected by warfarin.

Educational objective:
Warfarin inhibits proteins C and S (natural anticoagulants present in blood), which can lead to skin necrosis, particularly in patients with protein C or S deficiency. This complication is usually seen in the first few days of warfarin therapy.

References

- Coumadin-induced skin necrosis in a 64 year-old female despite LMWH bridging therapy.

an anticoagulant effect (through proteolysis and deactivation of factors V and VIII). **Protein C** has a **short half-life**, so its anticoagulant activity is reduced quickly when warfarin therapy is initiated, by about 50% within the first day. During this time, the vitamin K-dependent clotting factors II, IX, and X continue to exert a procoagulant effect as they have longer half-lives (factor VII has a short half-life similar to protein C).

This difference in half-lives translates into a transient hypercoagulable state:

- Decreased protein C (anticoagulant) activity → procoagulant effect
- Persistent clotting factor II, IX, and X activity → procoagulant effect

Thrombosis and clot can interrupt blood flow to the skin and lead to skin necrosis. For this reason, overlapping coadministration of heparin **("heparin bridge")** is commonly used when warfarin is initiated. The risk of warfarin-induced skin necrosis is increased in patients with a preexisting protein C deficiency, as well as in those started on a large loading dose of warfarin.

(Choice A) Warfarin affects coagulation factor carboxylation, not synthesis.

(Choice B) Factor VII inhibition by warfarin has an anticoagulant effect.

(Choice C) Warfarin does not have a major direct effect on factor XI activity that would cause skin necrosis.

(Choices D and F) Fibrinogen and prothrombin activity may be impacted downstream, but this is not the primary process affected by warfarin.

Educational objective:
Warfarin inhibits proteins C and S (natural anticoagulants present in blood), which can lead to skin necrosis, particularly in patients with protein C or S deficiency. This complication is usually seen in the first few days of warfarin therapy.

References

- Coumadin-induced skin necrosis in a 64 year-old female despite LMWH bridging therapy.

Pathology	Hematology & Oncology	Anticoagulants
Subject	System	Topic

Copyright © UWorld. All rights reserved.

7
8
9
10
11
12
13
14
15
16
17
18
19
20
21
22
23
24
25
26
27
28
29
30
31
32
33
34
35
36

A 34-year-old man with an unremarkable past medical history is evaluated for an enlarged lymph node in his anterior cervical chain that measures 4 cm in diameter. The patient first felt the lymph node several weeks ago and states that it has been steadily increasing in size. He is concerned about whether or not he "has cancer." The patient is referred to a specialist for surgical removal of the enlarged node. Biopsy reveals abnormal lymph node architecture and numerous lymphocytes. Which of the following, if present, would be most consistent with malignancy in this patient?

A. Lymphocyte pleomorphism

B. Abundant mitotic figures within the lymph node

C. Nuclear changes in lymphocytes

D. Monoclonal T-cell receptor gene rearrangements

E. Admixture of several lymphoid cell types within the lymph node

Submit

7
8
9
10
11
12
13
14
15
16
17
18
19
20
21
22
23
24
25
26
27
28
29
30
31
32
33
34
35
36

A 34-year-old man with an unremarkable past medical history is evaluated for an enlarged lymph node in his anterior cervical chain that measures 4 cm in diameter. The patient first felt the lymph node several weeks ago and states that it has been steadily increasing in size. He is concerned about whether or not he "has cancer." The patient is referred to a specialist for surgical removal of the enlarged node. Biopsy reveals abnormal lymph node architecture and numerous lymphocytes. Which of the following, if present, would be most consistent with malignancy in this patient?

A. Lymphocyte pleomorphism (12%)

B. Abundant mitotic figures within the lymph node (32%)

C. Nuclear changes in lymphocytes (14%)

✓ D. Monoclonal T-cell receptor gene rearrangements (34%)

E. Admixture of several lymphoid cell types within the lymph node (5%)

Omitted
Correct answer
D

34%
Answered correctly

02 secs
Time Spent

05/18/2020
Last Updated

Explanation

Lymphadenopathy can represent inflammatory changes within the lymph node (reactive hyperplasia) or malignant transformation. Reactive hyperplasia is a broad term that encompasses all benign, reversible enlargement of the lymphoid tissue secondary to an antigenic stimulus. The nodal response to antigenic stimuli is highly variable and can be classified as follicular hyperplasia, sinus hyperplasia, or diffuse hyperplasia. Follicular hyperplasia occurs when the follicles increase in size and number, whereas sinus hyperplasia occurs when the sinuses enlarge and fill with histiocytes. Diffuse hyperplasia is observed when the nodal architecture is diffusely effaced by sheets of lymphocytes, immunoblasts, and macrophages. When malignant transformation occurs (as in lymphomas), the normal lymph node architecture is distorted or effaced by the

Lymphadenopathy can represent inflammatory changes within the lymph node (reactive hyperplasia) or malignant transformation. Reactive hyperplasia is a broad term that encompasses all benign, reversible enlargement of the lymphoid tissue secondary to an antigenic stimulus. The nodal response to antigenic stimuli is highly variable and can be classified as follicular hyperplasia, sinus hyperplasia, or diffuse hyperplasia. Follicular hyperplasia occurs when the follicles increase in size and number, whereas sinus hyperplasia occurs when the sinuses enlarge and fill with histiocytes. Diffuse hyperplasia is observed when the nodal architecture is diffusely effaced by sheets of lymphocytes, immunoblasts, and macrophages. When malignant transformation occurs (as in lymphomas), the normal lymph node architecture is distorted or effaced by the proliferation of malignant lymphoid cells, often to a greater extent than that seen with reactive hyperplasia. Malignancy-associated effacement of nodal architecture may be follicular or diffuse.

Reactive lymphoid hyperplasia is polyclonal in that it consists of a proliferation of many different cell types within the lymph node. For each type of lymphocyte responding to an antigenic stimulus, multiple genetically-distinct cells of that variety undergo limited monoclonal expansion, leading to an overall polyclonal response. Malignant transformation, in contrast, is monoclonal in that it results from the unchecked proliferation of a single genetically unique cell from only one cell line.

Evaluation for monoclonality of the lymphocyte population is important when lymphoma is suspected. The clonality of a T-cell population is assessed by molecular methods, such as PCR, that examine the rearrangement of T-cell receptor (TCR) genes. If a single allele for the V region of the T-cell receptor predominates in a lymphocytic population, monoclonal proliferation is suspected. The same principle applies when assessing B-cell clonality. Monoclonal rearrangement of the genes for immunoglobulin variable regions is suggestive of a B-cell lymphoma. Of the choices given, monoclonal TCR gene rearrangement is most indicative of malignant processes, especially in the context of appropriate clinical features (i.e., weight loss, night sweats, fever, anorexia).

(Choices A, B, & C) Pleomorphism, increased mitoses, and nuclear changes are all commonly seen in the lymphocytes of a reactive hyperplastic lymph node. These findings do not automatically classify the specimen as malignant.

(Choice E) An admixture of several lymphoid cell types in a lymph node is suggestive of a benign process. A predominantly monomorphic cell population is indicative of malignancy and is characteristic of non-Hodgkin's lymphoma. Hodgkin's lymphoma does demonstrate an admixture of several lymphoid cell types within the lymph nodes; however, this finding does not distinguish Hodgkin's lymphoma from reactive hyperplasia. Additionally, genetic analysis of Reed-Sternberg cells most often reveals monoclonal characteristics.

genetically unique cell from only one cell line.

Evaluation for monoclonality of the lymphocyte population is important when lymphoma is suspected. The clonality of a T-cell population is assessed by molecular methods, such as PCR, that examine the rearrangement of T-cell receptor (TCR) genes. If a single allele for the V region of the T-cell receptor predominates in a lymphocytic population, monoclonal proliferation is suspected. The same principle applies when assessing B-cell clonality. Monoclonal rearrangement of the genes for immunoglobulin variable regions is suggestive of a B-cell lymphoma. Of the choices given, monoclonal TCR gene rearrangement is most indicative of malignant processes, especially in the context of appropriate clinical features (i.e., weight loss, night sweats, fever, anorexia).

(Choices A, B, & C) Pleomorphism, increased mitoses, and nuclear changes are all commonly seen in the lymphocytes of a reactive hyperplastic lymph node. These findings do not automatically classify the specimen as malignant.

(Choice E) An admixture of several lymphoid cell types in a lymph node is suggestive of a benign process. A predominantly monomorphic cell population is indicative of malignancy and is characteristic of non-Hodgkin's lymphoma. Hodgkin's lymphoma does demonstrate an admixture of several lymphoid cell types within the lymph nodes; however, this finding does not distinguish Hodgkin's lymphoma from reactive hyperplasia. Additionally, genetic analysis of Reed-Sternberg cells most often reveals monoclonal characteristics.

Educational objective:
Benign lymph node enlargement in response to antigenic stimulation is associated with a polyclonal proliferation of lymphocytes. A monoclonal lymphocytic proliferation is strong evidence of malignancy.

References

- Resolving T-cell receptor clonality in two and genotype in four multiplex polymerase chain reactions.
- The polymerase chain reaction in the demonstration of monoclonality in T cell lymphomas.

Pathology	Hematology & Oncology	Nonhodgkin lymphoma
Subject	System	Topic

Copyright © UWorld. All rights reserved.

A 67-year-old woman is evaluated for worsening fatigue and exertional dyspnea. She has no prior medical conditions and takes no medications. The patient does not use tobacco, alcohol, or illicit drugs and consumes a balanced diet. Vital signs are within normal limits. Physical examination is notable for mucosal pallor. Stool testing for occult blood is negative. Laboratory studies reveal that hemoglobin is 6.7 g/dL, white blood cell count is 35,000/mm^3, and platelets are 45,000/mm^3. Peripheral blood flow cytometry of the white blood cell population is shown below.

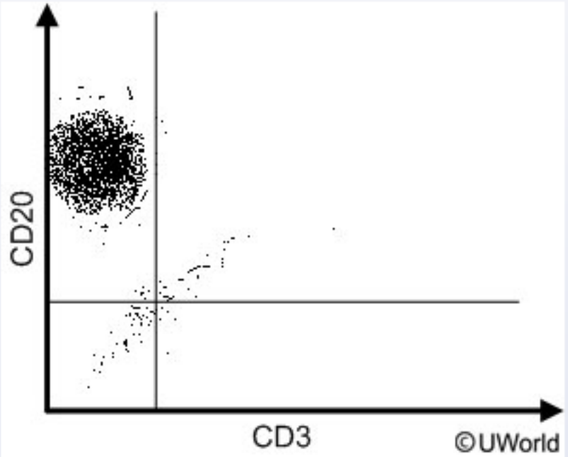

Which of the following is the most likely diagnosis?

A. Adult T-cell leukemia
B. Aplastic anemia
C. Chronic lymphocytic leukemia
D. Chronic myeloid leukemia
E. Hodgkin lymphoma

is notable for mucosal pallor. Stool testing for occult blood is negative. Laboratory studies reveal that hemoglobin is 6.7 g/dL, white blood cell count is 35,000/mm³, and platelets are 45,000/mm³. Peripheral blood flow cytometry of the white blood cell population is shown below.

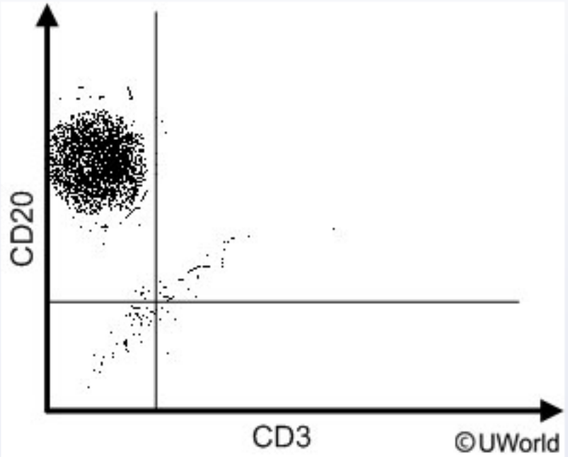

Which of the following is the most likely diagnosis?

- A. Adult T-cell leukemia
- B. Aplastic anemia
- C. Chronic lymphocytic leukemia
- D. Chronic myeloid leukemia
- E. Hodgkin lymphoma

Submit

is notable for mucosal pallor. Stool testing for occult blood is negative. Laboratory studies reveal that hemoglobin is 6.7 g/dL, white blood cell count is 35,000/mm³, and platelets are 45,000/mm³. Peripheral blood flow cytometry of the white blood cell population is shown below.

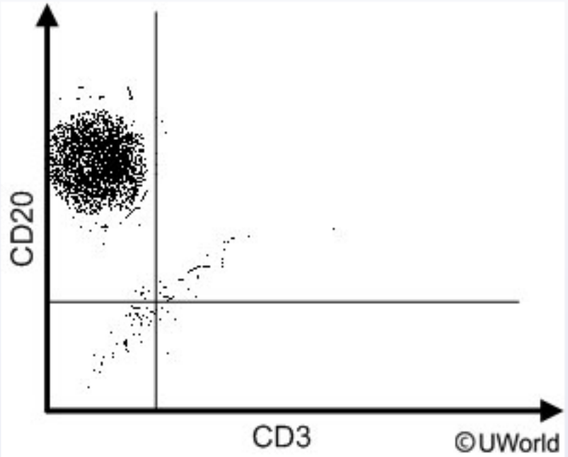

Which of the following is the most likely diagnosis?

- A. Adult T-cell leukemia (3%)
- B. Aplastic anemia (1%)
- ✓ C. Chronic lymphocytic leukemia (67%)
- D. Chronic myeloid leukemia (9%)
- E. Hodgkin lymphoma (17%)

Omitted
Correct answer

67%
Answered correctly

07 secs
Time Spent

02/24/2020
Last Updated

This patient's symptomatic anemia (eg, fatigue, weakness), thrombocytopenia, and leukocytosis are associated with clonal proliferation of CD20-positive cells (a B-cell surface marker), raising strong suspicion for **chronic lymphocytic leukemia** (CLL). In CLL, **mature B cells** progressively accumulate in the bone marrow and peripheral blood due to oncogenic mutations that **inhibit apoptosis**. Although most patients are asymptomatic for years, accumulation of B-cells in the bone marrow eventually chokes out normal hematopoiesis, leading to symptomatic **anemia**, **thrombocytopenia**, and infections (due to neutropenia).

Patients with CLL usually have dramatic elevations in peripheral leukocyte count (often >100,000/mm^3) and characteristic findings on peripheral blood smear (eg, smudge cells). The diagnosis is confirmed when flow cytometry of peripheral blood reveals a **clonal population** of leukocytes with B-cell surface markers such as **CD19**, **CD20**, and **CD23**.

(Choice A) T-cell leukemia is marked by the clonal expansion of a leukocyte population with T-cell surface markers such as CD2, CD3, and CD4. This patient's flow cytometry shows a wide range of CD3 positive cells (without any particular prominence), indicating a normal population of T-cells.

(Choice B) Aplastic anemia is characterized by bone marrow failure and is usually triggered by an infection, medication, radiation, toxic substance, or autoimmune disease. Patients have pancytopenia (not leukocytosis) and bone marrow biopsy evidence of a hypocellular marrow with morphologically normal hematopoietic cells; a clonal population of B cells would not be seen.

(Choice D) Chronic myeloid leukemia is a myeloproliferative neoplasm characterized by peripheral leukocytosis due to circulating granulocytes (neutrophils in different stages of maturation). Diagnosis is generally made when cytogenetic studies reveal the BCR-ABL fusion gene (Philadelphia chromosome). A clonal population of CD20-positive cells (B cells) would not be seen.

(Choice E) Hodgkin lymphoma usually causes localized peripheral lymphadenopathy and B-symptoms (eg, fever, night sweats). The diagnosis is made by lymph node excision, which usually reveals Reed-Sternberg cells. Anemia, thrombocytopenia, and leukocytosis would be atypical.

Educational objective:
Chronic lymphocytic leukemia is a chronic lymphoproliferative disorder marked by the progressive accumulation of mature B cells. Most patients are asymptomatic for years but eventually develop anemia, thrombocytopenia, and/or neutropenia. The diagnosis is generally made when complete blood count reveals dramatic leukocytosis, and flow cytometry subsequently shows a clonal population of leukocytes with typical B-cell markers such as CD19, CD20, and CD23.

This patient's symptomatic anemia (eg, fatigue, weakness), thrombocytopenia, and leukocytosis are associated with clonal proliferation of CD20-

Exhibit Display

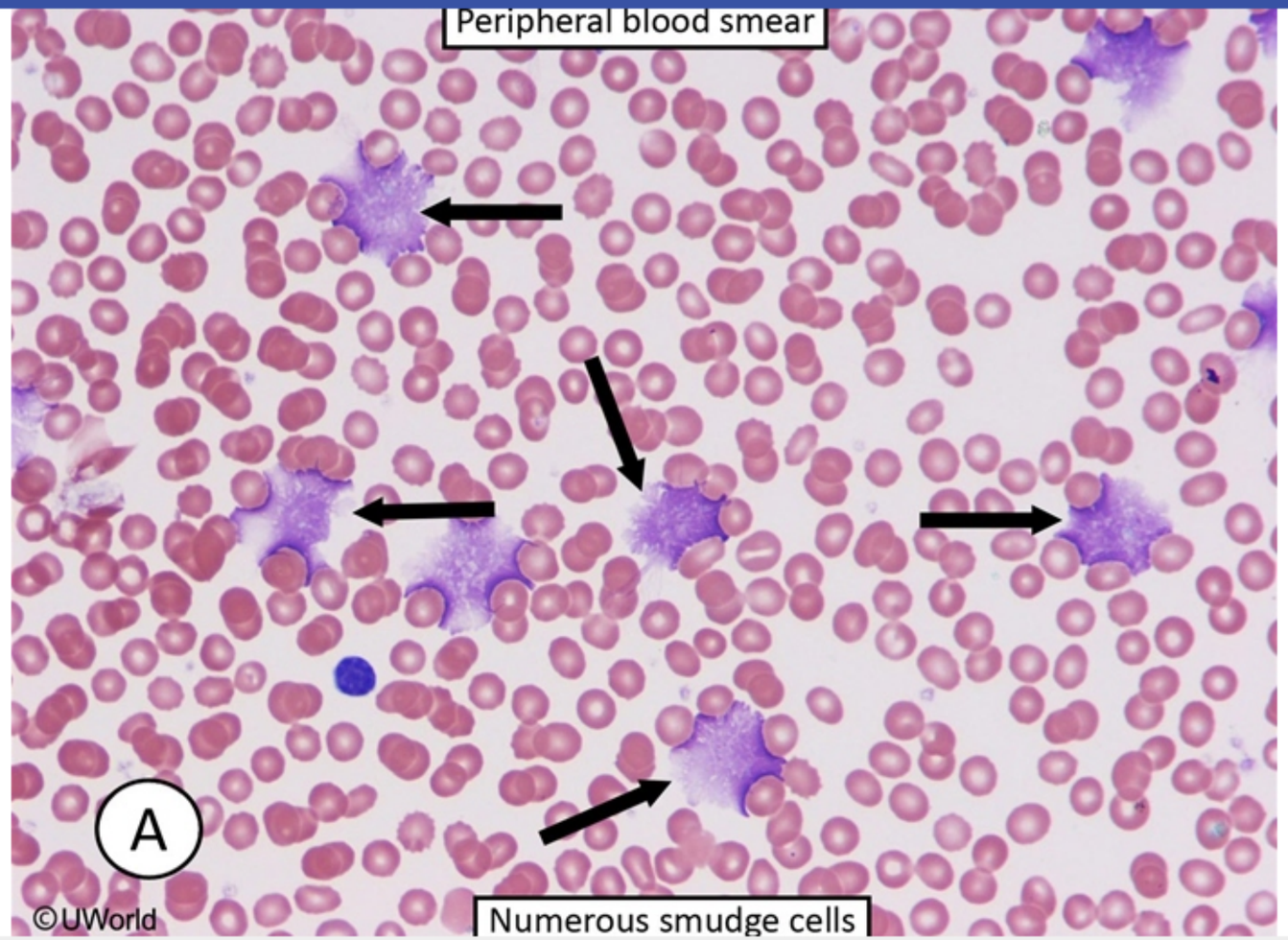

Zoom In | Zoom Out | Reset | Add To New Card | Existing Card

This patient's symptomatic anemia (eg, fatigue, weakness), thrombocytopenia, and leukocytosis are associated with clonal proliferation of CD20-

Exhibit Display

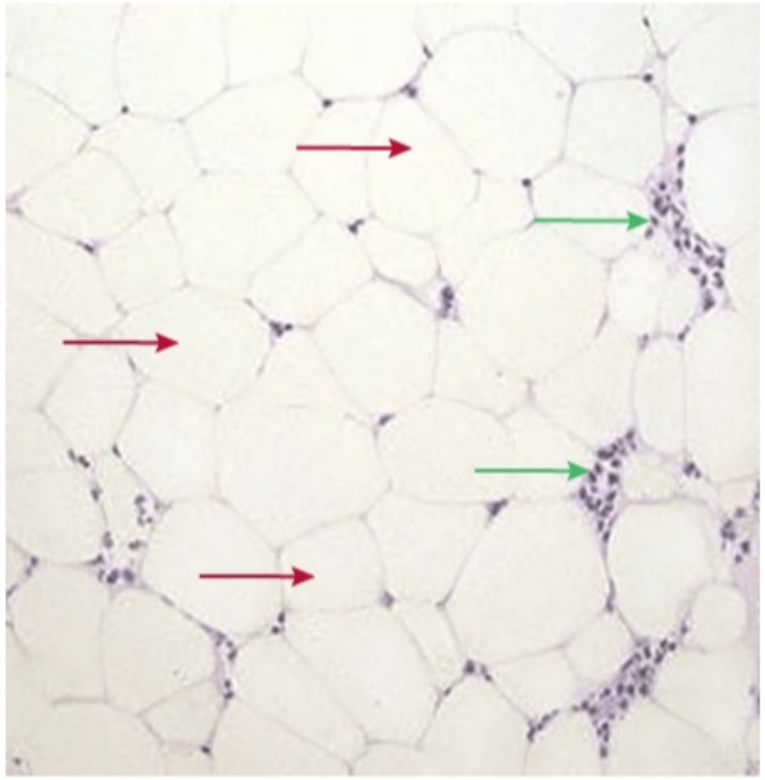

Zoom In | Zoom Out | Reset | Add To New Card | Existing Card

This patient's symptomatic anemia (eg, fatigue, weakness), thrombocytopenia, and leukocytosis are associated with clonal proliferation of CD20-

Exhibit Display

Chronic myelogenous leukemia

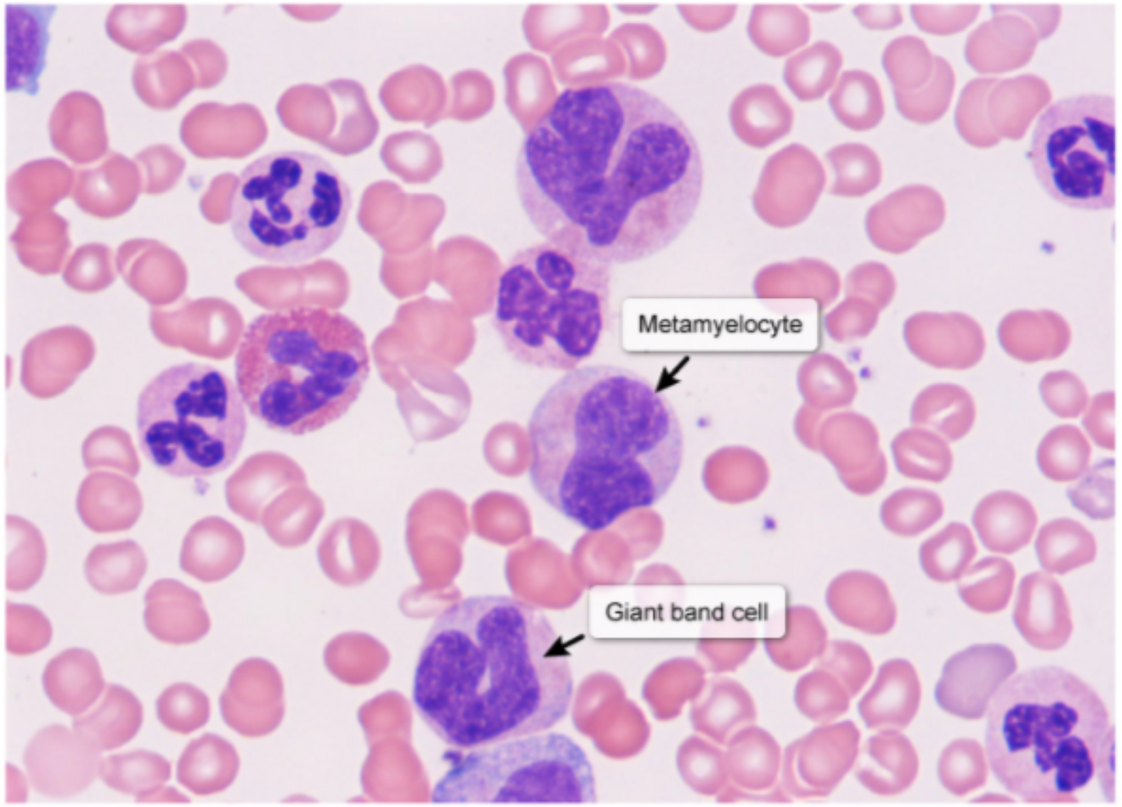

Numerous large, immature granulocytes

©UWorld

Zoom In | Zoom Out | Reset | Add To New Card | Existing Card

This patient's symptomatic anemia (eg, fatigue, weakness), thrombocytopenia, and leukocytosis are associated with clonal proliferation of CD20-

Exhibit Display

Hodgkin lymphoma

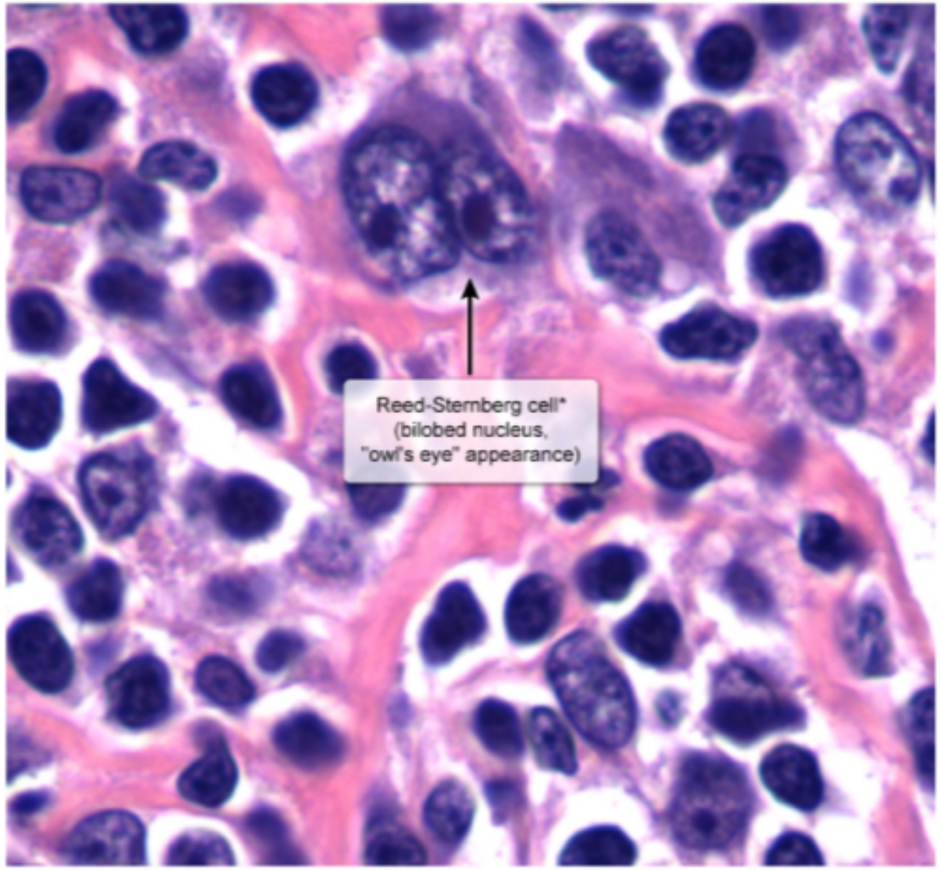

*Derived from CD 20/45 negative B cells

©UWorld

Zoom In | Zoom Out | Reset | Add To New Card | Existing Card

Patients with CLL usually have dramatic elevations in peripheral leukocyte count (often >100,000/mm^3) and characteristic findings on peripheral blood smear (eg, smudge cells). The diagnosis is confirmed when flow cytometry of peripheral blood reveals a **clonal population** of leukocytes with B-cell surface markers such as **CD19**, **CD20**, and **CD23**.

(Choice A) T-cell leukemia is marked by the clonal expansion of a leukocyte population with T-cell surface markers such as CD2, CD3, and CD4. This patient's flow cytometry shows a wide range of CD3 positive cells (without any particular prominence), indicating a normal population of T-cells.

(Choice B) Aplastic anemia is characterized by bone marrow failure and is usually triggered by an infection, medication, radiation, toxic substance, or autoimmune disease. Patients have pancytopenia (not leukocytosis) and bone marrow biopsy evidence of a hypocellular marrow with morphologically normal hematopoietic cells; a clonal population of B cells would not be seen.

(Choice D) Chronic myeloid leukemia is a myeloproliferative neoplasm characterized by peripheral leukocytosis due to circulating granulocytes (neutrophils in different stages of maturation). Diagnosis is generally made when cytogenetic studies reveal the BCR-ABL fusion gene (Philadelphia chromosome). A clonal population of CD20-positive cells (B cells) would not be seen.

(Choice E) Hodgkin lymphoma usually causes localized peripheral lymphadenopathy and B-symptoms (eg, fever, night sweats). The diagnosis is made by lymph node excision, which usually reveals Reed-Sternberg cells. Anemia, thrombocytopenia, and leukocytosis would be atypical.

Educational objective:
Chronic lymphocytic leukemia is a chronic lymphoproliferative disorder marked by the progressive accumulation of mature B cells. Most patients are asymptomatic for years but eventually develop anemia, thrombocytopenia, and/or neutropenia. The diagnosis is generally made when complete blood count reveals dramatic leukocytosis, and flow cytometry subsequently shows a clonal population of leukocytes with typical B-cell markers such as CD19, CD20, and CD23.

Pathology	Hematology & Oncology	Chronic lymphocytic leukemia
Subject	System	Topic

Copyright © UWorld. All rights reserved.

A 63-year-old man comes to the emergency department due to abdominal pain. Physical examination shows abdominal tenderness without guarding or rebound. His laboratory test results are as follows:

Hemoglobin	8.9 g/dL
Platelets	134,000/mm^3
Total bilirubin	6.3 mg/dL
Lactate dehydrogenase	740 U/L
Haptoglobin	Low

On further investigation, magnetic resonance angiography of the abdomen reveals mesenteric vein thrombosis. Flow cytometry shows absence of CD55 on the surface of red blood cells. Which of the following is the most likely pathologic renal finding in this patient?

A. Cast nephropathy
B. Hemosiderosis
C. Interstitial nephritis
D. Membranous glomerulonephritis
E. Minimal change disease

Submit

A 63-year-old man comes to the emergency department due to abdominal pain. Physical examination shows abdominal tenderness without guarding or rebound. His laboratory test results are as follows:

Hemoglobin	8.9 g/dL
Platelets	134,000/mm^3
Total bilirubin	6.3 mg/dL
Lactate dehydrogenase	740 U/L
Haptoglobin	Low

On further investigation, magnetic resonance angiography of the abdomen reveals mesenteric vein thrombosis. Flow cytometry shows absence of CD55 on the surface of red blood cells. Which of the following is the most likely pathologic renal finding in this patient?

A. Cast nephropathy (22%)
B. Hemosiderosis (48%)
C. Interstitial nephritis (12%)
D. Membranous glomerulonephritis (15%)
E. Minimal change disease (1%)

Omitted
Correct answer
B

48%
Answered correctly

01 sec
Time Spent

02/04/2020
Last Updated

Explanation

This patient's presentation is consistent with **paroxysmal nocturnal hemoglobinuria** (PNH), a disorder due to complement-mediated hemolysis. PNH is usually due to a mutated phosphatidylinositol glycan class A (***PIGA***) gene, which helps synthesize the glycosylphosphatidylinositol (**GPI**) anchor protein. This protein helps attach several **cell surface proteins** (eg, **CD55** decay accelerating factor, CD59 MAC inhibitory protein) that inactivate complement. Absence of these proteins leads to uncontrolled **complement-mediated hemolysis**.

Manifestations of PNH include the following:

- Fatigue and jaundice due to **hemolytic anemia** (elevated bilirubin and lactate dehydrogenase, low haptoglobin, **hemoglobinuria** [which may be nocturnal])
- **Thrombosis** at atypical sites (eg, hepatic, portal, or cerebral veins) possibly due to the release of prothrombotic factors from lysed red blood cells and platelets (mesenteric vein thrombosis may explain this patient's abdominal pain)
- **Pancytopenia** due to stem cell injury

Chronic hemolysis with breakdown of iron-containing erythrocytes can also lead to **iron deposition** in the kidney (hemosiderosis), which can interfere with proximal tubule function and cause interstitial scarring and cortical infarcts. The hemosiderosis combined with microvascular thrombosis can increase the risk of chronic kidney disease.

(Choices A and C) Cast nephropathy is usually seen in multiple myeloma and is due to large amounts of monoclonal free chain deposition in the kidney. Interstitial nephritis (inflammation in the area surrounding the renal tubules) is most commonly due to drugs (eg, analgesics, antibiotics), recent infection, or systemic conditions (eg, sarcoidosis).

(Choices D and E) Membranous glomerulonephritis can be associated with systemic lupus erythematosus, drugs (eg, nonsteroidal anti-inflammatory drugs [NSAIDs]), hepatitis B and C, or solid tumor malignancies (eg, lung, prostate, gastrointestinal). Minimal change disease can be associated with drugs (eg, NSAIDs), hematologic malignancies (eg, lymphoma, leukemia), or allergens (eg, fungi).

Educational objective:
Paroxysmal nocturnal hemoglobinuria is due to a gene defect that leads to uncontrolled complement-mediated hemolysis. The classic triad includes hemolytic anemia (hemoglobinuria), pancytopenia, and thrombosis at atypical sites. Chronic hemolysis can cause iron deposition in the kidney (hemosiderosis).

cells and platelets (mesenteric vein thrombosis may explain this patient's abdominal pain)

- **Pancytopenia** due to stem cell injury

Chronic hemolysis with breakdown of iron-containing erythrocytes can also lead to **iron deposition** in the kidney (hemosiderosis), which can interfere with proximal tubule function and cause interstitial scarring and cortical infarcts. The hemosiderosis combined with microvascular thrombosis can increase the risk of chronic kidney disease.

(Choices A and C) Cast nephropathy is usually seen in multiple myeloma and is due to large amounts of monoclonal free chain deposition in the kidney. Interstitial nephritis (inflammation in the area surrounding the renal tubules) is most commonly due to drugs (eg, analgesics, antibiotics), recent infection, or systemic conditions (eg, sarcoidosis).

(Choices D and E) Membranous glomerulonephritis can be associated with systemic lupus erythematosus, drugs (eg, nonsteroidal anti-inflammatory drugs [NSAIDs]), hepatitis B and C, or solid tumor malignancies (eg, lung, prostate, gastrointestinal). Minimal change disease can be associated with drugs (eg, NSAIDs), hematologic malignancies (eg, lymphoma, leukemia), or allergens (eg, fungi).

Educational objective:
Paroxysmal nocturnal hemoglobinuria is due to a gene defect that leads to uncontrolled complement-mediated hemolysis. The classic triad includes hemolytic anemia (hemoglobinuria), pancytopenia, and thrombosis at atypical sites. Chronic hemolysis can cause iron deposition in the kidney (hemosiderosis).

References

- Paroxysmal nocturnal hemoglobinuria
- Fanconi syndrome and CKD in a patient with paroxysmal nocturnal hemoglobinuria and hemosiderosis.
- Renal involvement in paroxysmal nocturnal hemoglobinuria

Pathology	Hematology & Oncology	Paroxysmal nocturnal hemoglobinuria
Subject	System	Topic

Copyright © UWorld. All rights reserved.

A 52-year-old man comes to the office due to a progressively enlarging neck mass, fatigue, and weight loss over the past 2 months. Physical examination shows enlarged, firm, and nontender cervical lymph nodes. The patient also has enlarged tonsils, bilateral axillary lymphadenopathy, and splenomegaly. Excisional lymph node biopsy reveals diffuse sheets of atypical, large B cells with high nuclear-cytoplasmic ratio that has replaced normal tissue architecture. In situ hybridization of the tissue section is positive for Epstein-Barr virus. Which of the following is most strongly correlated with this patient's condition?

A. Advanced HIV infection

B. Aspirin and nonsteroidal anti-inflammatory drug use

C. Cigarette smoking

D. Radiation exposure

E. Socioeconomic status

Submit

7
8
9
10
11
12
13
14
15
16
17
18
19
20
21
22
23
24
25
26
27
28
29
30
31
32
33
34
35
36

A 52-year-old man comes to the office due to a progressively enlarging neck mass, fatigue, and weight loss over the past 2 months. Physical examination shows enlarged, firm, and nontender cervical lymph nodes. The patient also has enlarged tonsils, bilateral axillary lymphadenopathy, and splenomegaly. Excisional lymph node biopsy reveals diffuse sheets of atypical, large B cells with high nuclear-cytoplasmic ratio that has replaced normal tissue architecture. In situ hybridization of the tissue section is positive for Epstein-Barr virus. Which of the following is most strongly correlated with this patient's condition?

- ✓ A. Advanced HIV infection (70%)
- B. Aspirin and nonsteroidal anti-inflammatory drug use (0%)
- C. Cigarette smoking (6%)
- D. Radiation exposure (10%)
- E. Socioeconomic status (10%)

Omitted
Correct answer
A

70%
Answered correctly

02 secs
Time Spent

06/11/2020
Last Updated

Explanation

This patient likely has **non-Hodgkin lymphoma** (NHL). Depending on the subtype, NHL often presents with a rapidly progressive mass, lymphadenopathy, splenomegaly, and B symptoms (eg, night sweats, weight loss). Diagnosis is typically made with excisional lymph node biopsy, which usually shows a loss of normal tissue architecture and large, atypical B cells with a high nuclear-cytoplasmic ratio.

Lymphoma can be associated **Epstein-Barr virus** (EBV), a ubiquitous herpesvirus that primarily infects B lymphocytes and causes persistent

A 52-year-old man comes to the office due to a progressively enlarging neck mass, fatigue, and weight loss over the past 2 months. Physical examination shows enlarged, firm, and nontender cervical lymph nodes. The patient also has enlarged tonsils, bilateral axillary lymphadenopathy, and splenomegaly. Excisional lymph node biopsy reveals diffuse sheets of atypical, large B cells with high nuclear-cytoplasmic ratio that has replaced normal tissue architecture. In situ hybridization of the tissue section is positive for Epstein-Barr virus. Which of the following is most strongly correlated with this patient's condition?

- ✓ A. Advanced HIV infection (70%)
- B. Aspirin and nonsteroidal anti-inflammatory drug use (0%)
- C. Cigarette smoking (6%)
- D. Radiation exposure (10%)
- E. Socioeconomic status (10%)

Omitted
Correct answer
A

70%
Answered correctly

02 secs
Time Spent

06/11/2020
Last Updated

Explanation

This patient likely has **non-Hodgkin lymphoma** (NHL). Depending on the subtype, NHL often presents with a rapidly progressive mass, lymphadenopathy, splenomegaly, and B symptoms (eg, night sweats, weight loss). Diagnosis is typically made with excisional lymph node biopsy, which usually shows a loss of normal tissue architecture and large, atypical B cells with a high nuclear-cytoplasmic ratio.

Lymphoma can be associated **Epstein-Barr virus** (EBV), a ubiquitous herpesvirus that primarily infects B lymphocytes and causes persistent

This patient likely has **non-Hodgkin lymphoma** (NHL). Depending on the subtype, NHL often presents with a rapidly progressive mass, lymphadenopathy, splenomegaly, and B symptoms (eg, night sweats, weight loss). Diagnosis is typically made with excisional lymph node biopsy, which usually shows a loss of normal tissue architecture and large, atypical B cells with a high nuclear-cytoplasmic ratio.

Lymphoma can be associated **Epstein-Barr virus** (EBV), a ubiquitous herpesvirus that primarily infects B lymphocytes and causes persistent latent infections. Although viral reactivation is uncommon, the latent EBV genome still transcribes viral gene products that can result in **malignant transformation** of infected cells. EBV is particularly associated with nasopharyngeal carcinoma, Hodgkin lymphoma, and some forms of NHL (eg, Burkitt lymphoma).

Patients with **HIV** are at greatest risk for EBV-associated lymphomas (risk is up to 60-fold greater). This is likely due to deficits in cell-mediated immunity (decreases immune recognition of EBV-infected cells) and chronic antigen-dependent B-cell stimulation (promotes B-cell proliferation). NHL is considered an AIDS-defining condition and can sometimes be the presenting manifestation of HIV infection.

(Choice B) Aspirin and nonsteroidal anti-inflammatory drugs may decrease the risk of colorectal cancer. Their use is not linked to an increased risk of NHL.

(Choice C) Cigarette smoking is a strong risk factor for the development of many types of cancer (eg, lung, bladder, pancreas) but is not closely linked with the development of NHL.

(Choice D) The link between radiation exposure and the development of NHL is controversial. However, most studies indicate that this is not a strong risk factor.

(Choice E) Although lower socioeconomic status may be associated with worse outcomes in patients with NHL, this marker has not been closely linked with the development of NHL.

Educational objective:
Patients with HIV have much higher rates of lymphoma than the general population. Many cases are due to underlying Epstein-Barr virus infection.

References

- EBV and HIV-related lymphoma.

This patient likely has **non-Hodgkin lymphoma** (NHL). Depending on the subtype, NHL often presents with a rapidly progressive mass,

Exhibit Display

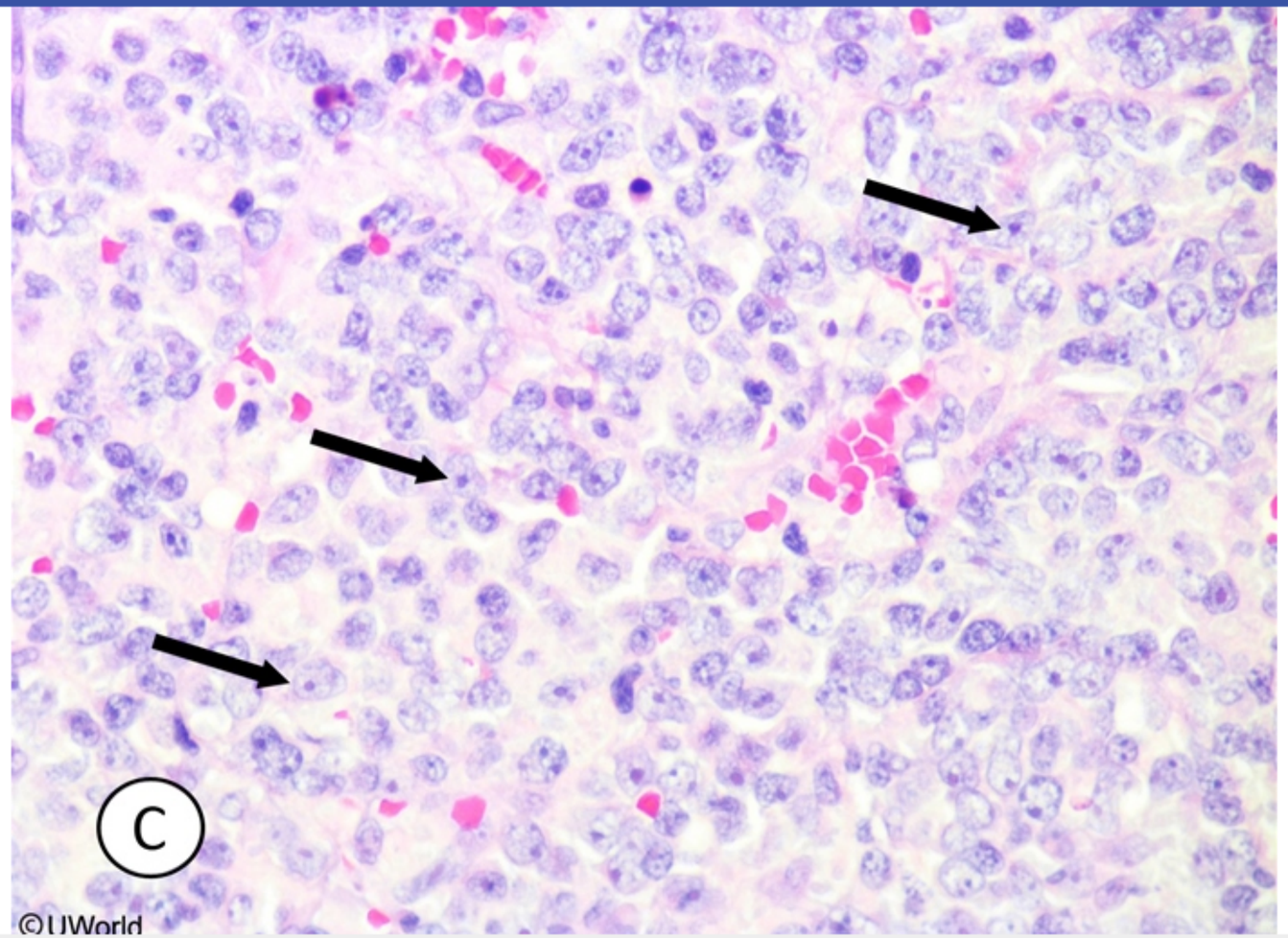

Zoom In | Zoom Out | Reset | Add To New Card | Existing Card

A mother brings her 6-year-old son to his pediatrician because he has been having recurrent nosebleeds. Physical examination reveals diffuse petechiae. Laboratory studies show:

Complete blood count

Hemoglobin	9.0 g/L
Platelet count	20,000/mm^3
Leukocyte count	14,500/mm^3

Bone marrow aspiration reveals the following:

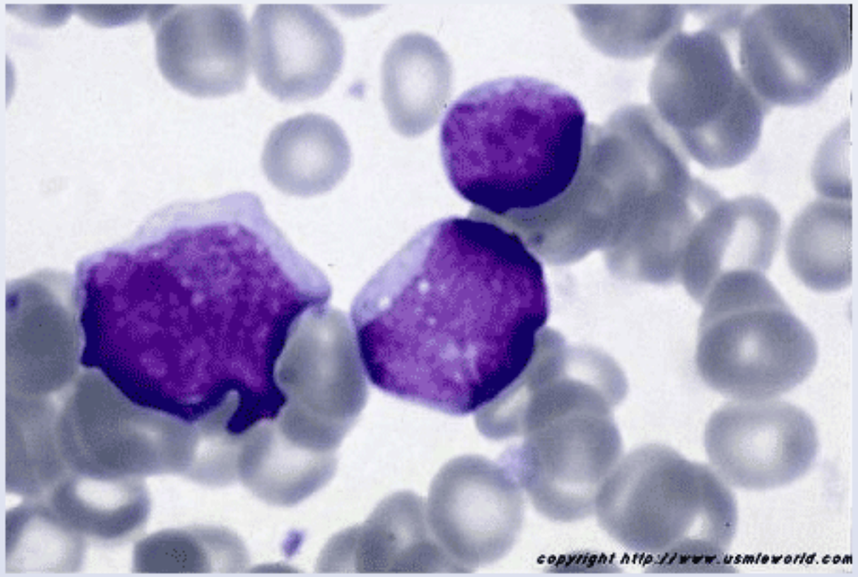

The large cells at the center of the slide demonstrate positive immunostaining for terminal deoxynucleotidyltransferase (TdT). They express

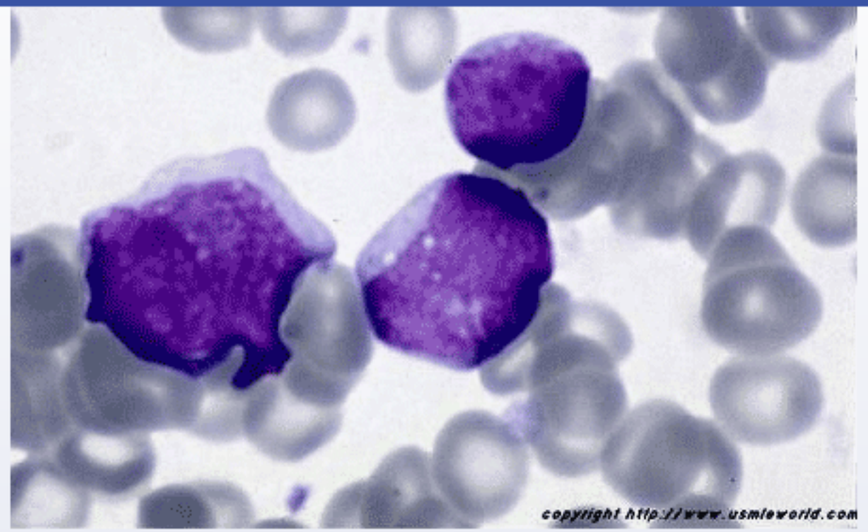

The large cells at the center of the slide demonstrate positive immunostaining for terminal deoxynucleotidyltransferase (TdT). They express surface CD19 and CD10 as well. What is the most likely diagnosis?

- A. Precursor B-cell leukemia
- B. Precursor T-cell leukemia
- C. Mature B-cell leukemia
- D. Mature T-cell leukemia
- E. Hodgkin's lymphoma

Submit

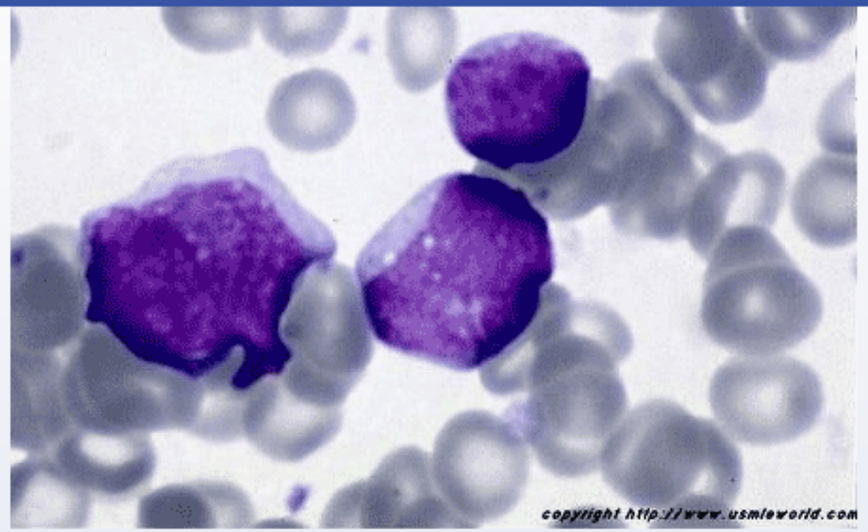

The large cells at the center of the slide demonstrate positive immunostaining for terminal deoxynucleotidyltransferase (TdT). They express surface CD19 and CD10 as well. What is the most likely diagnosis?

- ✓ A. Precursor B-cell leukemia (76%)
- B. Precursor T-cell leukemia (9%)
- C. Mature B-cell leukemia (9%)
- D. Mature T-cell leukemia (2%)
- E. Hodgkin's lymphoma (2%)

Omitted
Correct answer

76%
Answered correctly

04 secs
Time Spent

06/11/2020
Last Updated

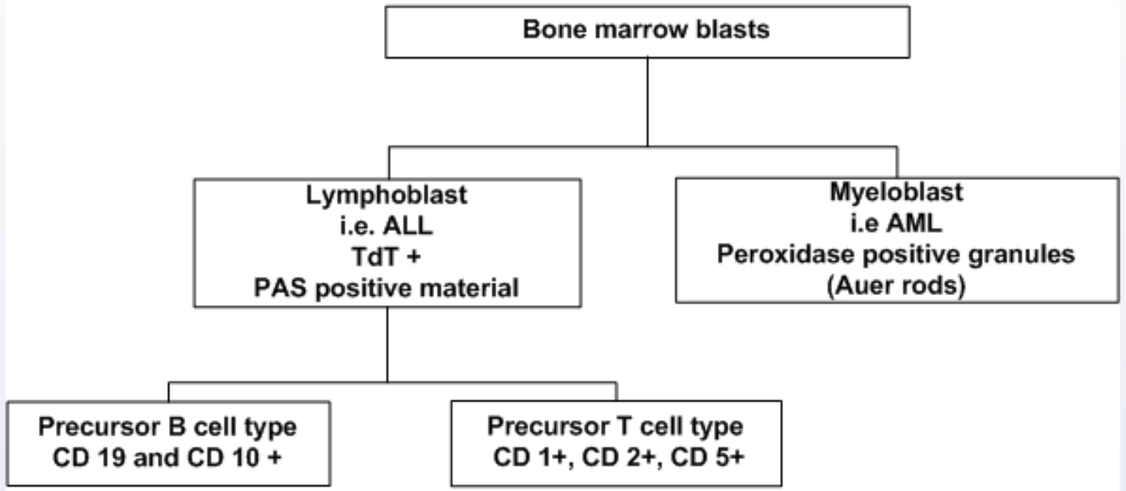

This bone marrow smear shows several lymphoblasts with a high nuclear-to-cytoplasmic ratio, variably condensed nuclear chromatin, and prominent nucleoli. The presence of these immature cells excludes choices C, D & E. The differential diagnosis of this acute lymphoblastic leukemia (ALL) includes precursor B-cell leukemia (precursor B-ALL) and precursor T-cell leukemia (precursor T-ALL). Precursor B-ALL and precursor T-ALL can be distinguished from each other *only* by immunophenotyping. Lymphoblasts in precursor B-ALL are positive for TdT, CD10, and almost always for CD19. In contrast, lymphoblasts in precursor T-ALL are TdT positive and variably express CD1a and the T-cell markers CD2, CD3, CD4, CD5, CD7, and CD8.

ALL is primarily a disease of children (75% occurs in children under six years of age). Most patients with precursor B-ALL present with evidence of bone marrow failure: thrombocytopenia and/or anemia and/or neutropenia. The leukocyte count may be normal, decreased or increased.

(Choice B) Precursor T-ALL accounts for about 15% of all childhood ALL and is more common in adolescents than younger children. Patients typically present with a high leukocyte count and often a large mediastinal mass. The lymphoblasts in precursor T-ALL variably express CD1a and T-cell markers like CD3, CD4, and CD8.

(Choice C) Mature B-cell leukemia (or chronic lymphocytic leukemia/small lymphocytic lymphoma, CLL/SLL) is a neoplasm of small, round, monomorphic B-lymphocytes in the peripheral blood, bone marrow and lymph nodes. These neoplastic lymphocytes express CD19 (B-cell

This bone marrow smear shows several lymphoblasts with a high nuclear-to-cytoplasmic ratio, variably condensed nuclear chromatin, and prominent nucleoli. The presence of these immature cells excludes choices C, D & E. The differential diagnosis of this acute lymphoblastic leukemia (ALL) includes precursor B-cell leukemia (precursor B-ALL) and precursor T-cell leukemia (precursor T-ALL). Precursor B-ALL and precursor T-ALL can be distinguished from each other *only* by immunophenotyping. Lymphoblasts in precursor B-ALL are positive for TdT, CD10, and almost always for CD19. In contrast, lymphoblasts in precursor T-ALL are TdT positive and variably express CD1a and the T-cell markers CD2, CD3, CD4, CD5, CD7, and CD8.

ALL is primarily a disease of children (75% occurs in children under six years of age). Most patients with precursor B-ALL present with evidence of bone marrow failure: thrombocytopenia and/or anemia and/or neutropenia. The leukocyte count may be normal, decreased or increased.

(Choice B) Precursor T-ALL accounts for about 15% of all childhood ALL and is more common in adolescents than younger children. Patients typically present with a high leukocyte count and often a large mediastinal mass. The lymphoblasts in precursor T-ALL variably express CD1a and T-cell markers like CD3, CD4, and CD8.

(Choice C) Mature B-cell leukemia (or chronic lymphocytic leukemia/small lymphocytic lymphoma, CLL/SLL) is a neoplasm of small, round, monomorphic B-lymphocytes in the peripheral blood, bone marrow and lymph nodes. These neoplastic lymphocytes express CD19 (B-cell marker) and coexpress CD5 (T-cell marker) on their surface.

(Choice D) Mature T-cell leukemia is a group of uncommon neoplasms that are derived from mature or post-thymic T-cells. Findings would include more mature lymphocytes (not blasts) expressing T-cell markers.

(Choice E) Hodgkin's lymphoma can involve the bone marrow, but blasts are not prominent. The classic bone marrow finding is Reed-Sternberg cells (large cells with abundant slightly basophilic cytoplasm and at least two nuclear lobes or nuclei).

Educational Objective:
Precursor B-ALL and precursor T-ALL can only be distinguished by immunophenotyping. The lymphoblasts in precursor B-ALL are TdT+, CD10+ and CD19+, whereas the lymphoblasts in precursor T-ALL express T-cell markers (e.g. CD2, CD3, CD4, CD5, CD7 and CD8), TdT and CD1a.

Pathology	Hematology & Oncology	Acute lymphoblastic leukemia
Subject	System	Topic

leukemia (ALL) includes precursor B-cell leukemia (precursor B-ALL) and precursor T-cell leukemia (precursor T-ALL). Precursor B-ALL and precursor T-ALL can be distinguished from each other *only* by immunophenotyping. Lymphoblasts in precursor B-ALL are positive for TdT, CD10, and almost always for CD19. In contrast, lymphoblasts in precursor T-ALL are TdT positive and variably express CD1a and the T-cell markers CD2, CD3, CD4, CD5, CD7, and CD8.

ALL is primarily a disease of children (75% occurs in children under six years of age). Most patients with precursor B-ALL present with evidence of bone marrow failure: thrombocytopenia and/or anemia and/or neutropenia. The leukocyte count may be normal, decreased or increased.

(Choice B) Precursor T-ALL accounts for about 15% of all childhood ALL and is more common in adolescents than younger children. Patients typically present with a high leukocyte count and often a large mediastinal mass. The lymphoblasts in precursor T-ALL variably express CD1a and T-cell markers like CD3, CD4, and CD8.

(Choice C) Mature B-cell leukemia (or chronic lymphocytic leukemia/small lymphocytic lymphoma, CLL/SLL) is a neoplasm of small, round, monomorphic B-lymphocytes in the peripheral blood, bone marrow and lymph nodes. These neoplastic lymphocytes express CD19 (B-cell marker) and coexpress CD5 (T-cell marker) on their surface.

(Choice D) Mature T-cell leukemia is a group of uncommon neoplasms that are derived from mature or post-thymic T-cells. Findings would include more mature lymphocytes (not blasts) expressing T-cell markers.

(Choice E) Hodgkin's lymphoma can involve the bone marrow, but blasts are not prominent. The classic bone marrow finding is Reed-Sternberg cells (large cells with abundant slightly basophilic cytoplasm and at least two nuclear lobes or nuclei).

Educational Objective:
Precursor B-ALL and precursor T-ALL can only be distinguished by immunophenotyping. The lymphoblasts in precursor B-ALL are TdT+, CD10+ and CD19+, whereas the lymphoblasts in precursor T-ALL express T-cell markers (e.g. CD2, CD3, CD4, CD5, CD7 and CD8), TdT and CD1a.

Pathology	Hematology & Oncology	Acute lymphoblastic leukemia
Subject	System	Topic

Copyright © UWorld. All rights reserved.